

## Erratum

**“A patient with fatigue and subfebrile temperature”. G.J.M. Herder, E.F. Smit, P.J. Borgstein, P.E. Postmus. *Eur Respir J* 2000; 16: 184–186.**

The wrong image was shown in figure 1a. The full figure is reproduced below along with the legend.

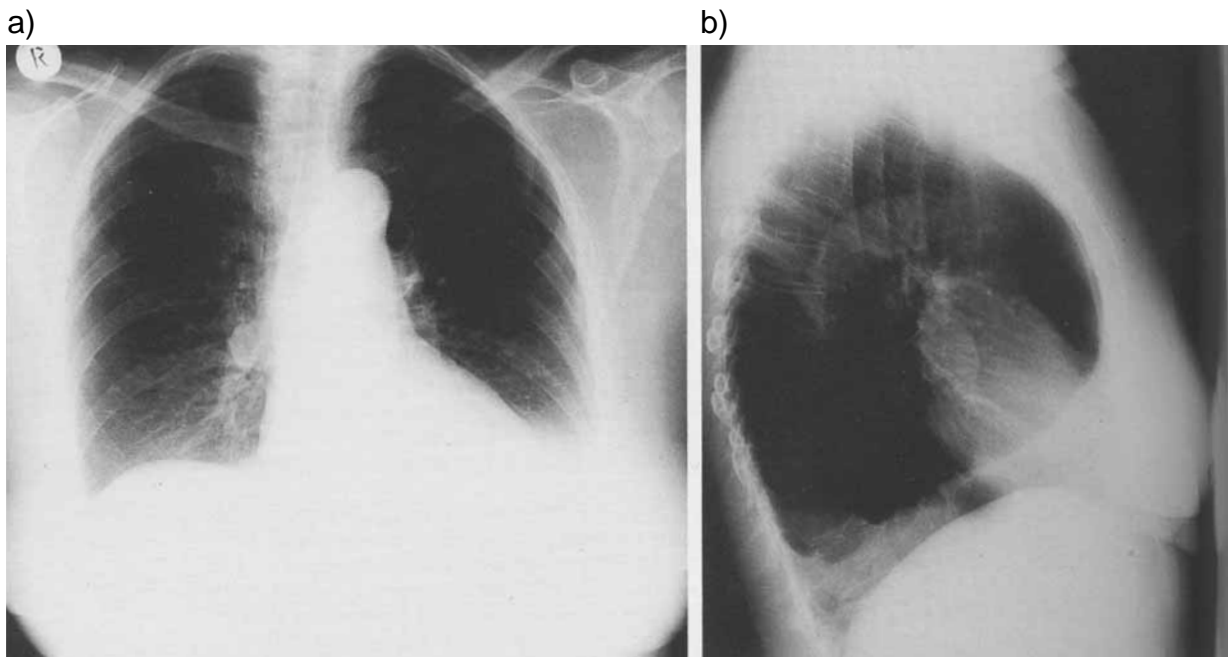


Fig. 1. – a) Posteroanterior chest radiograph. b) Lateral chest radiograph.