

Bronchoalveolar lavage in allergic granulomatosis and angiitis

B. Wallaert^{††}, P. Gosset[†], L. Prin^{**}, F. Bart^{*}, C-H. Marquette^{*}, A.B. Tonnel^{††}

Bronchoalveolar lavage in allergic granulomatosis and angiitis. B. Wallaert, P. Gosset, L. Prin, F. Bart, C-H. Marquette, A.B. Tonnel. ©ERS Journals Ltd 1993.

ABSTRACT: Pulmonary involvement occurs in approximately half of patients with allergic granulomatosis and angiitis (AGA). We studied bronchoalveolar cells from six patients with histologically proven AGA and compared our results with those obtained from four patients with chronic eosinophilic pneumonia (CEP), nine nonsmoking patients with bronchial asthma and blood eosinophilia, and 10 healthy nonsmokers. Pulmonary infiltrates were present in 5 out of 6 AGA patients. None of these patients was receiving corticosteroids at the time of entry to the study. Pulmonary function tests were normal in two cases, and demonstrated on obstructive ventilatory disorder with hypoxaemia in four cases. Total cell yield did not differ between AGA patients ($22.4 \pm 4.9 \times 10^4$ cells·ml⁻¹), asthmatics ($9.6 \pm 1.7 \times 10^4$ cells·ml⁻¹) and controls ($11.3 \pm 1.5 \times 10^4$ cells·ml⁻¹), whereas it was dramatically increased in patients with CEP ($186.4 \pm 26.3 \times 10^4$ cells·ml⁻¹). All six AGA patients demonstrated an increased percentage of alveolar eosinophils (mean: $31.1 \pm 9.9\%$; range 6-66%). In two patients evaluation of alveolar eosinophil subpopulations showed a low percentage (27 and 36%) of hypodense cells, when compared to the high levels (>80%) found in CEP. No significant correlation could be established between bronchoalveolar (BAL) results and clinical data, pulmonary function abnormalities, or biological results. Sequential evaluation of alveolitis in two AGA patients undergoing corticosteroid therapy demonstrated persistent alveolar eosinophilia, despite disappearance of clinical, radiological and biological abnormalities.

Our data demonstrate that eosinophils are present in the alveolar spaces of patients with AGA. However, when expressed as a percentage, their amount was reduced and apparently less sensitive to corticosteroid therapy than in CEP. These findings suggest that the role of eosinophils in the pathophysiology of AGA differs from CEP and remains to be elucidated.

Eur Respir J., 1993, 6, 413-417.

Allergic granulomatosis and angiitis (AGA), originally described by CHURG and STRAUSS [1] in 1951, is characterized by disseminated necrotizing vasculitis involving small arteries and veins, with a tissue infiltration by eosinophils and extravascular granulomas. The clinical hallmark of this syndrome is asthma, with a high degree of blood eosinophilia [2, 3]. Pulmonary involvement occurs in approximately half of patients with AGA, including a variety of pneumonic infiltrates, nodular pulmonary densities, with or without cavitation, and diffuse interstitial lung disease [4]. Histological examination of the lung discloses fibrinoid, necrotizing and eosinophilic granulomatous lesions [5]. Current concepts on the pathophysiology of pulmonary granulomatosis disorders have stressed the importance of alveolitis, *i.e.* accumulation of immune and effector cells within the alveolar structures [6]. During the last decade, extensive studies using bronchoalveolar lavage (BAL), have provided the unique opportunity to explore the alveolitis associated with chronic disorders of the lower respiratory tract [7]. There is, however, little information about the inflammatory

cells present in airways in AGA [8, 9]. Therefore, we initiated a study of the alveolar inflammatory cells recovered by BAL from the lower respiratory tract of six patients with proven AGA and compared our results with those obtained from four patients with chronic eosinophilic pneumonia (CEP), from nine nonsmoking asthmatic patients evaluated at baseline and from 10 healthy nonsmokers.

Materials and methods

Patients

Six patients with histologically proven AGA were included in the study (table 1). They were five males and one female, aged 31-47 yrs (mean 40 ± 1 yrs). All were nonsmokers. Respiratory symptoms included asthma in all cases, associated with allergic rhinitis in one. Five showed pulmonary infiltrates on chest roentgenogram. Extra respiratory involvement included weight loss and

* Service de Pneumologie et Immuno-allergologie, Hôpital A. Calmette, CHRU, Lille, France. † CJF INSERM 90-06 Institut Pasteur, Lille, France, ** CIBP Institut Pasteur, Lille, France.

Correspondence: B. Wallaert
Service de Pneumologie et Immuno-allergologie
Hôpital A. Calmette
Bld du Pr. J. Leclerc
59037 Lille Cédex
France

Keywords: Allergic granulomatosis and angiitis
bronchoalveolar lavage
eosinophil
eosinophilic lung disease

Received: June 12 1992
Accepted after revision September 10 1992

Supported by INSERM CJF 90-06 and by Université de Lille II.

weakness in all patients, myalgia and arthralgia in two, abdominal pain in three, mononeuritis multiplex in five, purpura in one, glomerulonephritis in two and hepatitis in five. None of the patients was receiving corticosteroids at the time of referral. Laboratory findings included: elevation of erythrocyte sedimentation rate, high degrees of peripheral blood eosinophilia (mean: 12,632; range: 3,900–33,000 eosinophils·mm⁻³), and presence of circulating immune complexes. Antinuclear antibodies, cryoglobulins and hepatitis B surface antigen were absent in all patients; rheumatoid factor was present in two patients, complement was normal in each patient; total serum immunoglobulin E (IgE) level was high. Pulmonary function tests (PFT) at rest were performed at the time of initial evaluation and included forced vital capacity (FVC) and forced expiratory volume in one second (FEV₁). Residual volume (RV) and total lung capacity (TLC) were determined with the helium dilution method.

Table 1. – Allergic granulomatosis and angiitis: pathological findings

Case no.	Necrotizing vasculitis	Granulomas	Eosinophil infiltration
1	Muscle		Kidney
2	Muscle		
3	Liver, kidney		Kidney
4	Lung	Lung	Lung
5	Liver		Lung
6	Liver, muscle	Liver	Liver, lung, muscle

Diffusing capacity of the lungs for carbon monoxide (DLCO) was obtained by single breath method and corrected for alveolar volume and haemoglobin. The predicted values for each subject, based on sex, age and height, were obtained from standard tables [10]. PFT were normal in two cases. Four patients (cases no. 1, 4, 5 and 6) exhibited an obstructive ventilatory syndrome (FEV₁: 62, 48, 62 and 72% predicted values; FEV₁/FVC: 53, 49, 48 and 67%) with hypoxaemia (Pao₂: 65, 64, 47 and 62 mmHg (8.7, 8.5, 6.3 and 8.3 kPa), respectively).

The control groups included 10 healthy nonsmokers (8 men and 2 women, 22–46 yrs of age), and nine non-smoking asthmatic patients (6 men and 3 women, 20–45 yrs of age) with blood eosinophilia (985±122 eosinophils·mm⁻³), who responded to the usual criteria of allergic asthma and exhibited mild asthma at a distance from any acute phase [11]. Four patients with chronic eosinophilic pneumonia (CEP) (4 women, aged 28–48 yrs) who demonstrated clinical, biological and radiological characteristics of the disease [12, 13] were also studied.

Bronchoalveolar lavage

Bronchoalveolar lavage was performed after premedication with atropine, under local anaesthesia with lignocaine, using a wedged fiberoptic bronchoscope (Olympus

model BF-B3; Olympus Corps of America, New Hyde Park, NY, USA), and 250 ml of sterile saline solution was applied in five 50 ml aliquots, with immediate gentle vacuum aspiration after each aliquot. When infiltrates were observed on chest X-ray, BAL was performed in this segment. The aspirated fluid was collected into sterile siliconized jugs and immediately transported on ice to the laboratory. BAL was filtered through several layers of sterile surgical gauze and the cells were separated from the fluid by low speed centrifugation at 800 × g (10 min). After three washings, the cells were resuspended in 10 ml of Hank's balanced salt solution (HBSS) and evaluated for their total number. Cell identification using cytocentrifuged preparations stained by Giemsa (R.A.L. 555, Société Chimique Pointed Girard, Clichy, France) and differential cell count were then performed. To characterize alveolar eosinophil sub-populations, alveolar cells were suspended at 0.5×10⁸ cells·ml⁻¹ in minimum essential medium (MEM) containing 10% heat-inactivated foetal calf-serum (MEM:FCS) and were layered on discontinuous metrizamide gradients (Nyegaard, Oslo, Norway) as described previously [13, 14]. The cell fractions were then collected from each gradient and interface, and washed in MEM. The percentage purity and the morphology of the eosinophils, were estimated by using cytocentrifuged preparations stained with Giemsa. Normal granular eosinophils, which are collected in 24–25% metrizamide solutions (density 1,135–1,140 g·ml⁻¹) are referred to as "normodense" eosinophils. Eosinophils which sediment in the lightest density gradients (in 18–23% metrizamide solutions; density 1,105 to 1,125 g·ml⁻¹) are referred to as "hypodense" eosinophils. No contaminating basophils or mast cells were identified in these purified blood or alveolar eosinophil preparations. Viability estimated by the trypan blue dye exclusion test was >90% for all separated sub-populations.

Statistical analysis

Since most data are not normally distributed, results were compared using the Mann-Whitney U-test.

Results

Evaluation of number and types of bronchoalveolar cells

Endoscopic examination of the tracheobronchial tree before lavage demonstrated normal airways in all subjects, with no evidence of inflammation. Total cell count in BAL fluid did not differ between AGA patients, asthmatics and normals, but was significantly lower than in patients with CEP (table 2). Evaluation of BAL differential cell counts of AGA patients, asthmatics and CEP patients demonstrated a shift in the cell differential compared with normal subjects, with a higher proportion of eosinophils. Patients also had reduced percentages of alveolar macrophages in proportion to the increased percentages of alveolar eosinophils. Percentage of lymphocytes was normal.

Table 2. — Distribution of alveolar inflammatory cells

	Total cell count $10^4 \cdot \text{ml}^{-1}$	Alveolar macrophages		Lymphocytes		Neutrophils		Eosinophils	
		%	$10^4 \cdot \text{ml}^{-1}$	%	$10^4 \cdot \text{ml}^{-1}$	%	$10^4 \cdot \text{ml}^{-1}$	%	$10^4 \cdot \text{ml}^{-1}$
AGA									
Case no.									
1	20	92	18.4	2	0.4	0	0	6	1.2
2	36.3	25	9.1	7	2.5	2	0.72	66	23.9
3	5.6	65	3.64	11	0.6	7	0.4	17	0.95
4	12.8	82	10.5	8	0.13	1	0.13	9	1.15
5	25	42	10.5	4	1	3	0.75	51	12.75
6	35	52	18.2	2	0.7	8	2.8	38	13.3
Mean	22.4 [§]	59.6*	11.7 [§]	5.6	0.8 [§]	3.5	0.8 [§]	31.1* [#]	8.8* ^{§#}
SEM	± 4.9	± 10	± 2.3	\pm	± 0.34	± 1.3	± 0.4	± 9.9	± 3.8
CEP (n=4)	186.4* ± 26.3	36.2* ± 9.4	83.2* ± 14	4.1 ± 2	8.2* ± 4.1	2.6 ± 0.4	4.6* ± 1.8	56.2* ± 12	121.8* ± 27
Asthmatics (n=9)	9.6 [§] ± 1.7	85.7 [§] ± 1.7	8.2 [§] ± 1.2	8.8 ± 1	0.8 [§] ± 0.2	2.2 ± 0.7	0.2 [§] ± 0.03	3.1* [§] ± 1	0.3* [§] ± 0.1
Controls (n=10)	11.3 ± 1.5	90 ± 1.7	10.2 ± 1.3	7.8 ± 1.5	0.8 ± 0.2	0.9 ± 0.2	0.07 ± 0.002	0.3 ± 0.1	0.02 ± 0.01

Results, unless individual, are mean \pm SEM. AGA: allergic granulomatosis and angiitis; CEP: chronic eosinophilic pneumonia; *: significantly different from healthy controls ($p < 0.05$); [§]: significantly different from patients with CEP ($p < 0.05$); [#]: significantly different from asthmatics ($p < 0.05$). Results obtained from patients with CEP and asthmatics have been published previously in [13] and [11], respectively.

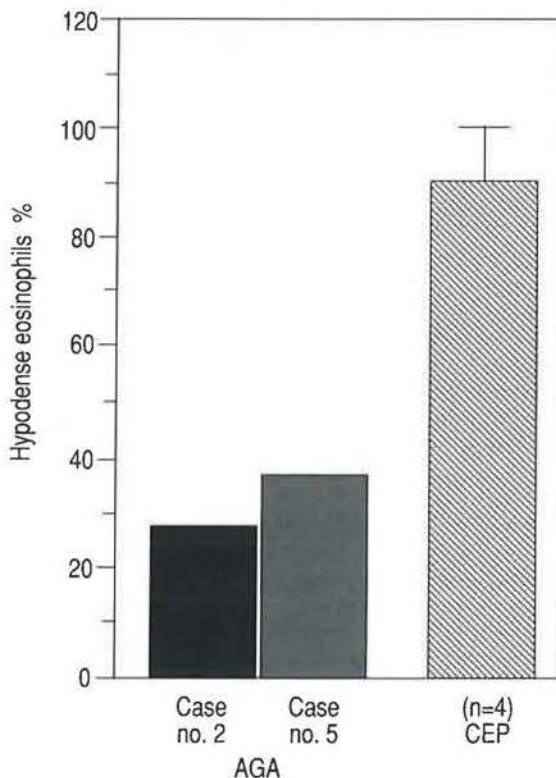


Fig. 1. — Distribution of alveolar eosinophils after separation on discontinuous gradients of metrizamide. Percentage of BAL hypodense eosinophils in two patients with AGA and four patients with CEP. BAL: bronchoalveolar lavage; AGA: allergic granulomatosis and angiitis; CEP: chronic eosinophilic pneumonia.

In addition, the proportion of neutrophils was mildly elevated in two patients. Basophils were not observed in the BAL of these patients. Determination of eosinophil density was carried out in two cases, because of the small number of alveolar eosinophils in the other cases. Distribution of alveolar eosinophils (cases no. 2 and 5) demonstrated a normal distribution (27 and 36% of hypodense cells, respectively) when compared to the high percentage (>80%) described in patients with CEP [13] (fig. 1).

Sequential evaluation of alveolitis

Two patients (cases no. 1 and 2) were evaluated by sequential BAL, before and during corticosteroid treatment. The two patients were treated with prednisolone ($1 \text{ mg} \cdot \text{kg}^{-1} \text{ q.d.}$) for 8 months and 12 months at the time of the second evaluation. BAL studies demonstrated that corticosteroid therapy did not suppress the intensity of eosinophil alveolitis (from 6 to 8% and from 66 to 58%, respectively), whereas blood eosinophilia and pulmonary function tests returned to normal.

Relationship between BAL findings and other parameters

The small number of patients in our study did not allow definite correlations between BAL findings and biological, functional and radiographic parameters. Although peripheral blood hypereosinophilia was associated with

alveolar eosinophilia, there was no correlation between these two parameters. Increased percentage of BAL eosinophils was found to an equal extent in patients with radiological and functional abnormalities and in patients with either normal chest X-rays or normal pulmonary function tests.

Discussion

Our study clearly demonstrated the presence of eosinophils on the surface of the lower respiratory tract from patients with AGA. Alveolar eosinophils were found in BAL from five patients with overt pulmonary involvement and in BAL from one patient with normal chest roentgenogram. Eosinophil accumulation in the lower respiratory tract has been reported in a variety of lung diseases associated with parenchymal lung damage and interstitial fibrosis [15]. Eosinophils are frequently found in bronchoalveolar lavage fluid in diseases generally considered to be pulmonary eosinophilic disorders, such as histiocytosis X, chronic eosinophilic pneumonia and drug-induced pneumonitis [16–18]. In addition, increased numbers of eosinophils have been recovered from patients with allergic asthma and during allergen-induced late asthmatic reactions [19, 20]. However, the absolute and percentage eosinophil counts were significantly lower in asthmatics than in the AGA patients.

Studies of lung biopsy specimens of patients with vasculitis clearly demonstrated the eosinophil component of alveolitis associated with perivascular granuloma and necrotizing angiitis [5]. Thus, BAL eosinophilia may reflect the eosinophil alveolitis associated with AGA. Eosinophil-induced lung injury has been reported both in Churg-Strauss Syndrome [21] and in chronic eosinophilic pneumonia [22]. Activated eosinophils are observed and eosinophil cationic protein (ECP) and eosinophil protein X (EPX) are released [22]. Consistent with this concept, BAL eosinophils exhibit spontaneous cytotoxicity against tracheal epithelial cells, alveolar epithelial cells and human alveolar cells *in vitro* [15, 23–25], suggesting that the eosinophil may play a direct role in the lower respiratory tract injury.

Density distribution pattern of eosinophils from two patients with AGA demonstrated that most eosinophils sedimented in the high density gradient fractions (24–25% metrizamide solutions; density 1,135–1,140 g·ml⁻¹) and were referred to as "normodense" eosinophils. In marked contrast, alveolar eosinophils from patients with CEP were predominantly hypodense eosinophils (with a density of <1,130 g·ml⁻¹). Previous studies suggested that eosinophil density is altered in the affected tissues by factors associated with the disease process. These results are in agreement with previous studies demonstrating an accumulation of normodense eosinophils in the lower respiratory tract of patients with various eosinophilic lung diseases, such as polyarteritis nodosa and amiodarone-induced pneumonitis [12], and is consistent with the hypothesis of different patterns of activation of alveolar eosinophils in lung diseases. FUKUDA *et al.* [26] reported increased numbers of hypodense eosinophils in the blood

of patients with bronchial asthma to be in a lower proportion than in the blood of patients with hyper-eosinophilic syndrome. Thus, the reason for different densities of eosinophils in various diseases is unclear. One cannot exclude that processes responsible for attraction and migration of eosinophils towards the airways depend on different activation mechanisms.

The significance of eosinophils in the pathophysiology of AGA remains unclear. Firstly, there is convincing evidence that an accumulation of inflammatory cells and, particularly eosinophils, might be observed despite normal chest X-ray, normal PFT and normal high resolution computed tomography (HRCT) scan [27, 28]. Secondly, the fact that eosinophil alveolitis was unaffected by steroid therapy raises the intriguing question of the ability of steroids to protect the lung against eosinophil-mediated lung injury during the clinical course of AGA. Indeed, an increased percentage of alveolar eosinophils may be present in patients with normal chest X-ray and/or normal pulmonary function tests. In this context, the clinical role of BAL in the management of AGA needs to be determined.

References

1. Churg J, Strauss L. – Allergic granulomatosis, allergic angiitis and periarteritis nodosa. *Am J Pathol* 1951; 27: 277–294.
2. Chumbley LC, Harrison EG, de Remez RA. – Allergic granulomatosis and angiitis (Churg and Strauss syndrome). *Mayo Clin Proc* 1977; 52: 477–484.
3. Lanham JG, Elkon KB, Pusey CD, Hugues GR. – Systemic vasculitis with asthma and eosinophilia: a clinical approach to the Churg-Strauss syndrome. *Medicine* 1984; 63: 65–81.
4. Laevitt RY, Fauci AS. – Pulmonary vasculitis. *Am Rev Respir Dis* 1986; 134: 149–166.
5. Fauci AS, Haynes BF, Katz P. – The spectrum of vasculitis: clinical, pathologic, immunologic and therapeutic considerations. *Ann Intern Med* 1978; 89: 660–676.
6. Keogh BA, Crystal RG. – Alveolitis: the key of the interstitial lung disorders. *Thorax* 1982; 37: 1–9.
7. Wallaert B, De Vuyst P, Israel-Biet D. – Le lavage bronchoalveolaire. *Rev Mal Respir* 1992; 9: 39–56.
8. Bart F, Wallaert B, Prin L, *et al.* – Pulmonary involvement in allergic granulomatosis and angiitis. Evaluation of alveolitis by bronchoalveolar lavage. *Am Rev Respir Dis* 1986; 133: 313 A.
9. Schmidt B, Teschler H, Kroegel C, *et al.* – Bronchoalveolar cell profiles in Wegener's granulomatosis, chronic eosinophilic pneumonia and Churg-Strauss syndrome. *Eur Respir J* 1989; 2 (Suppl. 8): 641S.
10. Quanjer PH (Comp. and Ed). – Standardized lung function testing. Report of the working party on standardization of lung function tests. Luxembourg: European Community for Coal and Steel, 1981.
11. Gosset Ph, Tsicopoulos A, Wallaert B, *et al.* – Increased secretion of tumor necrosis factor- α and interleukin-6 by alveolar macrophages consecutive to the development on the late asthmatic reaction. *J Allergy Clin Immunol* 1991; 88: 561–571.
12. Carrington CB, Addington NW, Goff AM, *et al.* – Chronic eosinophilic pneumonia. *N Engl J Med* 1969; 280: 787–791.

13. Prin L, Capron M, Gosset Ph, *et al.* – Eosinophilic lung disease: immunological studies of blood and alveolar eosinophilia. *Clin Exp Immunol* 1986; 63: 249–257.
14. Prin L, Charon J, Capron M, *et al.* – Heterogeneity of human eosinophils. II. Variability of respiratory burst activity related to cell density. *Clin Exp Immunol* 1984; 57: 735–742.
15. Davis WB, Fells GA, Sun SH, *et al.* – Eosinophil-mediated injury to lung parenchymal cells and interstitial matrix: a possible role for eosinophils in chronic inflammatory disorders of the lower respiratory tract. *J Clin Invest* 1984; 74: 269–278.
16. Olivieri D, Pesci A, Bertorelli G. – Eosinophilic alveolitis in immunologic interstitial lung disorders. *Lung* 1990; (Suppl.): 964–973.
17. Allen JN, Bruce D, Pacht ER. – Diagnostic significance of increased bronchoalveolar lavage fluid eosinophils. *Am Rev Respir Dis* 1990; 142: 642–647.
18. Danel C, Israel-Biet D, Costabel U, Rossi GA, Wallaert B. – The clinical role of BAL in eosinophilic lung diseases. *Eur Respir J* 1990; 3: 950.
19. Godard PH, Bousquet J, Lebel B, Michel FB. – Le lavage bronchoalvéolaire chez l'asthmatique. *Bull Eur Physiopathol Respir* 1987; 23: 73–83.
20. Tonnel AB, Joseph M, Wallaert B. – Bronchoalveolar lavage in the study of allergic asthma. *Baillière's Clinical Immunology and Allergy* 1988; 2: 177–195.
21. Williams BD, Spry CJF. – Deposition of eosinophilic cationic protein in granulomas in allergic granulomatosis and vasculitis: the Churg-Strauss syndrome. *Br Med J* 1984; 289: 402–409.
22. Gonzalez E, Swedo JL, Rajaraman S, Daniels JC, Grant JA. – Ultrastructural and immunohistochemical evidence for release of eosinophilic granules *in vivo*: cytotoxic potential in chronic eosinophilic pneumonia. *J Allergy Clin Immunol* 1987; 79: 755–762.
23. Gleich GJ, Frigas E, Loegering DA, Wassom DL, Steimuller D. – Cytotoxic properties of eosinophil major basic protein. *J Immunol* 1979; 123: 1925–1927.
24. Frigas E, Loegering DA, Gleich GJ. – Cytotoxic effects of the guinea-pig eosinophil major basic protein on tracheal epithelium. *Lab Invest* 1980; 42: 35–42.
25. Ayars GH, Altman LC, Gleich G, Loegering D, Baker CB. – Eosinophil and eosinophil granule-mediated pneumocytic injury. *J Allergy Clin Immunol* 1985; 76: 595–604.
26. Fukuda T, Dunnette SL, Reed CE, *et al.* – Increased numbers of hypodense eosinophils in the blood of patients with bronchial asthma. *Am Rev Respir Dis* 1985; 132: 981–985.
27. Dejægher Ph, Derveaux L, Dubois P, Demedts M. – Eosinophilic pneumonia without radiographic pulmonary infiltrates. *Chest* 1983; 84: 637–638.
28. Wallaert B, Dugas M, Dansin E, *et al.* – Subclinical alveolitis in immunological systemic disorders. Transition between health and diseases? *Eur Respir J* 1990; 3: 1206–1216.