

Pulmonary schistosomiasis resembling acute pulmonary tuberculosis

T. Schaberg*, W. Rahn*, P. Racz**, H. Lode*

Pulmonary schistosomiasis resembling acute pulmonary tuberculosis. T. Schaberg, W. Rahn, P. Racz, H. Lode.

ABSTRACT: Pulmonary involvement of schistosomiasis is usually characterized by a miliary mottling or diffuse nodular infiltrates. In most cases, pulmonary involvement is associated with an apparent clinical involvement of other organs. This report describes a 35 yr old patient who developed a cavity, a parenchymatous infiltrate and hilar adenopathy in association with pulmonary schistosomiasis. Schistosoma eggs were demonstrated in transbronchial biopsies from the lung. Pulmonary involvement of schistosomiasis is reviewed and atypical features are discussed, which may lead to diagnostic difficulties, particularly compared to tuberculosis.

Eur Respir J, 1991, 4, 1023-1026.

* Dept of Infectious Diseases and Immunology, Pulmonary Section, City Hospital Berlin - Zehlendorf (affiliated Freie Universität Berlin), D-1000 Berlin 39, FRG.

** Bernhard-Nocht-Institute of Tropical Medicine, D-2000 Hamburg 36, FRG.

Correspondence: T. Schaberg, Dept of Infectious Diseases and Immunology, Pulmonary Section, Krankenhaus Zehlendorf, Zum Heckeshorn 33, D-1000 Berlin 39, FRG.

Keywords: Lung involvement; schistosomiasis.

Received: March 20, 1991; accepted after revision May 13, 1991.

Schistosomiasis is one of the major helminthic infections in man. There are three main species of the parasite which causes human infections. *S. mansoni* is common in Africa, Arabia and South America; *S. haematobium* is found in Africa and Arabia and *S. japonicum* is found in Japan and China [1]. A pulmonary involvement with schistosomiasis is described in three different forms: 1) In acute schistosomiasis, an eosinophilic pneumonia has been described, without direct parasite distribution to the lung; 2) In chronic hepatosplenic schistosomiasis, an embolism of eggs moves into the pulmonary circulation and produces a granulomatous endarteritis leading to progressive development of pulmonary hypertension and cor pulmonale; 3) An embolism of dead worms and dead eggs into the pulmonary circulation has been described in connection with antischistosomiasis therapy [1].

This report describes a case of pulmonary involvement of schistosomiasis with a cavity, a parenchymatous infiltrate and hilar adenopathy in the right upper lobe, mimicking acute tuberculosis. No signs of infection of the bladder, the intestinal tract, or the liver were found.

Case report

A 35 yr old black man was admitted to the hospital, because of a mild non-productive cough and night sweats. The man was an immigrant from Angola, Africa, who had arrived in Europe only 8 weeks before admission. There was no history of tuberculosis, parasitic diseases or other lung diseases. The patient was a nonsmoker. There was no history of weight loss, diarrhoea or fatigue.

The admission chest radiograph showed a cavitory infiltration in the apical segment of the right upper lobe with a modest generalized increase in density of the upper right lobe above the fissure, and a dense parenchymatous infiltration on the upper right hilar pole (fig. 1). Tomographic studies confirmed a hilar adenopathy, the parenchymatous infiltrate in the posterior segment of the upper lobe and the cavernous infiltrate with surrounding parenchymal infiltration.

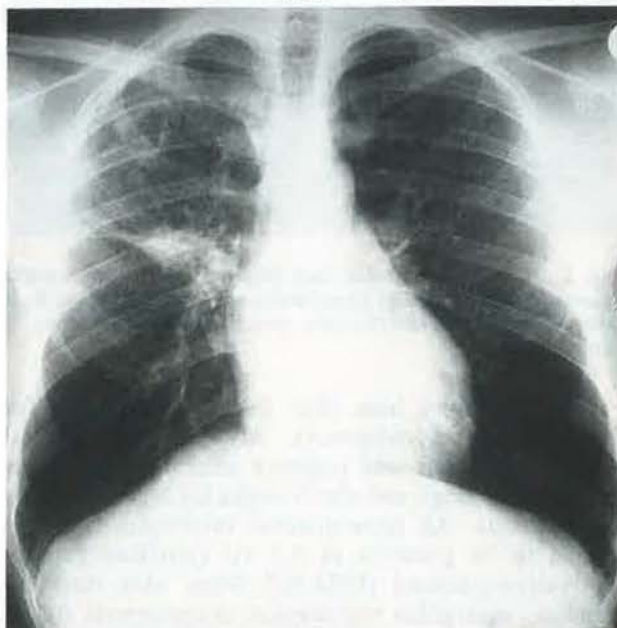


Fig. 1. - Posteroanterior chest X-ray on admission showing a dense infiltrate on the upper right hilar pole, a slightly diffuse interstitial infiltrate in the upper right lobe and a cavernous lesion under the clavicle.

Physical examination revealed an alert, well-developed man in good condition (body weight 63 kg; height; 175 cm). Body temperature was 37.1°C, respiratory rate 18·min⁻¹, heart rate 84·min⁻¹ and blood pressure 140/90 mmHg. No rashes or lymphadenopathy were found. There was no palpable hepatic or splenic enlargement. Laboratory studies revealed: blood sedimentation rate 36 mm in the 1st hour; haemoglobin level 144 g·l⁻¹; haematocrit 44%; leucocyte count 4.7×10⁹·l⁻¹ with 31% granulocytes, 12% eosinophils, 4% monocytes, 50% lymphocytes and 3% atypical lymphocytes. Lymphocyte subpopulation distribution was: 56% CD3+ cells, 36% CD4+ cells, 61% CD5+ cells, 76% CD7+ cells, 28% CD8+ cells, 17% CD16+ cells and 6% CD19+ cells (all normal values in our laboratory). The chemical profile revealed a borderline elevation of the serum alanine aminotransferase (33 U·l⁻¹) and of the gamma-glutamyl-transferase (31 U·l⁻¹). All other chemical values, coagulation studies and multiple urinalysis were normal. Serum-electrophoresis showed a total protein of 80 g·l⁻¹ with a decreased albumin fraction (49%) and an increased gamma globulin level of 29%. Levels of immunoglobulin (Ig) G, A and M were within the normal range, but the serum IgE level was increased to 1,450 U·l⁻¹. Precipitating antibodies against fungi (aspergillus, candida, penicillium, cryptococcus) were negative.

saturation 95.9%. Lung function studies showed normal values (total lung capacity (TLC) 6.1 l, vital capacity (VC) 5.0 l, forced expiratory volume in one second (FEV₁) 4.6 l, airways resistance (Raw) 0.11 kPa·l⁻¹·s).

Fibreoptic bronchoscopy was performed under local anaesthesia, revealing a normal central bronchial system and a marked mucosal oedema inside the right upper lobe bronchus, where the lumen of the apical segment bronchus was narrowed by half. Biopsies were taken from the mucosal membrane of the right upper lobe bronchus, and transbronchial lung biopsies were taken from the peripheral cavitory infiltrate in this lobe. The bacteriological examination of samples obtained by bronchoscopy was negative for bacteria, fungi and mycobacteria. After 8 weeks, all cultures from these materials for mycobacteria remained negative. Cytological studies showed only necrotic cellular material, containing erythrocytes, granulocytes, lymphocytes and macrophages.

The histological examination of the biopsies from both the lung parenchyma and the bronchus wall revealed a marked eosinophilic infiltration with epithelioid-cell granulomas and some giant-cells. Eosinophilic material, suggesting parasitic deposition, was seen inside the granuloma and in the lung tissue. Re-examination of the biopsies revealed this material

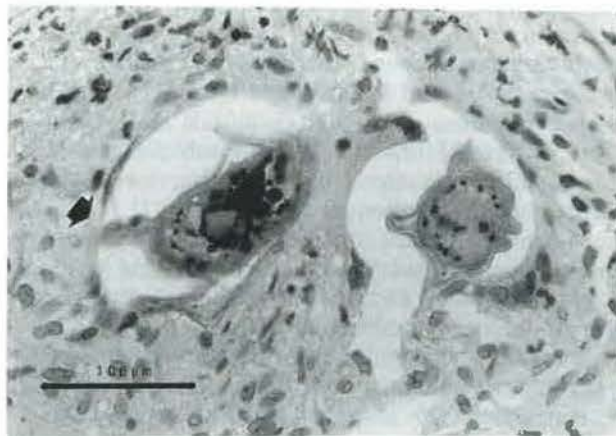
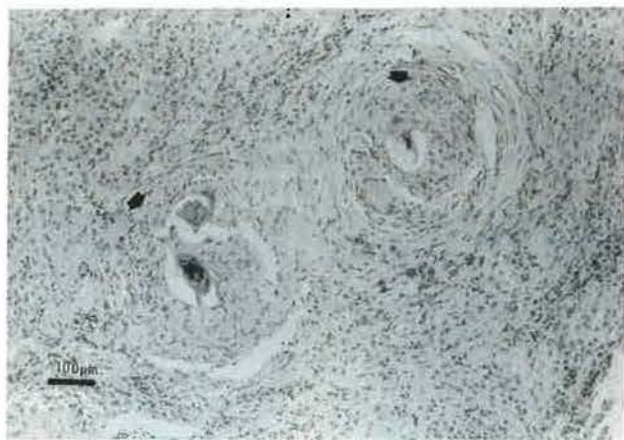


Fig. 2. — A: Transbronchial lung biopsy demonstrating a marked eosinophilic infiltration with granuloma (arrow) and some giant cells (haematoxylin-eosin stain; magnification: ×40) Bar= 100 μm. B: Inside the granuloma eggs of schistosoma with central miracidium and egg core are seen (haematoxylin-eosin stain: magnification: ×100). The subterminal sting (arrow) is characteristic for *Schistosoma mansoni*. Bar=100 μm.

Sputum smears from three days were negative for bacteria and mycobacteria. All cultured material from the sputum was negative after three days for bacteria and fungi, and after 8 weeks for *Mycobacterium tuberculosis*. An intracutaneous tuberculin test was found to be positive at 0.1 IU (purified protein derivative-standard (PPD-S)). Other skin tests for candida, aspergillus and atypical mycobacteria (recall antigen tests) were negative. Arterial blood gases obtained while breathing room air revealed pH 7.39, arterial carbon dioxide tension (Paco₂) 5.51 kPa, arterial oxygen tension (Pao₂) 11.05 kPa and oxygen

to be vital eggs of schistosoma with characteristic central miracidium and egg cores. A subterminal sting of the eggs provided evidence for *Schistosoma mansoni* (fig. 2 A and B). No worms, tuberculous lesions or mycobacteria were seen in any of the biopsy specimens.

Because of these results of bronchoscopy, an intensive search for parasites was initiated. In faecal specimens hookworm eggs and *Entamoeba histolytica* cysts were found. Serological tests for parasites (filaria, ascaris, hookworms, strongyloides, paragonimus, trichinella, toxocara canis, echinococcus, amebiasis,

cryptosporidia and toxoplasma) were negative. Urine studies revealed no parasites. After treatment with paromomycinsulphate (25 mg·kg⁻¹ for 5 days) and mebendazole (10 mg·kg⁻¹ for 3 days) stool specimens were negative for hookworms and amebiasis.

Investigation of the serum for schistosomiasis revealed a moderate antibody titre of 1:32 (enzyme-linked immunosorbent assay (ELISA) technique, normal value <1: 8). The search for schistosomiasis eggs and worms in all other specimens (faeces, urine) was negative. Sonographic investigation of the liver, the spleen and the bladder and a computed tomographic (CT) scan of the abdomen revealed no signs of intestinal, hepatosplenic or urinary tract schistosomiasis. Echocardiographic studies showed no signs of pulmonary hypertension or right-heart disease, and a perfusion scan of the lung was normal except for a reduced deposition of the tracer inside the infiltration.

The patient was treated with 40 mg·kg⁻¹ praziquantel for 1 day. This therapy was well tolerated without side-effects. Chest X-ray after 2, 4 and 6 days revealed no deterioration. After six weeks, the infiltrate and adenopathy nearly completely resolved, leaving only a small bulla and a slightly increased density of the right upper lobe. After 8 weeks, the serum IgE level was 210 U·l⁻¹ and the eosinophils were decreased to 4%.

Discussion

As many as 200 million people worldwide may be infected with the schistosomiasis species [2]. Most infected individuals show only few, if any signs or symptoms of the infection and only a small minority develop a serious disease [3]. Humans become infected after contact with water containing the infective stage of the parasite called cercaria which develops in a specific snail. Cercariae penetrate the skin and there transform into schistosomules. After 2 days, the schistosomules migrate to the lung and the portal vein. After 1–3 months, the adult forms of schistosoma start to deposit eggs, mostly in the bladder and the intestinal veins. The eggs are excreted *via* the urine or faeces into the water, where a ciliated stage of the parasite enters the snails. There is no replication of the worms themselves within the body [1].

Pulmonary schistosomiasis was first described in natives from South Africa by TURNER [4] as early as 1908. Three different forms of pulmonary involvement in schistosomiasis infection have so far been described. In acute schistosomiasis, which occurs mostly with *S. haematobium*, a syndrome of acute illness including fever, chills, anorexia, weight loss, abdominal pain, diarrhoea, myalgias, and a dry cough may develop 2–6 weeks after exposure [5, 6]. Chest X-rays of these patients typically reveal a miliary mottling resembling miliary tuberculosis or condensed basilar and midzone infiltrates; this form of the disease is usually seen in the "Katayama syndrome" [7, 8]. The exact aetiology of this syndrome is still

unclear [9]. It seems that the pulmonary involvement in "Katayama syndrome" is a form of allergic alveolitis [10, 11], because high levels of immune complexes were found in the serum. The syndrome is self-limiting and usually subsides over a period of 1–2 months [9]. Specific therapy can shorten the course of acute schistosomiasis. No data about persisting forms of this syndrome or persisting chest X-ray changes are reported in the literature [1, 10].

In chronic schistosomiasis, the infection involves the liver and the spleen. In the course of hepatic injury, a presinusoidal fibrosis occurs which may lead to an increase of portosystemic collaterals [12]. Eggs of the parasite released into these vessels are spread throughout the body, and mainly into the lung, where they cause a pulmonary arteriitis [13]. Histologically, the eggs are localized intravascularly and the vessels are surrounded by granulomatous formations of macrophages and eosinophils [14]. Up to 25% of patients with hepatosplenomegaly and portal hypertension develop evidence of pulmonary involvement, however, only 5% progress to pulmonary hypertension and cor pulmonale [10, 14]. Pulmonary symptoms in chronic schistosomiasis include dyspnoea on exercise and dry cough. Progression to cor pulmonale is associated with cyanosis, severe dyspnoea, and right heart failure. In chronic schistosomiasis chest X-rays reveal a fine diffuse nodular pattern and lung function tests show decreased lung volumes, an impairment of diffusion, a decreased Pao₂ and an abnormal perfusion-ventilation ratio [14–16]. At this stage of the disease, treatment of schistosomiasis can prevent further embolism of eggs into the lung, but does not change the existing functional impairment of the lung.

A third form of pulmonary involvement in schistosomiasis infection has been described under antischistosomal therapy [17, 18]. In these cases, development of new infiltrates on the chest X-ray may occur, and the patients may develop eosinophilia and new pulmonary symptoms such as coughing or wheezing [19]. This form of pulmonary schistosomiasis may be due to a new embolism of dead worms and eggs into the lung. The syndrome is self-limiting and may reflect an immunological response to a new release of antigens [17].

Our patient revealed several atypical features of pulmonary schistosomiasis and is a good example of the difficulties involved in the differential diagnosis of this type of pulmonary schistosomiasis. Firstly, the radiological pattern was unusual. Most descriptions of chest X-rays include a miliary nodular pattern or diffuse homogeneous infiltrates, depending on the form of pulmonary schistosomiasis. This patient's chest X-rays showed a cavity, a parenchymatous infiltrate in the upper right lobe and a right hilar adenopathy strongly mimicking acute tuberculosis. As tuberculosis is a widespread disease in African countries and the patient had a highly positive tuberculin skin test, there was some probability for the diagnosis of acute pulmonary

tuberculosis. However, most of the patients with this type of tuberculosis will have a positive sputum smear for acid-fast bacteria. The fact that we were unable to find mycobacteria in the sputum of this patient with a cavitory infiltrate led to the initiation of invasive diagnostic procedures. Here, again, the situation was difficult, because the endobronchial findings and the histological demonstration of epitheloid-cell granulomas were consistent with the diagnosis of pulmonary tuberculosis. Careful examination of the small specimens obtained from transbronchial biopsy finally revealed the diagnosis of pulmonary schistosomiasis.

In other cases of direct pulmonary schistosomiasis, the pulmonary involvement is secondary to a systemic infection, which can be detected by examination of the liver, the intestine or the urinary tract. In our patient, we were unable to demonstrate any sign of schistosomiasis in other organs than the lung. The cavitory lesion was probably due to numerous egg emboli and related necroses. Lymphadenopathy and the infiltration of the upper lobe may reflect an acute inflammatory reaction due to the antigen presentation by schistosoma eggs.

Therapy with praziquantel has an effect only on the worms themselves but not on the eggs. Nevertheless, effective therapy is able to stop egg embolism into the lung, thereby making it possible to prevent further destruction of the parenchyma. Therefore, the improvement of the infiltrates after therapy may be due to a self-limiting inflammatory reaction but could not have any effect on the structural changes of the lung parenchyma. The possibility of parasitic infections with atypical chest X-ray findings should be considered, when patients coming from endemic areas with tuberculosis and parasitic diseases are evaluated. Even when cavitory tuberculosis is highly probable, failure to demonstrate mycobacteria in the sputum should lead to the initiation of invasive diagnostic procedures, such as transbronchial biopsies via fibrebronchoscopy.

References

- Jordan P, Webbe G. - Schistosomiasis, epidemiology, treatment and control. Heinemann Medical, London, 1982.
- Nash TE, Cheever AW, Ottesen EA, Cook JA. - Schistosome infections in humans: perspectives and recent findings. *Ann Intern Med*, 1982, 97, 740-754.
- Nash TE. - Schistosomiasis. In: Harrison's principles of internal medicine. E. Braunwald, U.J. Isselbacher, R.G. Petersdorf, J.D. Wilson, J. Martin, A.S. Fanci. eds, McGraw-Hill, New York, 1987, pp. 810-814.
- Turner GA. - Pulmonary bilharziosis in South Africa. *Parasitology*, 1908, 1, 195-204.
- Clark WD, Cox PM, Ratner LH, Carrera-Coronas R. - Acute *Schistosomiasis mansoni* in 10 boys. *Ann Intern Med*, 1970, 73, 379-385.
- Diaz-Rivera RS, Ramos-Molares F, Koppisch E, Gracia-Palmeri MR, Cintron-Rivera AA, Marchand EJ, Gonzales O, Torregrosa MV. - Acute Manson's schistosomiasis. *Am J Med*, 1956, 21, 918-943.
- Ritchken J, Gelfand M. - Katayama disease, early toxemic stage of bilharziosis. *Br Med J*, 1954, 1, 1419-1420.
- Gelfand M. - Pulmonary schistosomiasis in the early "Katayama" phase of the disease. *J Trop Med Hyg*, 1966, 69, 143-144.
- Hiatt RA, Sotomayor ZR, Sanchez G, Zambrana M, Knight WB. - Factors in the pathogenesis of acute *Schistosomiasis mansoni*. *J Infect Dis*, 1979, 139, 659-666.
- Barrett-Connor E. - Parasitic pulmonary disease. *Am Rev Respir Dis*, 1982, 126, 558-563.
- Hiatt RA, Ottesen EA. - Serial observations of circulating immune complexes in patients with acute schistosomiasis. *J Infect Dis*, 1980, 142, 665-666.
- Maciera-Coelho E, Durate CS. - The syndrome of portopulmonary schistosomiasis. *Am J Med*, 1967, 43, 944-950.
- Andrade ZA, Andrade SG. - Pathogenesis of schistosomal pulmonary arteriitis. *Am J Trop Med Hyg*, 1970, 19, 305-310.
- Farid Z, Greer JW, Ishak KG, El Nagah AM, Le Golvan PC, Mousa AH. - Chronic pulmonary schistosomiasis. *Am Rev Tuberc Pulm Dis*, 1959, 79, 119-133.
- Fulleihan FJD, Habayabeh A, Abdallah A, Moussa A, Saif M, Srougi M, Kent DC. - Respiratory function in moderate schistosomal infection. *Am Rev Respir Dis*, 1969, 100, 651-661.
- Frayser R, DeAlonso AE. - Studies of pulmonary function in patients with *Schistosomiasis mansoni*. *Am Rev Respir Dis*, 1967, 95, 1036-1040.
- Ottesen EA, Weller PF. - Eosinophilia following treatment of patients with *Schistosomiasis mansoni* and Bancroft's filariasis. *J Infect Dis*, 1979, 139, 343-347.
- Pedroso ERP, Lambertucci JR, Greco DB. - Pulmonary *Schistosomiasis mansoni*: post-treatment pulmonary clinical-radiological alterations in patients in the chronic phases. *Trans Royal Soc Trop Med Hyg*, 1979, 81, 778-781.
- Weller PF. - Parasitic pneumonias. In: Respiratory infections: diagnosis and management. J.E. Pennington ed., 2nd ed, Raven Press, New York, 1988, pp. 583-600.

Observation clinique: schistosomiase pulmonaire ressemblant à une tuberculose pulmonaire aiguë. T. Schaberg, W. Rahn, P. Racz, H. Lode.

RÉSUMÉ: L'atteinte pulmonaire dans la schistosomiase est caractérisée habituellement par un aspect de miliaire ou des infiltrats nodulaires diffus. Dans la plupart des cas, l'atteinte pulmonaire est associée à une atteinte cliniquement apparente d'autres organes. Cette observation concerne un patient de 35 ans, qui a développé une cavité, un infiltrat parenchymateux et une adénopathie hilare, en rapport avec une schistosomiase pulmonaire. L'on a trouvé des oeufs de schistosomes au niveau du poumon dans les biopsies transbronchiques. L'atteinte pulmonaire de la schistosomiase fait l'objet d'une revue, et les aspects atypiques qui peuvent entraîner des difficultés diagnostiques, particulièrement par comparaison avec la tuberculose, sont discutés. *Eur Respir J.*, 1991, 4, 1023-1026.