

Agnesis of the right pulmonary artery in a young asymptomatic girl

P. Morales, L. Miravet, V. Marco

Agnesis of the right pulmonary artery in a young asymptomatic girl. P. Morales, L. Miravet, V. Marco.

ABSTRACT: We report the case of a 13 yr old, asymptomatic girl with agnesis of the right pulmonary artery. In the context of a tuberculosis survey in her school, an X-ray examination disclosed a decreased volume of the right lung. Ventilation and perfusion scans and digital subtraction angiography established the diagnosis.

Eur Respir J., 1991, 4, 1301-1302.

Servicio de Neumología, Hospital Universitario La Fe, Valencia, Spain.

Correspondence: Dra. P. Morales, Servicio de Neumología, Hospital La Fe, Avda. Campanar 21, 46009 - Valencia, Spain.

Keywords: Asymptomatic pulmonary artery agnesis; right pulmonary artery, vascular malformation.

Received: March 27, 1991; accepted after revision August 19, 1991.

Isolated unilateral absence of the pulmonary artery (UAPA) is an uncommon anomaly [1-6]. More frequently, UAPA occurs in association with congenital cardiac defects such as Fallot's tetralogy, septal defects and patent ductus arteriosus [2]. When it occurs as an isolated anomaly, patients are generally asymptomatic and the defect may remain undetected throughout his/her life. Only a minority of cases will develop pulmonary hypertension. However, in some cases, the diagnosis is made at necropsy after a fulminant haemoptysis [3].

Case report

A 13 yr old girl had an X-ray picture taken in the context of a tuberculosis survey in her school. A decreased volume of the right lung with ipsilateral displacement was observed, and she was referred to our hospital for diagnosis.

She was of normal appearance, in good health, and played with her classmates at the same level of physical exercise. Her past history was unrevealing. Physical examination was normal.

Haematocrit, haemoglobin and the biochemical profile were also within normal limits. Arterial blood gases while breathing room air showed: arterial oxygen tension (P_{aO_2}) 100 torr, arterial carbon dioxide tension (P_{aCO_2}) 30 torr and pH 7.43.

The results of pulmonary function study showed a discrete ventilatory restriction: vital capacity (VC) 2.22 l (73% of predicted); forced vital capacity (FVC) 2.22 l (73%); total lung capacity (TLC) 3.35 l (81%); forced expiratory volume in one second (FEV_1) 2.05 l (68%) and the ratio FEV_1/FVC 92% [7].

Chest X-ray radiographs at inspiration (fig. 1) and expiration showed a loss of volume of the right lung,

ipsilateral displacement, anterior herniation of the left lung and hyperlucency of the left lung due to compensatory hyperinflation. Computed tomography (CT) scans confirmed these findings. The patient's electrocardiogram (ECG) was normal.

Fibreoptic bronchoscopy revealed a normal disposition of bronchi of both lungs, of normal calibre, without endobronchial lesions.

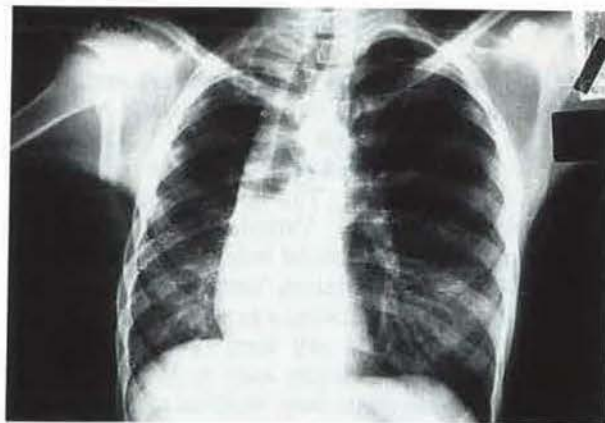

Fig. 1 - Chest X-ray film showing a loss of volume of the right lung, ipsilateral displacement and anterior herniation and hyperlucency of the left lung.

Ventilation and perfusion scans demonstrated absence of perfusion to the right lung with normal perfusion to the left lung. Ventilation was normal in both lungs. An angiography performed by digital subtraction showed the absence of the right pulmonary artery; the left pulmonary vasculature was normal (fig. 2). No other anomalies of the great vessels were observed; this was corroborated by an aortogram.

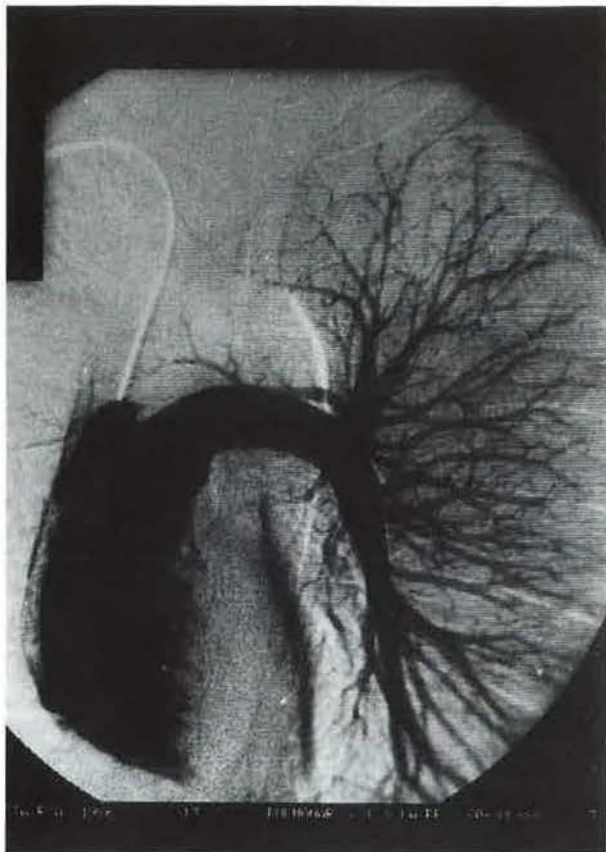


Fig. 2 - Digital subtraction angiography showing absence of the right pulmonary artery.

Discussion

Proximal absence of the right pulmonary artery is a rare malformation [2]. It is due to the lack of development of the right sixth aortic arch. The distal portion is sometimes present in the form of a small vessel or a fibrous cord. The intrapulmonary arterial vessels develop normally. Vascularization of the lung is carried out from the arterial bronchial vessels. The size of the lung is reduced, usually of decreased radio-lucency, with diminished vascular markings. The bronchial tree is normal and there is no air-trapping in the lung. Other pathologies such as Macleod's syndrome or the hypogenetic lung syndrome, may present with a similar radiographic appearance. However, other radiographic findings may help to make the differential diagnosis. In Macleod's syndrome, although diminutive, a hilum is present. On the other hand, there is air-trapping of the affected lung during a forced expiration manoeuvre [8]. In the hypogenetic lung syndrome, a diminutive hilum of abdominal configuration is also present, usually associated with cardiac and bronchial tree malformations [8].

In contrast with left pulmonary artery agenesis, which in most cases is associated with other

cardiovascular malformations, right pulmonary agenesis is more often an isolated finding. The clinical presentation of these patients is variable: about 30% of patients may remain asymptomatic throughout their lives [1], with the diagnosis being a chance radiological finding. Others suffer recurrent chest infections, haemoptysis of variable severity, sometimes massive, congestive heart failure secondary to pulmonary artery hypertension, and even sudden death without previous knowledge of the condition [3]. In our patient, after the initial radiological suspicion of right pulmonary artery agenesis, the diagnosis was confirmed using methods of increasing complexity and risk.

Considering that the patient was asymptomatic, according to the recommendations of the other authors [2, 4], no therapeutic intervention was used. A year from the initial diagnosis, the patient is doing well, and is completely asymptomatic.

References

1. Toews WH, Pappas G. - Surgical management of absent right pulmonary artery with associated pulmonary hypertension. *Chest*, 1983, 84, 497-499.
2. Ko T, Gatz MG, Reisz GR. - Congenital unilateral absence of a pulmonary artery: a report of two adult cases. *Am Rev Respir Dis*, 1990, 141, 795-798.
3. Mehta AC, Livingston DR, Kawalek W, Golish JA, O'Donnell JK. - Pulmonary artery agenesis presenting as massive hemoptysis. A case report. *Angiology*, 1987, 38, 67-71.
4. Presbitero P, Bull C, Haworth ShG, de Leval MR. - Absent or occult pulmonary artery. *Br Heart J*, 1984, 52, 178-185.
5. Taguchi T, Ikeda K, Kume K, Nagasaki A, Goto S, Matsuo S, Hasuo K, Tamura S. - Isolated unilateral absence of left pulmonary artery with peribronchial arteriovenous malformation showing recurrent hemoptysis. *Pediatr Radiol*, 1987, 17, 316-318.
6. Stiller RJ, Soberman S, Turetsky A, Lockwood Ch, Haddad R. - Agenesis of the pulmonary artery: an unusual cause of dyspnea in pregnancy. *Am J Obstet Gynecol*, 1988, 158, 172-173.
7. Polgar G, Promadhat V. - Pulmonary function testing in children: techniques and standards. W.B. Saunders Co., Philadelphia, 1971.
8. Fishman AP. - Tratado de Neumología. A.P. Fishman ed., Doyma, Barcelona, 1983, pp. 154-941.

Observation clinique. Agénésie de l'artère pulmonaire droite chez une fille asymptomatique. P. Morales, L. Miravet, V. Marco.

RÉSUMÉ: Il s'agit de l'observation d'une fille asymptomatique âgée de 13 ans, atteinte d'une agénésie de l'artère pulmonaire droite. C'est dans le contexte d'une recherche de la tuberculose à son école, qu'un examen radiologique a décelé une diminution de volume du poumon droit. Les scanners de ventilation et de perfusion, ainsi que l'angiographie digitale de soustraction, ont permis d'établir le diagnostic.

Eur Respir J, 1991, 4, 1301-1302.