

CASE STUDY

Giant bilateral fibrous dysplasia of first ribs: compression of mediastinum and thoracic outlet

V. Thomas de Montpréville, E. Dulmet, R. Ponlot, P. Dartevelle

Giant bilateral fibrous dysplasia of first ribs: compression of mediastinum and thoracic outlet. V. Thomas de Montpréville, E. Dulmet, R. Ponlot, P. Dartevelle. ©ERS Journals Ltd 1995.

ABSTRACT: A 43 year old woman presented with two large bilateral tumours of the first ribs that compressed the right subclavian vessels, trachea and oesophagus and led to right arm oedema, severe dyspnoea and dysphagia. The resected tumours showed typical histological features of fibrous dysplasia without malignant transformation. The right tumour weighed 1.5 kg and measured 17×13×10 cm.

This report demonstrates that major surgery is still possible for resection of such exceptional giant compressive lesions, since fibrous dysplasia is a benign and non-infiltrative tumour.

Eur Respir J., 1995, 8, 1028–1029.

Depts of Pathology and of Thoracic and Vascular Surgery and Heart-Lung Transplantation, Marie Lannelongue Surgical Centre (Université Paris-Sud), Le Plessis-Robinson, France and Catholic University of Louvain, St Luc Clinics, Brussels, Belgium.

Correspondence: V. Thomas de Montpréville, Service d'Anatomie Pathologique, Centre Chirurgical Marie Lannelongue, 133 Avenue de la Résistance, 92350 Le Plessis-Robinson, France

Keywords: Chest wall tumours, fibrous dysplasia, mediastinum, rib, thoracic outlet syndrome

Received: June 15th 1994

Accepted after revision January 29 1995

Fibrous dysplasia is a benign bony abnormality that may be monostotic or polyostotic [1]. Surgical treatment is usually required during growth for pathological fractures or deformities of tubular bones [2]. In the costal region, fibrous dysplasia is the most frequent benign tumour [3], and surgical intervention is usually performed for diagnostic purposes [4]. We present an exceptional case with severe manifestations.

Case report

A 43 year old woman was known to have rib radiological abnormalities from the age of 25 yrs. These lesions were asymptomatic but grew progressively. The left lesion, which led to aesthetic complications and eventually to dyspnoea and dysphagia, was resected in 1988. Diagnosis of fibrous dysplasia was established by examination of the surgical specimen that weighed 600 g.

Four years later, the patient again complained of dysphagia and of a severe dyspnoea, that required a tracheal stent endoprosthesis. A tumour was palpable in the right supraclavicular space, where it compressed vascular structures leading to weakening of the radial pulse and arm oedema. There were no symptoms of brachial plexus lesion, recurrent or phrenic palsy, or vena cava syndrome. Computed tomography (CT) scan (fig. 1) and radiographs (figs. 2a) of the chest showed the large thoracic mass and revealed another small bony lesion.

The tumour was completely removed by an anterior transcervical-thoracic approach used for resection of lung tumours invading the thoracic inlet [5] (fig. 2b). Briefly, a cervicotomy was performed with an L-shaped incision

that followed the anterior border of the sternocleidomastoid muscle and the second rib. The internal half of the clavicle was removed and the subclavian vein was resected. Invaded ribs were then sectioned and the tumour was progressively removed. There were only loose adhesences with lung and with subclavian and mediastinal structures. The postoperative course was uneventful, with abolition of all symptoms. The patient is well, 18 months following surgery.

The surgical specimen weighed 1,500 g. The hard and partially calcified tumour arising from anterior part of the two first ribs measured 17×13×10 cm. The internal side of the tumour, covered with parietal pleura, was smooth and lobulated. Microscopically, the lesion had

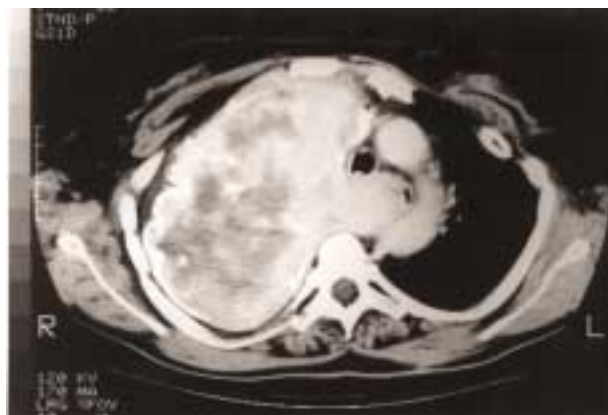

Fig. 1. – Computed tomography (CT) scan showing the solid mass that arises from the anterior part of first ribs, fills the right superior hemithorax and extends into the mediastinum, where it shifts major structures.

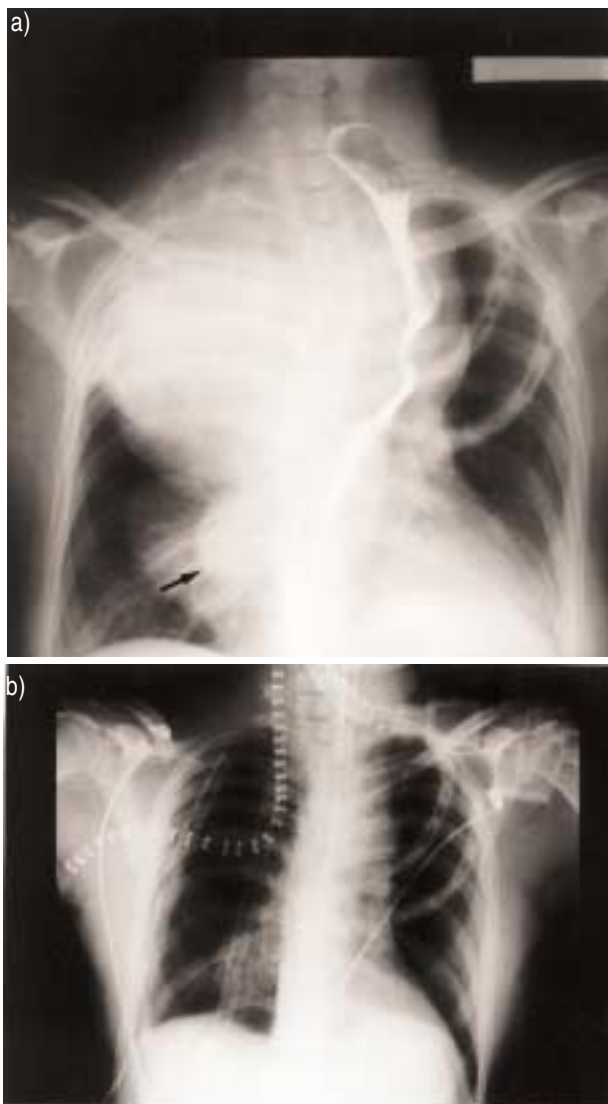


Fig. 2. – a) Preoperative chest radiogram, showing the tumoral mass that shifts the oesophagus (marked with contrast material) to the left. Another smaller posterior costal lesion is indicated by the arrow. A prosthesis replaces the left first ribs, previously resected. b) Postoperative radiogram. The tumour has been resected with the invaded ribs after removal of the internal half of the clavicle. The L-shaped incision is indicated by metallic clips.

a typical histological appearance of fibrous dysplasia (fig. 3) and produced a thinning of the rib cortex. There were several haemorrhagic cysts measuring less than 2 cm, which had no cellular lining. Neither cellular atypia, mitotic features, nor necrosis were observed.

Discussion

Thoracic outlet syndrome, an unusual event resulting from fibrous dysplasia of the first ribs, has been reported previously [6, 7]. Costal lesions of fibrous dysplasia are also known to develop after the end of growth because of cystic degeneration [8], with occasional formation of an aneurysmal cyst [9]. This enlargement may mimic sarcomatous transformation [8], but malignancy occurs in less than 1% of cases of fibrous dysplasia [10].



Fig. 3. – Histological appearance diagnostic of fibrous dysplasia. A dense collagen tissue with regular fibroblasts and osseous trabeculae. These trabeculae have Chinese letter shapes and are not layered by osteoblasts. (Haematoxylin and eosin stain; internal scale marker=100 μ m).

Development of a giant benign costal mass compressing the mediastinum is exceptional. Since this complication is rare, a preventive resection for small fibrous dysplasia of the first ribs is probably not justified. Even when the tumour is massive, surgical resection is still possible, since fibrous dysplasia of bone is a benign and non-infiltrative tumour.

Acknowledgements: The authors thank C. Brink for reviewing the manuscript and D. Pétraz for photographic work.

References

- Schajowicz F. Histological typing of bone tumours. WHO International Histological Classification of Tumours. In: Sobin LH, ed. 2nd edn. Berlin; Springer-Verlag, 1993.
- Andrisano A, Soncini G, Calderoni PP, Stilli S. Critical review of infantile fibrous dysplasia: surgical treatment. *J Ped Orthop* 1991; 11: 478–481.
- Waller DA, Newman RJ. Primary bone tumours of the thoracic skeleton: an audit of the Leeds regional bone tumour registry. *Thorax* 1990; 45: 850–855.
- Cavanaugh DG, Cabellon S, Peake JB. A logical approach to chest wall neoplasms. *Ann Thorac Surg* 1986; 41: 436–437.
- Dartevielle PG, Chapelier AR, Macchiarini P, et al. Anterior transcervical-thoracic approach for radical resection of lung tumors invading the thoracic inlet. *J Thorac Cardiovasc Surg* 1993; 10: 1025–1034.
- Melliere D, Ben Yahia NE, Etienne G, Becquemin JP, de Labareyre H. Thoracic outlet syndrome caused by tumor of the first rib. *J Vasc Surg* 1991; 51: 888–892.
- Karanjia ND, Sayer RE. Thoracic outlet syndrome due to monostotic fibrous dysplasia of the first rib. *J R Coll Surg Edinb* 1990; 35: 111.
- Simpson AHRW, Creasy TS, Williamson DM, Wilson DJ, Spivey JS. Cystic degeneration of fibrous dysplasia masquerading as sarcoma. *J Bone Joint Surg (Br)* 1989; 71: 434–436.
- Tresserra F, Rami R, Salas A et al. Polyostotic coexisting fibrous dysplasia and aneurysmal bone cyst of the chest wall. *Thorac Cardiovasc Surg* 1993; 41: 321–324.
- Ruggieri P, Sim FH, Bond JR, Unni KK. Malignancies in fibrous dysplasia. *Cancer* 1994; 73: 1411–1424.