

## CASE REPORT

# Transplantation of a lobe of lung from mother to child following previous transplantation with maternal bone marrow

U.G Svendsen\*, S. Aggestrup\*\*, C. Heilmann+, N. Jacobsen++, C. Koch+,  
B. Larsen†, A. Svejgaard++, B. Thisted†, G. Petterson\*\*.

*Transplantation of a lobe of lung from mother to child following previous transplantation with maternal bone marrow. U.G. Svendsen, S. Aggestrup, C. Heilmann, N. Jacobsen, C. Koch, B. Larsen, A. Svejgaard, B. Thisted, G. Petterson. ©ERS Journals Ltd 1995.*

**ABSTRACT:** A left lower lobe of the lung was transplanted from a mother to her child, who had previously received a maternal bone marrow transplant for an immune defect. Following the bone marrow transplantation, the child had developed severe pulmonary fibrosis.

Surgery and the early postoperative course have been uncomplicated. Immunosuppression with corticosteroids was administered for a short period, after which all immunosuppressive treatment was discontinued.

The operation and the outcome are described both in the donor and recipient. Rehabilitation was slow, but one year later the patient is doing well.

*Eur Respir J., 1995, 8, 334–337.*

Depts of \*Cardiology, \*\*Cardiothoracic Surgery, †Pediatrics, ††Hematology, and †Anesthesiology, The National University Hospital, Rigshospitalet, Copenhagen, Denmark.

Correspondence: U.G. Svendsen, Dept. of Medicine B, Hjertecentret 2142, National University Hospital, Rigshospitalet, Blegdamsvej 9, 2100-Copenhagen, Denmark

Keywords: Bone marrow transplantation-related donor lung lobe transplantation

Received: April 29 1994; Accepted after revision December 29 1994

Few reports of living donor lung or lung lobe transplantation have been published [1], but there have been verbal presentation of lobe transplantations from parents to children [2]. The conditions under which a living-donor lung or lung lobe transplantation could be justified and acceptable have been outlined previously [3].

Experimental organ transplantation in animals following syngeneic bone marrow transplantation (BMT) can be performed without immunosuppression [4]. A few patients have been described who have received an organ allograft following BMT from the same donor [5], or from other donors [6, 7]. The results indicate that these patients need little or no immunosuppression.

We report a case of mother to child lung lobe transplantation for progressive lung fibrosis with extreme reduction of lung function following a previous maternal BMT.

### Case Report

An 11 year old girl was kept under surveillance from birth because her older brother had died at the age of 5 yrs from interstitial pneumonia. An autopsy of this brother revealed absent thymus and a general cellular depletion of the lymphoid organs. Apart from lobar pneumonia at the age of 4 yrs and periods of cough associated with positive cultures of cytomegalovirus (CMV) from her urine, the girl had normal general development and normal computed tomographic (CT) scan of the chest.

However, her immune system, as reported in detail previously [8, 9], became increasingly abnormal.

The immunological findings before BMT were characterized by moderate lymphopenia, decreased serum immunoglobulin A (IgA), and gradual loss of proliferative lymphocyte response to levels below 20% of normal. Analysis of T-lymphocyte subsets revealed that only approximately 30% of the CD3+ cells expressed the usual  $\alpha\beta$ -T-cell receptor (TCR), whereas about 70% expressed the  $\gamma\delta$ -TCR. These (abnormal) cells were all CD4-, and their expression of CD8 and CD5 surface antigens varied. Thymic biopsy revealed poor differentiation, with only a single Hassall's corpuscle and selective severe reduction of medullary epithelium.

Considering the patient's family history and the evidence of progressive loss of immune competence, a BMT from the mother to the 5 year old child was performed in 1988, even though the recipient was still in good health and one HLA-DR antigen mismatch in both directions was present. The HLA class I antigens were identical. She had been conditioned for BMT with busulphan, cyclophosphamide and antithymocyte globulin.

Following BMT, lymphocyte counts normalized, and the proliferative response became quasi-normal. The distribution of  $\alpha\beta$ -TCR and  $\gamma\delta$ -TCR carrying cells was also normal.

The early post-BMT period was uneventful, except for moderate (grade II) acute graft *versus* host disease. However, 2–3 months later she developed progressive lung disease with a mixed obstructive and restrictive pattern of

lung function as well as diminished diffusion capacity. Chest radiograph and CT scans showed pulmonary fibrosis, but no bronchiectasis. An open lung biopsy was consistent with graft *versus* host disease, but the diagnosis could not be ascertained. Attempts to treat the condition with medication, using cyclosporin-A, prednisone, ganciclovir, and intravenous immunoglobulin were unsuccessful. In the following years, respiratory function deteriorated and the patient became totally dependent upon oxygen support. Six months prior to transplantation, she was completely bedridden. It was no longer possible to measure lung function due to her poor general condition. With an inspiratory oxygen fraction ( $F_{iO_2}$ ) of 50%, arterial oxygen tension ( $P_{aO_2}$ ) was 14.8 kPa, arterial carbon dioxide tension ( $P_{aCO_2}$ ) 13.1 kPa, and arterial oxygen saturation ( $S_{aO_2}$ ) 97%. The question of lung transplantation was raised by the family, who suggested the mother as a donor. The ethical problems associated with such a transplantation were fully discussed, but the wishes of the family were finally respected, and it was decided to perform the operation.

### Preoperative considerations

Before the lung transplantation, it was confirmed using both a serological technique and a polymerase chain reaction technique, that the child was a complete chimera, expressing only maternal HLA class II antigens and genes on and in the peripheral blood leucocytes (both the granulocytes and B- and T- lymphocytes).

The donor (mother) was a 45 year old nonsmoker in good physical condition. Total lung capacity of the donor was 4.4 l (92% of predicted), whereas the predicted TLC for the recipient was 1.7 l. Forced expiratory volume

in one second ( $FEV_1$ ) of the donor was 3.0 l (112% pred) and forced vital capacity (FVC) 3.6 l (100% pred). Isotope scintigraphy showed a normal and equal distribution of ventilation and perfusion between the two lungs. The left lower lobe was considered to be of good size for replacement of the recipient's left lung, as based on known and predicted lung volumes, physical appearance of the donor and recipient, and on comparison of chest radiograph (fig. 1). It was estimated that the donor would lose 25% of her lung function following lobectomy.

### The operation

On arrival in the operating room, the recipient's  $P_{aCO_2}$  was 26 kPa without premedication, while arterial oxygen saturation with  $F_{iO_2}$  of 100% was 95%. After induction of anesthesia, intubation, and ventilation,  $P_{aCO_2}$  was reduced to 10 kPa. A heart-lung machine was available on "standby".

Left thoracotomy was performed on the recipient, and the hilar structures were dissected free. Test clamping of the left pulmonary artery was sufficiently well tolerated.

The donor had a well developed fissure between both her left lobes. These were carefully separated and artery, vein, and division of the lower lobe bronchus were dissected free. The segmental artery to the sixth segment originated just opposite the segmental artery to the lingula. No heparin was given to the donor. Immediately following clamping of the artery and division of the vein, the lobe was perfused with modified Eurocollins solution. The artery was divided obliquely, such as to allow a primary suture and blood flow to the lingula artery of the upper lobe. The bronchus was divided immediately

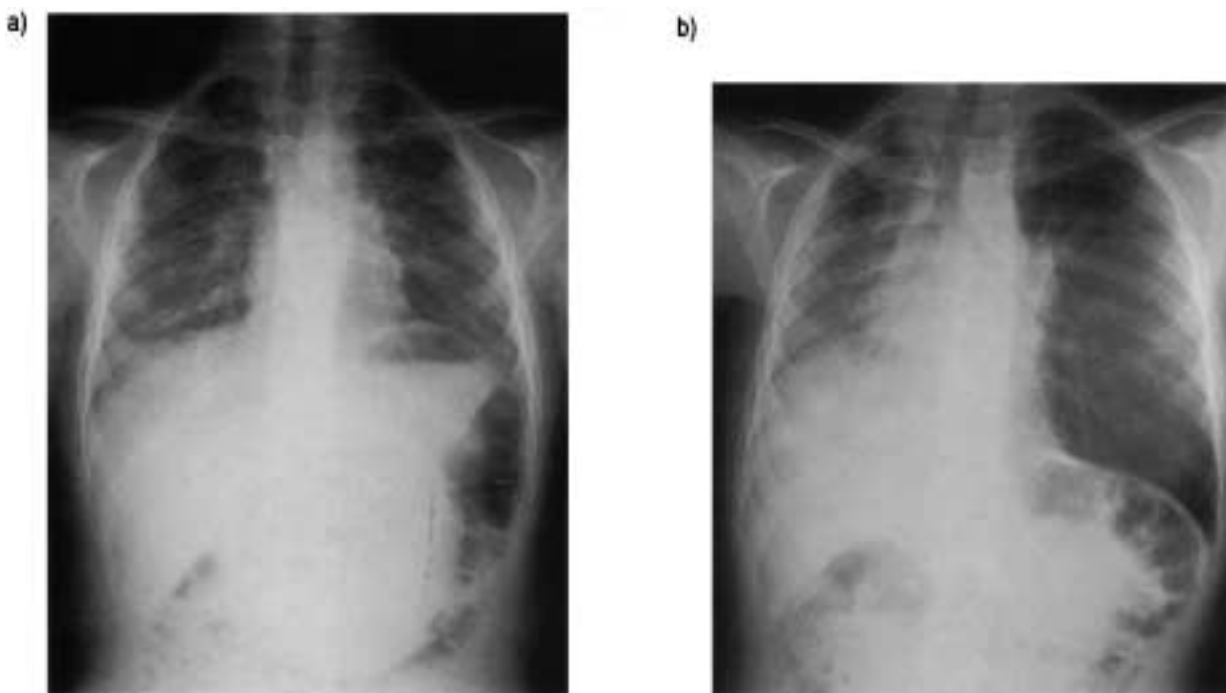


Fig. 1. - Chest radiographs from the patient: a) before and b) 4 months after left-sided lung lobe transplantation.

below the upper lobe bronchus. Total ischaemic time of the graft was 40–45 min.

The recipient pneumonectomy was performed taking into consideration the arterial anatomy of the lobe to be transplanted, and leaving some extra length of the pulmonary artery. By leaving this sufficient length of recipient pulmonary artery, any possible donor anatomy could be dealt with; and, therefore, pulmonary angiography of the donor was unnecessary. The recipient main bronchus was divided distally just proximal to the origin of the upper lobe bronchus. The pulmonary artery and veins were clamped centrally. The donor lobe was placed posteriorly in the pleural cavity and bronchial, pulmonary artery, and vein anastomoses were performed using 5–0 Prolene® continuous running suture technique, except for the non membraneous part of the bronchus, which was sutured with interrupted Prolene® sutures. No wrapping of the bronchial anastomosis was performed because of a lack of available well-suited tissue. In addition, the donor bronchus had been divided almost inside the lung parenchyma to reduce ischaemic complications. After reperfusion and ventilation, the transplanted lobe appeared normal and of good size to fit the pleural space. The chest was drained and closed in standard fashion. Histological examination of the explanted lung showed fibrosis only.

#### Postoperative course

The patient was extubated after 24 h and the postoperative course was uneventful.  $Paco_2$  and  $Pao_2$  normalized within days and have remained normal. The patient was discharged from the intensive care unit after 3 days, and from the hospital after 24 days. Steroids were given perioperatively (100 mg methylprednisolone) but tapered rapidly to 2.5 mg·day<sup>-1</sup> after 7 days. They were completely discontinued after 16 weeks. No other immunosuppressive treatment was given. Even though saturation

was higher than preoperatively, weaning from oxygen proved to be a slow process, taking over 4 weeks, whereafter saturation remained normal. Mobilization and rehabilitation were slow, but progressed steadily. Serial bronchoscopies over the following months revealed satisfactory bronchial anastomotic healing.

During the first postoperative months, the child had persistent cough, but 14 months post-transplant she is making good progress and has resumed schooling. Her  $FEV_1$  of 0.5–0.7 l is below the predicted normal of 1.5 l for two lungs. On air, her  $Pao_2$  is 8.3 kPa,  $Paco_2$  5.8 kPa and  $Sao_2$  95%. There is still no need for immunosuppressive medication. We have abstained from postoperative transbronchial lung biopsy because the patient is a complete chimera, and to avoid complications of bleeding, infection and subsequent loss of lung function.

Antibiotics have been given to prevent recurrence and spreading of infection from the diseased right lung. Prior to transplantation, recurrent infections with *Haemophilus influenzae* caused problems; after the operation, infection from the right lung was apparent and antibiotic therapy had to be restarted.

Fourteen months after the transplantation, the donor is in good health without dyspnoea and with normal exercise performance.  $FEV_1$  has decreased to 2.2 l (normal range 2.0–3.3 l) and FVC to 2.6 l (normal range 2.4–3.8 l). Isotope scintigraphy showed that the remaining left lung had 25% of the total ventilation and perfusion. Chest radiograph (fig. 2a) before the operation and one year after (fig. 2b) shows only minor changes related to left lower lobectomy.

#### Discussion

Donor lung transplantation is still controversial and has so far been practised in a very limited number of cases. To our knowledge, only a few cases of transplant of a lobe from a parent to a child have been reported [2].

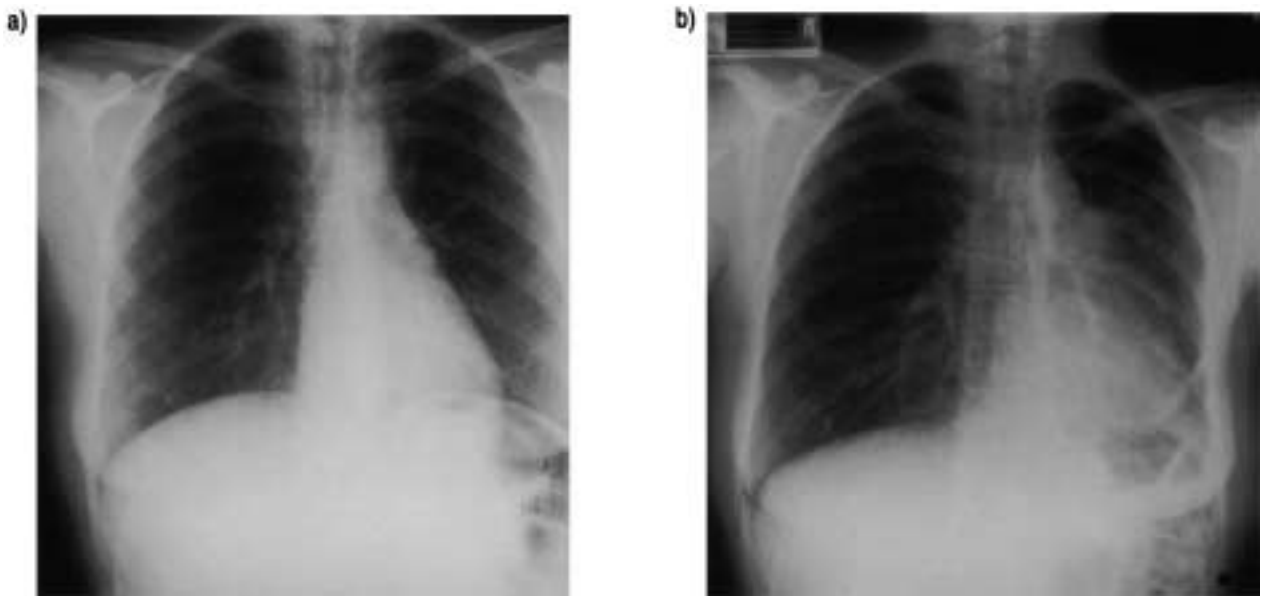


Fig. 2. – Chest radiography from the donor: a) before and b) 12 months after left lower lobectomy.

In our case, the left lower lobe was chosen and it could be transplanted without notable problems. Technically, transplant of any lobe is possible, but individual anatomical variations could make the procedure more or less demanding. Heparin was not given to the donor to decrease the bleeding risk. Bronchial healing was a concern, since neither bronchial revascularization nor anastomotic wrapping were technically feasible; however, normal primary healing occurred. By leaving a long recipient pulmonary artery stump, it was easy to perform a good arterial anastomosis in spite of a short artery on the donor side.

Experimental and clinical evidence supports the presumption that the previous BMT should have induced total immunological tolerance towards the donor HLA antigens. It was confirmed that the child only expressed maternal MHC class II antigens and genes on and in her leucocytes. The earlier "general depletion" of the lymphoid organs is expected to have disappeared when the lymphocyte counts and function normalized years before the lung transplantation. Therefore, the "general depletion" seems not to have been important in the acceptance of the lung graft.

Initial steroid treatment was considered necessary because of previous steroid therapy in relation to the BMT and lung disease.

Most of the postoperative problems were related to the residual diseased lung. Recurrent infections may still induce risks to the transplanted lung. Pneumothorax on both sides had been a recurrent problem before the transplantation, and there has been another episode on the right side since the transplantation. Persistent non-productive coughing remains a problem, and its underlying cause has not been determined. The possibility of an additional right lung transplantation has been discussed. This, however, would require immunosuppression because another maternal lung transplantation is excluded. Pneumonectomy, removal of the sick right lung, has also been discussed, but this would probably jeopardize a future right-sided transplantation if needed. It remains our belief that the underlying cause of the recipient's lung disease will be of importance for the long-term outcome.

If the BMT has indeed induced complete tolerance, and providing that the transplanted lobe does not suffer

acute or chronic rejection, this case will furnish a unique possibility to study the development, growth, and function of lung tissue transplanted from an adult to a child. Although the initial rate of rehabilitation has been slow, this has not been shown to be related to dysfunction of the transplanted lobe.

We conclude that lobe transplantation from an adult to a child is technically possible and a reasonable alternative in well-selected cases. The future of this procedure will depend on long-term results regarding lung function and growth.

#### References

1. Goldsmith MF. Mother to child: first living donor lung transplantation. *J Am Med Assoc* 1990; 264(21): 2724.
2. Starnes VA, Barr ML, Cohen RG, *et al.* Bilateral living related lobar transplantation for cystic fibrosis; initial experience. *J Heart Lung Transplant.* 1994; 13(1); Part 2 (Abstract 101): S57.
3. Shaw, LR, Miller JD, Slutsky AS, *et al.* Ethics of lung transplantation with live donors. *Lancet* 1991; 338: 678-681.
4. Main JM, Prehn RT. Successful skin homograft after the administration of high dosage X-irradiation and homologous bone marrow. *J Natl Cancer Inst* 1955; 15: 1023.
5. Sayegh MH, Fine NA, Smith JL, Rennke HG, Milford EL, Tilney NL. Immunologic tolerance to renal allografts after bone marrow transplantation from the same donor. *Ann Intern Med* 1991; 114: 954.
6. Calhoun JH, Levine S, Anqneto A, Bryan CL, Trinkle JK. Lung transplantation in a patient with a prior bone marrow transplant. *Chest* 1992; 102: 948.
7. Dark, J. Lung transplants in patients with prior bone marrow transplants. *Chest* 1994; 105: 327.
8. Geisler C, Pallesen G, Platz P, *et al.* Novel primary thymic defect with T-lymphocytes expressing  $\gamma\delta$ -T-cell receptor. *J Clin Pathol* 1989; 42: 705-711.
9. Koch C, Geisler C, Pallesen G, Jacobsen N. Novel genetic immune deficiency with relative absence of thymic medullary epithelium and increased number of circulating T-cells expressing  $\gamma\delta$ -T-cell receptor. Correction by BMT. *In: Chapel HM, Levinsky RI, Webster ADB, eds. Progress in Immune Deficiency. III.* London, Royal Society of Medicine Services Ltd. 1991; pp. 314-315.