

## Breathlessness in a teenager

I.B. Dahlén\*, G.N. Hillerdal, G.A. Wegenius, A.C. Henze

### Case history

An 18 yr old woman was referred for investigation of therapy-resistant asthma.

As a baby, she had had considerable nutritional problems. These problems decreased during infancy, but she was never able to swallow large mouthfuls.

As a young child, she was slightly troubled by breathlessness and this became more evident after the age of about 8 yrs. It was most apparent in connection with exercise and during episodes of upper respiratory infection. A chest roentgenogram from this period was interpreted as normal. Asthma medication gave no relief. Her physical capacity was poor and she was never able to run as fast as her peers. She developed the habit of sleeping with her mouth open and snored loudly.

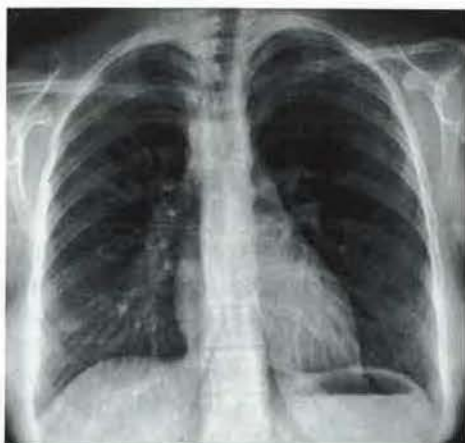

Fig. 1. - Posteroanterior chest roentgenogram.

Over the years, the patient's physical capacity continued to deteriorate, and she experienced shortness of breath and could hardly climb a flight of stairs. She noticed increased difficulties during the pollen season and when exposed to animals. However, a skin prick test and radioallergosorbent test (RAST) were negative and the total immunoglobulin E (IgE) level was low.

On physical examination, breathing sounds were normal, but during forced breathing stridor could be heard over the suprasternal area in both expiration and inspiration. Peak expiratory flow rate (PEFR) was  $230 \text{ l}\cdot\text{min}^{-1}$ . Methacholine challenge did not influence PEF.

Correspondence: \*I.B. Dahlén, Dept of Lung Medicine, Uppsala University, Akademiska sjukhuset, S-751 85 Uppsala, Sweden.

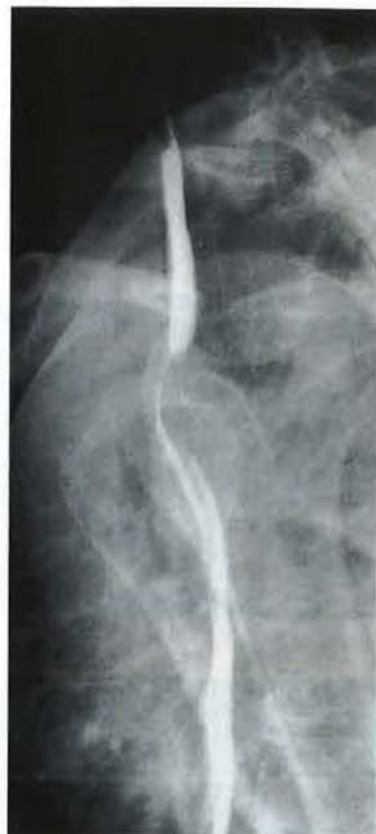

Fig. 2. - Barium swallow. Lateral view.

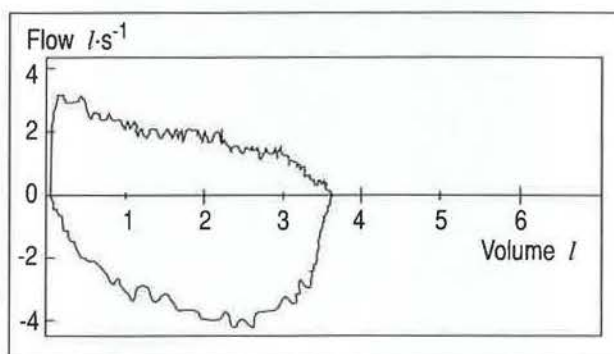


Fig. 3. - Flow-volume curve.

**BEFORE TURNING THE PAGE: - INTERPRET THE ROENTGENOGRAMS (FIGS 1 AND 2) AND THE FLOW-VOLUME CURVE (FIG. 3); - PROPOSE FURTHER EXAMINATIONS; - SUGGEST DIAGNOSIS AND TREATMENT.**

### Interpretation of chest roentgenogram

The chest roentgenogram revealed a right-sided aortic arch (fig. 1). At fluoroscopy of the chest, the trachea was found to be compressed at the level of the aortic arch.

The barium swallow disclosed anterior displacement of the oesophagus with posterior compression of the trachea (fig. 2).

### Interpretation of the flow-volume curve

Maximal expiratory flow was reduced but expiratory flow at low lung volumes was almost normal. Beta-agonists gave no improvement. There was also a marked reduction in maximal inspiratory flow.

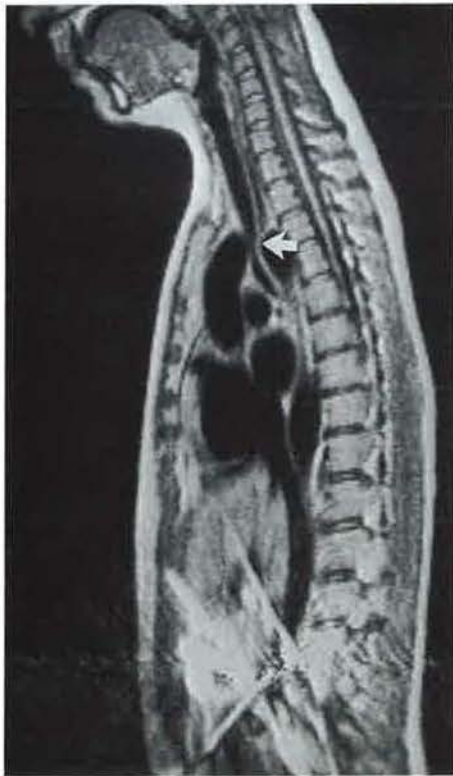
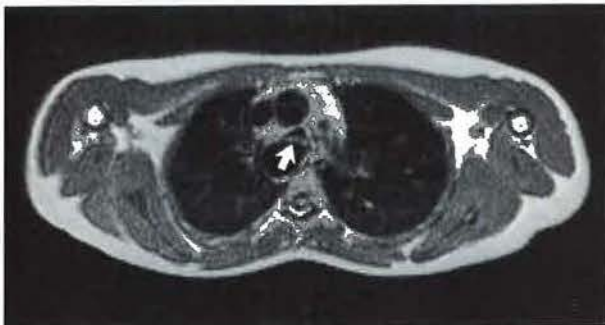
Fig. 4. - Magnetic resonance images: (upper panel) axial plane; and (lower panel) sagittal plane. Note that the trachea (arrow) is compressed between the ascending and descending aorta.

### Magnetic resonance imaging (MRI)

MRI demonstrated a right-sided aortic arch with tracheal compression (fig. 4). The left subclavian artery had its origin in the dorsal part of the aortic arch and passed behind the oesophagus, causing it to be displaced anteriorly.

### Bronchoscopy

Bronchoscopy showed compression of the distal part of the trachea 5 cm above the carina. The lumen was approximately half of its normal diameter.

### DIAGNOSIS: Right-sided aorta with remnants of the left arch compressing the trachea

### Treatment

These findings were confirmed at left-sided thoracotomy. The atretic left aortic arch overriding the left main bronchus and carina was resected, with resultant relief of the airway obstruction. There were no macroscopic signs of tracheomalacia.

The patient's condition has improved considerably since the operation. She no longer snores and experiences greater physical fitness. During the first night at home the patient's parents felt that they had to constantly check her, as they could no longer hear the familiar snoring sounds.

### Discussion

A right-sided aortic arch is quite rare and when it does occur it is most often of no clinical significance. However, this malformation is sometimes accompanied by a left-sided aorta ("double arch") or remnants thereof, which can cause compression of the oesophagus and trachea [1, 2]. This is usually diagnosed and surgically treated very early in life. However, as seen from this case, the diagnosis is sometimes missed. In patients with asthma who claim that they get no relief from asthma medication, a thorough search for an alternative diagnosis should be made. Concurrent swallowing difficulties indicate a malformation of central vessels.

The finding of a right-sided aortic arch should prompt further investigation of the central vessels. The first step (after chest radiography) should be a barium swallow to examine the oesophagus. Should this examination confirm an abnormality, the next measure is usually angiography of the thoracic aorta [3] (with oesophagus indicated) or a CT scan of the thorax with intravenous contrast enhancement. As demonstrated by the present case, MRI of the thorax can be performed instead. This examination has clear advantages: it is completely noninvasive (and may thus be performed on an out-patient basis), no ionizing radiation is used, and any projection may be employed,

so as to achieve optimal visualization of the abnormality [4].

#### References

1. Stewart JR, Kincaid OW, Edwards JE. - An Atlas of Vascular Rings and related Malformations of the Aortic Arch System. Springfield, Ill., Charles C. Thomas, 1964.
2. Lincoln JCR, Deverall PB, Stark J, Aberdeen E, Waterson DJ. - Vascular anomalies compressing the esophagus and trachea. *Thorax*, 1969; 24: 295-306.
3. Freedom RM, Culham JAG, Moes CAF. - Angiocardiography of congenital heart disease. Macmillan Publishing Co. 1984; p, 508.
4. Kersting-Sommerhoff BA, Sechtem UP, Fisher MR, Higgins CB. - MR imaging of congenital anomalies of the aortic arch. *AJR*, 1987; 149: 9-13.