

Spontaneous pneumothorax following regression of pulmonary metastases

N. Kryger-Baggesen

Spontaneous pneumothorax following regression of pulmonary metastases. N. Kryger-Baggesen.

ABSTRACT: Spontaneous pneumothorax (SP) caused by necrosis in combination with regression of lung metastases is a rare complication to cancer chemotherapy. Few case reports have previously been presented, and mostly in patients with sarcomas. A patient is presented with spontaneous pneumothorax probably caused by chemotherapy-induced cell necrosis in bilateral lung metastases secondary to an endometrioid cancer. The literature is surveyed. Because of the increasing use of effective chemotherapeutic drugs, it is expected that this rare complication will occur more often.

Eur Respir J., 1990, 3, 485-486.

Dept of Oncology, Finsen Institute, Copenhagen University Hospital, Denmark.

Correspondence: N. Kryger-Baggesen, Dept of Oncology ONK 5074, Copenhagen University Hospital, 9, Blegdamsvej, DK-2100 Copenhagen 0, Denmark.

Keywords: Chemotherapy; endometrioid cancer; pneumothorax.

Received: November 30, 1989; accepted after revision December 11, 1989.

Case report

A 75 yr old, previously healthy, nonsmoking woman without premorbid lung disease underwent hysterectomy and bilateral salpingo-oophorectomy for a uterine cancer in November, 1987. Histological examination showed endometrioid cancer of mixed mesodermal type, invading <50% of the myometrium, with invasion of the tumour in the cervical part of the uterus. Postoperatively, the patient was seen regularly without further treatment.

Local recurrence was confirmed histologically in February, 1988, and the patient was referred to the Finsen Institute for further treatment. External irradiation (50 Gy) combined with internal vaginal caesium (30 Gy) was given in April, 1988.

Three months later, X-ray of the thorax showed multiple bilateral lung metastases (fig. 1). Examination of the pelvis showed no signs of local recurrence.

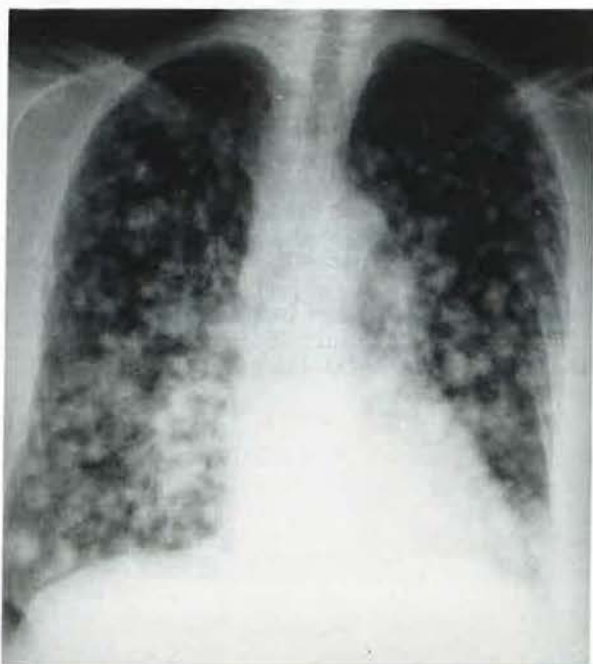


Fig. 1. - Bilateral lung metastases in a 75 yr old woman with endometrioid cancer.

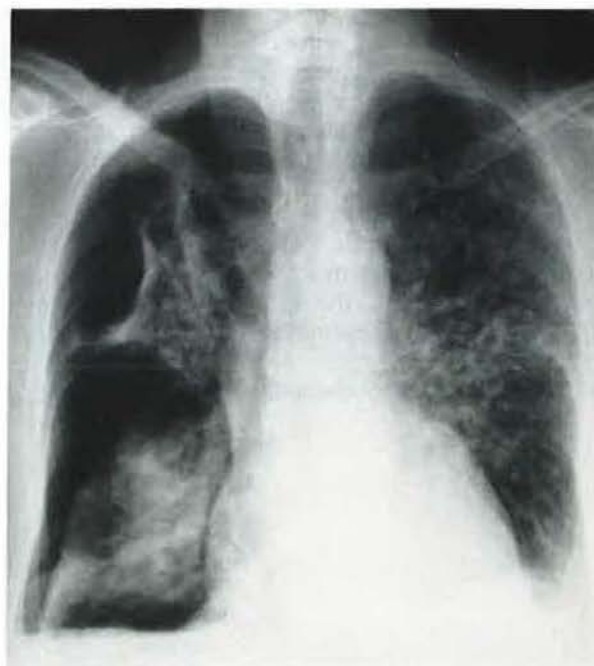

Fig. 2. - Obvious regression of the left-sided lung metastases combined with a right-sided pneumothorax following two courses of chemotherapy.

Subsequently, the patient was given doxorubicin 60 mg·m⁻² i.v., on day 1 and 8 in a series of 28 days. Because of toxicity the dosage of the second treatment was reduced to 66%. Before the third treatment, X-ray of the thorax showed a right-sided pneumothorax and considerable regression of the measurable left-sided metastases (fig. 2).

Following treatment of the pneumothorax with drainage, the general condition of the patient improved and chemotherapy was resumed until February, 1989. Progression of lung metastases occurred at this time and chemotherapy was discontinued.

Discussion

A patient, with multiple bilateral lung metastases secondary to an endometrioid cancer of mesodermal mixed type treated with chemotherapy, is described. After two treatments regression of the lung metastases was observed but, in addition, a unilateral pneumothorax was demonstrated, presumably secondary to the pronounced regression of the tumour with necrosis.

Spontaneous pneumothorax occurs mostly among younger men in the second to the fourth decade [1]. Certain lung diseases, especially chronic obstructive diseases, predispose to this condition [2]. Lung metastases, especially secondary to sarcomas, may cause spontaneous pneumothorax. Among 1,143 patients with SP, DINES *et al.* [3] found ten with lung metastases, of whom six had sarcomas. In 1963, JANETOS and OCHSNER [4] reported 43 cases of SP among patients with sarcomas, whilst SMEVIK and KLEPP [5] reported seven cases of SP among 63 patients with sarcomas. Of 35 patients treated with chemotherapy, five patients developed SP. Three cases of SP have been reported among patients with leiomyosarcomas, of whom two were treated with chemotherapy [6–8], whilst there has been one report of bilateral SP following chemotherapy in a patient with adenocarcinoma of the uterus [6]. Finally, three cases of SP following chemotherapy treatment of germinative tumours have been reported [9, 10].

Necrosis in the tumour is probably capable of causing a bronchopleural fistula and a pneumothorax. This is confirmed by the fact that SP was reported in patients with sarcomas prior to the wide use of chemotherapy [4, 8]. This predisposing factor is probably enhanced by the excessive cell necrosis induced by chemotherapy. In spite of this, SP caused by chemotherapy-induced regression

of lung metastases is a rare complication. Because of the increasing use of effective chemotherapeutic drugs, it can be expected that this condition will occur more often. It is, therefore, of importance to have this complication in mind in this type of patient.

References

1. Bertelsen S. – Thoraxvaeg, pleura, diaphragma. In: Kirurgisk kompendium. T. Hald and F. Stadil eds, Nyt nordisk Forlag, Arnold Busk A/S, Kobenhavn, 1987, pp. 627–658 (in Danish).
2. Green RA. – Pneumothorax. In: Textbook of Pulmonary Diseases. G.L. Baum ed., Little, Brown and Company, Boston, Massachusetts, 1965, pp. 688–698.
3. Dines DE, Cortese DA, Brennan MD, Hann RG, Payne WS. – Malignant pulmonary neoplasms predisposing to spontaneous pneumothorax. *Mayo Clin Proc*, 1973, 48, 541–544.
4. Janetos GP, Ochsner SF. – Bilateral pneumothorax in metastatic osteogenic sarcoma. *Am Rev Respir Dis*, 1963, 88, 73–76.
5. Smevik B, Klepp O. – The risk of spontaneous pneumothorax in patients with osteogenic sarcoma and testicular cancer. *Cancer*, 1982, 49(8), 1734–1737.
6. Helmkamp BF, Beecham JB, Wandtke JC, Keys H. – Spontaneous pneumothorax in gynecologic malignancies. *Am J Obstet Gynecol*, 1982, 6(1), 706–707.
7. Rammohan G, Bonacini M, Dwek JH, Das A. – Pleurodesis in metastatic pneumothorax. *Chest*, 1986, 90(6), 918–919.
8. Shaw AB. – Spontaneous pneumothorax from secondary sarcoma of the lung. *Br Med J*, 1951, 1, 278–280.
9. Shulman P, Cheng E, Cvitkovic E, Golbey R. – Spontaneous pneumothorax as a result of intensive cytotoxic chemotherapy. *Chest*, 1979, 75(2), 194–196.
10. Lote K, Dahl O, Vigander T. – Pneumothorax during combination chemotherapy. *Cancer*, 1981, 47(7), 1743–1745.

Pneumothorax spontané après régression de métastases pulmonaires. N. Kryger-Baggesen.

RÉSUMÉ: Présentation d'un patient dont le pneumothorax spontané a été probablement causé par une nécrose cellulaire induite par la chimiothérapie au niveau de métastases pulmonaires bilatérales secondaires à un cancer endométrial. Revue de la littérature. On peut s'attendre à ce que cette complication rare devienne plus fréquente, en raison de l'utilisation accrue de chimiothérapies efficaces. *Eur Respir J.*, 1990, 3, 485–486.