



Early View

Research letter

FEV₁ and MRI Ventilation Defect Reversibility in Asthma and COPD

Hana Serajeddini, Rachel L. Eddy, Christopher Licskai, David G. McCormack, Grace Parraga

Please cite this article as: Serajeddini H, Eddy RL, Licskai C, *et al.* FEV₁ and MRI Ventilation Defect Reversibility in Asthma and COPD. *Eur Respir J* 2019; in press (<https://doi.org/10.1183/13993003.01947-2019>).

This manuscript has recently been accepted for publication in the *European Respiratory Journal*. It is published here in its accepted form prior to copyediting and typesetting by our production team. After these production processes are complete and the authors have approved the resulting proofs, the article will move to the latest issue of the ERJ online.

Copyright ©ERS 2019

FEV₁ and MRI Ventilation Defect Reversibility in Asthma and COPD

*Hana Serajeddini MD^{1,2}, *Rachel L Eddy BEng^{1,3} Christopher Liciskai MD², David G McCormack MD² and Grace Parraga PhD¹⁻³

¹Robarts Research Institute, ²Division of Respiriology, Department of Medicine, ³Department of Medical Biophysics, Western University, London CANADA

*contributed equally as first authors

Correspondence to:

G. Parraga PhD
Robarts Research Institute
1151 Richmond St N
London, Canada
N6A 5B7
Telephone: (519) 931-5265
Email: gparraga@robarts.ca

Running Title: MRI ventilation defect reversibility in asthma and COPD

Key Words: Asthma, COPD, magnetic resonance imaging, ventilation heterogeneity, reversibility

Take Home Message

MRI ventilation defect post-bronchodilator reversibility was not always concordant with FEV₁ reversibility in asthma and COPD. MRI VDP may provide enhanced sensitivity to small airway response to inhaled medication.

To the Editor

The underlying pathophysiological determinants of asthma and chronic obstructive pulmonary disease (COPD) are related in complex ways. Importantly however, post-bronchodilator FEV₁-reversibility may occur in approximately 50% of COPD patients [1] whilst epidemiological [2] and magnetic-resonance-imaging (MRI) studies [3] suggest that in asthmatics, FEV₁-reversibility may diminish over time. As compared to patients with asthma or COPD alone, patients with co-existing asthma and COPD report worse clinical outcomes [4] and increased healthcare costs [5] and burden [4, 5].

Hyperpolarised ³He and ¹²⁹Xe MRI studies have reported clinically relevant post-bronchodilator improvements in MRI ventilation defects in patients with asthma [6] and COPD [7], independent of FEV₁ reversibility. However, post-bronchodilator FEV₁ and MRI reversibility have not been rigorously explored together across a wide range of patients with obstructive lung disease. Although their etiology has not been ascertained, MRI ventilation defects are thought to be related to airway occlusion or remodeling throughout the airway tree while FEV₁ is dominated by the larger airways.

To better understand bronchodilator reversibility in patients with a diagnosis of asthma or COPD, we retrospectively evaluated spirometry and hyperpolarised ³He MRI measurements in participants with asthma (age ≥40-years, <1 pack-year smoking-history) and COPD (age 60-85-years, >10 pack-years smoking-history). We expected that MRI would detect post-bronchodilator reversibility in participants in whom there was negligible post-bronchodilator FEV₁-reversibility, thereby providing a small and large-airway quantitative functional

measurement with enhanced sensitivity to small airways disease and greater dynamic range than FEV₁.

We retrospectively evaluated 58 participants including 45 participants with asthma (20 male/25 female never-smokers, 54±8-years) and 13 with COPD (7 male/6 female ex-smokers, 70±6-years, 45±17-pack-years) who underwent a single two-hour visit consisting of spirometry and MRI before and after inhalation of salbutamol (4x100µg Teva Novopharm Ltd., Toronto, Canada) using a pressurised metered-dose inhaler and *AeroChamberPlus* spacer (Trudell Medical International, London, Canada). Spirometry was performed (MedGraphics, St. Paul, USA) and post-bronchodilator reversibility assessed according to guidelines [8]. Participants withheld short-acting β-agonists for 6-hours and long-acting β-agonists for 12-hours before their visit. Anatomical proton and hyperpolarised ³He ventilation MRI were acquired after inhalation from functional residual capacity as previously described [9]. We used the minimal clinically-important-difference (MCID) of 110mL/2% [9] as the threshold for a clinically relevant post-bronchodilator change in MRI ventilation-defect-percent (VDP) [9].

In asthma, 51% (23/45) of participants were FEV₁-reversible, whereas 15% (2/13) of COPD participants were FEV₁-reversible. Shown in Figure 1 (bottom panel), COPD and asthma participants were further classified into eight subgroups based on FEV₁ and VDP post-bronchodilator reversibility where cyan represents both FEV₁ and VDP reversibility, purple represents either FEV₁ or VDP reversibility and rose reflects neither FEV₁, nor VDP reversibility. Twenty-seven percent (12/45) of asthmatics and 15% (2/13) of COPD participants exhibited both FEV₁ and VDP reversibility (cyan). As shown in rose, in 33% (15/45) of

participants with asthma and 62% of participants with COPD (8/13, ~double the proportion of asthmatics) there was neither FEV₁ nor VDP-reversibility. Shown in purple, 24% (11/45) of asthmatics and no COPD participants demonstrated FEV₁ reversibility in the absence of VDP reversibility whilst 16% (7/45) of asthmatics and 23% (3/13) of COPD participants demonstrated VDP reversibility in the absence of FEV₁ reversibility. Overall, VDP was greater in participants with COPD compared with asthma (pre-bronchodilator 24±9% vs 10±8%, p<0.0001), although a similar proportion of participants with COPD and asthma exhibited VDP reversibility (5/13 or 38% COPD; 19/45 or 42% asthma). Figure 1 also shows participant demographics and pre- and post-bronchodilator hyperpolarised ³He static ventilation MRI, for representative participants with both FEV₁ and VDP reversibility, and with VDP reversibility alone. There was visually and quantitatively improved ventilation post-bronchodilator even in participants who did not report FEV₁ improvements.

We observed a mixture of concordant and discordant FEV₁ and MRI VDP reversibility in asthmatic and COPD participants and were not surprised that nearly double the proportion of participants with asthma reported concordant FEV₁ and VDP reversibility (27% versus 15% in COPD). We were surprised that nearly the same proportion of asthmatics reported neither FEV₁ nor VDP reversibility (33%) which was about half the proportion of COPD (62%) reporting the same. FEV₁ reversibility in asthma may diminish over time, independent of smoking [2], and therefore asthmatics may develop fixed obstruction in a mechanistically different way as compared to COPD patients with post-bronchodilator reversibility [10, 11]. VDP was previously shown to be an independent predictor of future bronchodilator reversibility in asthmatics [3] and may help identify asthma patients at risk for fixed obstruction over time.

We also observed post-bronchodilator FEV₁ and MRI ventilation improvements in a small number of COPD patients, consistent with previous findings [7]. It is important to note that the COPD participants studied here had no previous history of asthma, and may not meet current asthma-COPD overlap definitions [10, 11]. VDP is temporally persistent and reproducible in COPD [12], so it is possible that corresponding FEV₁ and MRI VDP post-bronchodilator improvements identify new phenotypes. Future studies in COPD patients with modest FEV₁ and VDP reversibility may show that these patients share similarities with asthma and might benefit from asthma-targeted therapies.

Perhaps most enlightening was the observation in seven asthmatics and three COPD participants who reported reversible VDP in the absence of FEV₁ reversibility. This finding lends credence to the growing understanding that FEV₁ and VDP are measuring different but complementary pathologies. Given that VDP is more sensitive to small airways disease than FEV₁ and VDP predicts future bronchodilator reversibility [3], the lack of VDP reversibility demonstrated in 16% of the asthma participants studied here may be an early indicator of progression to fixed obstruction [2], that may stem from suboptimal treatment, inflammation, mucus plugging or terminal airway obliteration. We note that two of these seven participants exhibited a post-bronchodilator FEV₁ improvement >+200 mL but did not meet the 12% threshold (230mL/9%, 260mL/11%) to satisfy ATS/ERS criteria [8]. The remainder reported post-bronchodilator changes in FEV₁ of -70mL/-4%, 160mL/6%, -50mL/-5%, 130mL/6% and 140mL/10%; some of these post-bronchodilator changes are within the measurement error of FEV₁ [8]. Whilst 11 asthmatics reported FEV₁ reversibility with no VDP reversibility, all FEV₁-reversible COPD

participants also reported VDP-reversibility. Different VDP and FEV₁ responses in COPD and asthma may be due to differences in large central airway obstruction and small airways disease that is not detected using spirometry. Previous work showed that MRI in combination with oscillometry revealed that VDP was related to total respiratory system and small airways resistance before bronchodilator inhalation in asthma but was related only to small airways resistance post-bronchodilator in asthma and COPD [13]. This supports the notion that bronchodilator acts on the large airways in asthma, which could explain why so many participants with asthma but none with COPD showed FEV₁ reversibility with no VDP response. These findings challenge us to reflect on the pathophysiological processes related to the distal or peripheral airways which appear to dominate in COPD, but not asthma.

Our current understanding is that there are different asthma and COPD phenotypes with distinctive pathophysiologies, including different contributions of the small and large airways [1]. It was not unexpected that FEV₁ and VDP reversibility were not always in agreement, especially because VDP reflects both the small and large airways [14] and FEV₁ measurements are dominated by the large airways [15]. Importantly, VDP was not reversible in the majority of participants (34/58 total). This is important to consider in small airways-disease-predominant phenotypes, in whom reversibility may not be detected using spirometry, and this may be considered for inhaled therapy response in general for patients with asthma and COPD. If inhaled medications are unable to reach the small airways, this could explain why only a subset of patients experience improvements in symptoms or exacerbation frequency. VDP may provide a new way to quantify small and large-airway function with enhanced sensitivity to small airways disease and greater dynamic range than FEV₁. Our results suggest the possibility for MRI VDP

to provide added value for assessing response to inhaled treatments, and perhaps demonstrate different responses for inhalers specifically targeted at the small airways. VDP responses likely depend on patient phenotype and the type of inhaled medication, and this opens the door for future investigations to predict which patients will exhibit a VDP response to which inhaled medication, in an effort to deliver personalised treatment.

We acknowledge that post-bronchodilator response remains controversial in patients with asthma and COPD [11], and this limits the generalisability of our findings. Whilst age and smoking-history were clearly different between groups, other parameters considered as key asthma and COPD features [10, 11] including airway inflammation, age of disease-onset and/or disease duration will be important to consider in future studies.

Post-bronchodilator MRI ventilation defect and FEV₁ responses are not always concordant in participants with asthma and COPD, suggesting that VDP may provide a more sensitive tool to measure response to treatment in the small airways and identify the need for a change in treatment.

Acknowledgements: Dr. Parraga gratefully acknowledges funding from the Canada Research Chair program, the Canadian Institutes of Health Research and the Natural Sciences and Engineering Research Council (NSERC Canada). Rachel Eddy acknowledges NSERC Canada CGS-Masters and PGS-Doctoral Scholarships.

REFERENCES

1. Postma DS, Rabe KF. The Asthma-COPD Overlap Syndrome. *N Engl J Med* 2015; 373(13): 1241-1249.
2. To T, Zhu J, Larsen K, Simatovic J, Feldman L, Ryckman K, Gershon A, Loughheed MD, Licskai C, Chen H, Villeneuve PJ, Crighton E, Su Y, Sadatsafavi M, Williams D, Carlsten C. Progression from Asthma to Chronic Obstructive Pulmonary Disease. Is Air Pollution a Risk Factor? *Am J Respir Crit Care Med* 2016; 194(4): 429-438.
3. Eddy RL, Svenningsen S, Licskai C, McCormack DG, Parraga G. Hyperpolarized Helium 3 MRI in Mild-to-Moderate Asthma: Prediction of Postbronchodilator Reversibility. *Radiology* 2019; 293(1): 212-220.
4. Kendzerska T, To TM, Aaron SD, Loughheed MD, Sadatsafavi M, FitzGerald JM, Gershon AS. The impact of a history of asthma on long-term outcomes of people with newly diagnosed chronic obstructive pulmonary disease: A population study. *J Allergy Clin Immunol* 2017; 139(3): 835-843.
5. Sadatsafavi M, Tavakoli H, Kendzerska T, Gershon A, To T, Aaron SD, FitzGerald JM, Canadian Respiratory Research N. History of Asthma in Patients with Chronic Obstructive Pulmonary Disease. A Comparative Study of Economic Burden. *Ann Am Thorac Soc* 2016; 13(2): 188-196.
6. Svenningsen S, Kirby M, Starr D, Leary D, Wheatley A, Maksym GN, McCormack DG, Parraga G. Hyperpolarized (3) He and (129) Xe MRI: differences in asthma before bronchodilation. *J Magn Reson Imaging* 2013; 38(6): 1521-1530.
7. Kirby M, Mathew L, Heydarian M, Etemad-Rezai R, McCormack DG, Parraga G. Chronic obstructive pulmonary disease: quantification of bronchodilator effects by using hyperpolarized (3)He MR imaging. *Radiology* 2011; 261(1): 283-292.
8. Pellegrino R, Viegi G, Brusasco V, Crapo RO, Burgos F, Casaburi R, Coates A, van der Grinten CP, Gustafsson P, Hankinson J, Jensen R, Johnson DC, MacIntyre N, McKay R, Miller MR, Navajas D, Pedersen OF, Wanger J. Interpretative strategies for lung function tests. *Eur Respir J* 2005; 26(5): 948-968.
9. Eddy RL, Svenningsen S, McCormack DG, Parraga G. What is the minimal clinically important difference for helium-3 magnetic resonance imaging ventilation defects? *Eur Respir J* 2018; 51(6).
10. Global Initiative for Obstructive Lung Disease (GOLD) and Global Initiative for Asthma (GINA). Diagnosis of Diseases of Chronic Airflow Limitation: Asthma, COPD and Asthma-COPD Overlap Syndrome (ACOS); 2015.
11. Sin DD, Miravittles M, Mannino DM, Soriano JB, Price D, Celli BR, Leung JM, Nakano Y, Park HY, Wark PA, Wechsler ME. What is asthma-COPD overlap syndrome? Towards a consensus definition from a round table discussion. *Eur Respir J* 2016; 48(3): 664-673.
12. Mathew L, Evans A, Ouriadov A, Etemad-Rezai R, Fogel R, Santyr G, McCormack DG, Parraga G. Hyperpolarized 3He magnetic resonance imaging of chronic obstructive pulmonary disease: reproducibility at 3.0 tesla. *Acad Radiol* 2008; 15(10): 1298-1311.
13. Eddy RL, Westcott A, Maksym GN, Parraga G, Dandurand RJ. Oscillometry and pulmonary magnetic resonance imaging in asthma and COPD. *Physiol Rep* 2019; 7(1): e13955.
14. Teague WG, Tustison NJ, Altes TA. Ventilation heterogeneity in asthma. *J Asthma* 2014; 51(7): 677-684.

15. Macklem PT, Mead J. Resistance of central and peripheral airways measured by a retrograde catheter. *J Appl Physiol* 1967; 22(3): 395-401.

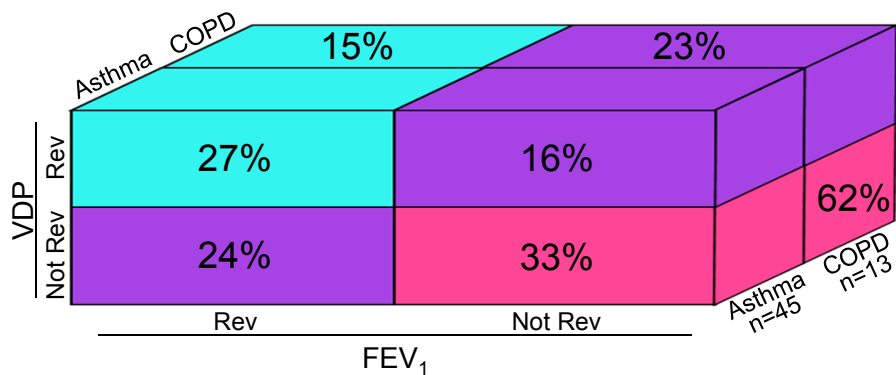
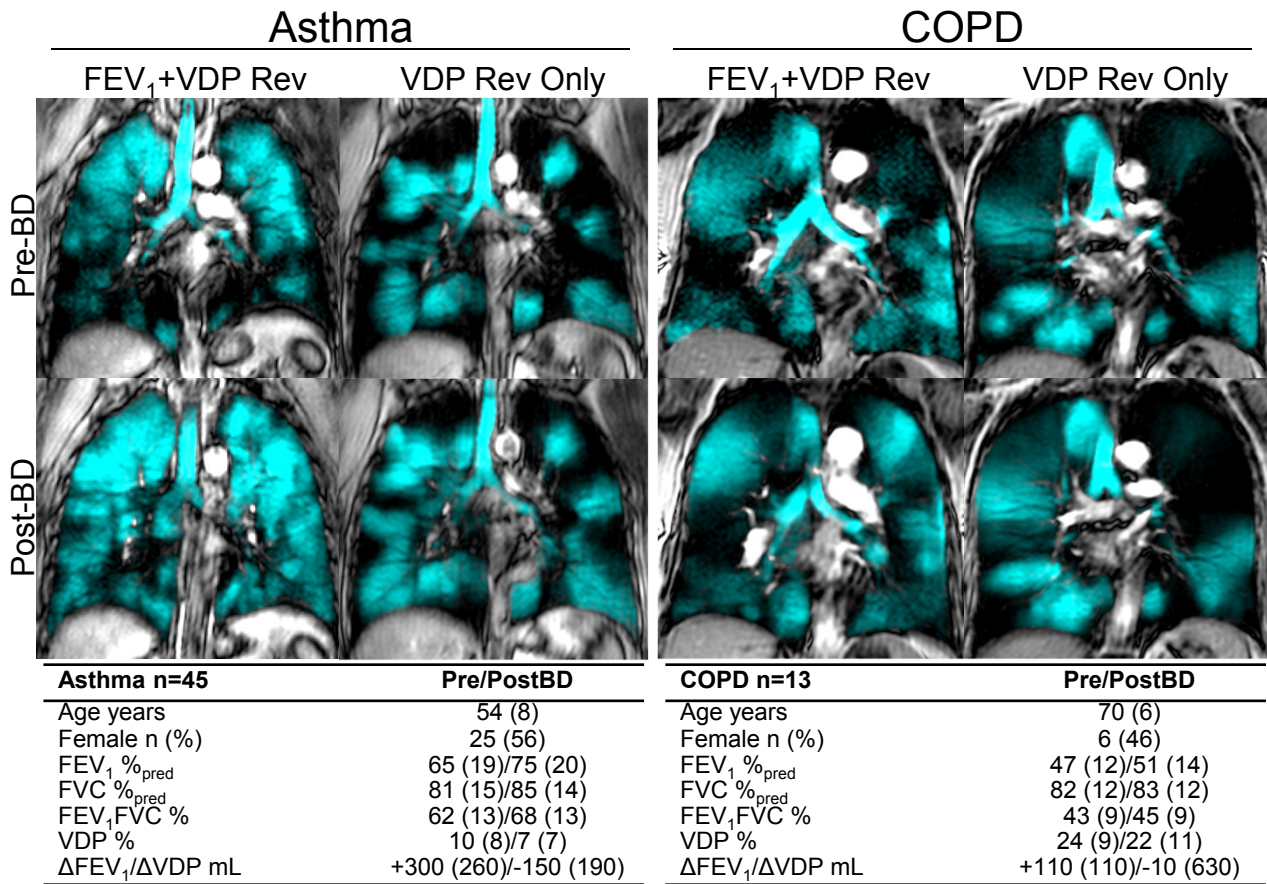


Figure 1. FEV₁ and MRI VDP Reversibility in Participants with Asthma and COPD. Centre slice hyperpolarised ³He MRI static ventilation (cyan) co-registered to anatomical proton (gray-scale) pre- and post-bronchodilator for representative participants with both FEV₁ and MRI ventilation defect percent (VDP) reversibility, and with VDP reversibility alone. Tables show demographics for asthma and COPD participants. Cubic illustration shows eight subgroups with proportions of participants in each based on FEV₁ and MRI VDP reversibility, where cyan represents both FEV₁ and VDP reversibility, purple represents either FEV₁ or VDP reversibility, and rose represents neither FEV₁ nor VDP reversibility.