

CASE STUDY

Association between Wegener's granulomatosis and *Staphylococcus aureus* infection?

J.W.G. van Putten, E.H.J. van Haren, J-W.J. Lammers

Association between Wegener's granulomatosis and Staphylococcus aureus infection?
J.W.G. van Putten, E.H.J. van Haren, J-W.J. Lammers. ©ERS Journals 1996.

ABSTRACT: Two patients are presented with Wegener's granulomatosis (WG) and lower respiratory tract infections with *Staphylococcus aureus* (SA). It is posulated that there is a relationship between the infection and the induction or relapse of the disease.

We suggest that bronchoalveolar lavages should be performed in cases of suspected WG to identify SA-infections. The co-existence of WG and SA support the reported beneficial effects of sulfamethoxazole/trimethoprim, but needs further evaluation in patients with and without SA-infection of the airways.

Eur Respir J., 1996, 9, 1955–1957.

University Hospital, Dept of Pulmonary Medicine, Utrecht, The Netherlands.

Correspondence: J.W.G. van Putten, Academisch Ziekenhuis Utrecht, Dept of Pulmonary Medicine, Heidelberglaan 100, 3584 CX Utrecht, The Netherlands

Keywords: *Staphylococcus aureus*
Wegener's granulomatosis

Received: September 1 1995

Accepted after revision January 31 1996

Wegener's granulomatosis (WG) is a systemic vasculitis with necrotic, granulomatous lesions. It predominantly involves the upper and lower respiratory tracts. All other organs can also be involved, especially the kidneys. Treatment with cyclophosphamide in combination with corticosteroids is highly effective, but may cause serious side-effects [1]. This has prompted the search for a less toxic treatment regimen in limited disease. Several reports have noted good results following treatment with trimethoprim/sulphamethoxazole [2–5]. This has given rise to a suspicion of the possible involvement of an infectious agent in the pathogenesis of WG.

In 1936, WEGENER [6] suggested that the disease was triggered by an infection of the upper respiratory tract and that all other signs were due to an allergic reaction to the infection. Many patients had a respiratory tract infection at the onset of the disease or before the occurrence of a relapse [7]. It was also noted that a respiratory tract infection could precede an increase in the level of antineutrophil cytoplasmic antibodies (c-ANCA) titre [8]. The level of c-ANCA is a specific and rather sensitive marker for disease-activity [9, 10], although c-ANCA levels do not always parallel the clinical course. In other studies, *Staphylococcus aureus* was found to be the most common cause of recurrent, purulent rhinitis in patients with WG [1, 11]. It has also been reported that patients with WG and chronic nasal carriage of *S. aureus* were more prone to relapses of the disease of the upper as well as the lower respiratory tract [12]. This suggests a possible role for upper respiratory tract infections with *S. aureus* in the pathophysiology of WG.

Although it is feasible that lower respiratory tract infections with *S. aureus* are also important in WG, this has not been described previously. We present the cases of two patients with WG and a lower respiratory tract infection with *S. aureus*.

Case report

Patient 1

In November 1994, a 63 year old female patient was admitted to our hospital. A mononeuritis multiplex was diagnosed. In the previous months she had had recurrent otitis, which necessitated a mastoidectomy. Physical examination was unremarkable except for bilateral nasal crusting. Laboratory investigation revealed a sedimentation rate of 69 mm·h⁻¹. A chest roentgenogram demonstrated peripheral pulmonary infiltrates (fig. 1). WG was diagnosed with a c-ANCA titre 1:640 and a positive anti-proteinase-3. Antimyeloperoxidase and antielastase were negative. No renal involvement was found. Treatment with 60 mg·day⁻¹ prednisolone and 150 mg·day⁻¹ cyclophosphamide was initiated.

In the following week, the patient complained of progressive cough and dyspnoea. The pulmonary infiltrates were rapidly increasing and were causing a total shadowing of the right lung. Bronchoscopy showed a red, oedematous nodular mucosa with irregular ulcerations and haemorrhages. Bronchoalveolar lavage (BAL) was performed in the right lung. Immunosuppressive therapy was continued and trimethoprim/sulphamethoxazole 960 mg twice daily was added. Cultures of the BAL showed growth of >100 colony-forming units (CFU)·mL⁻¹ *S. aureus*, which is normally sensitive to trimethoprim/sulphamethoxazole. *S. aureus* was also cultured from the nose. Following initiation of trimethoprim/sulphamethoxazole the pulmonary infiltrates disappeared within 10 days. The level of c-ANCA gradually declined to 1:40 after 6 months of treatment, during which the prednisolone dosage was reduced from 60 to 20 mg·day⁻¹ whilst the dosage of cyclophosphamide was kept constant (150 mg·day⁻¹). A culture of the nose after several months showed no chronic carriage of *S. aureus*.

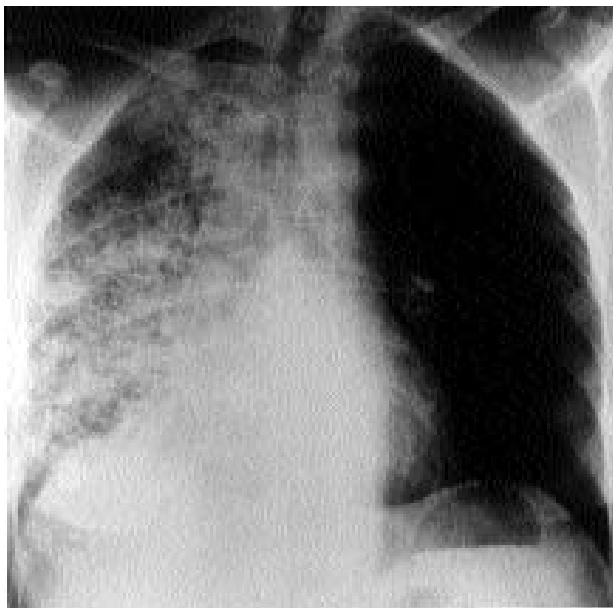


Fig. 1. – Patient 1. Diffuse infiltrates in the right lung caused by Wegener's granulomatosis and infection with *Staphylococcus aureus*.

Patient 2

A 53 year old female patient had had a limited form of WG since 1991. She had signs and symptoms of upper and lower respiratory tract involvement, but no renal involvement was found. The c-ANCA titre was elevated to 1:64, and antiproteinase-3 was weakly positive. Anti-myeloperoxidase and antielastase were negative. Despite treatment with 60 mg·day⁻¹ of prednisolone the patient developed progressive pulmonary lesions. Hence, cyclophosphamide, 150 mg daily, and trimethoprim/sulphamethoxazole, 960 mg twice daily, were added. The c-ANCA titre became negative and the pulmonary nodules resolved.

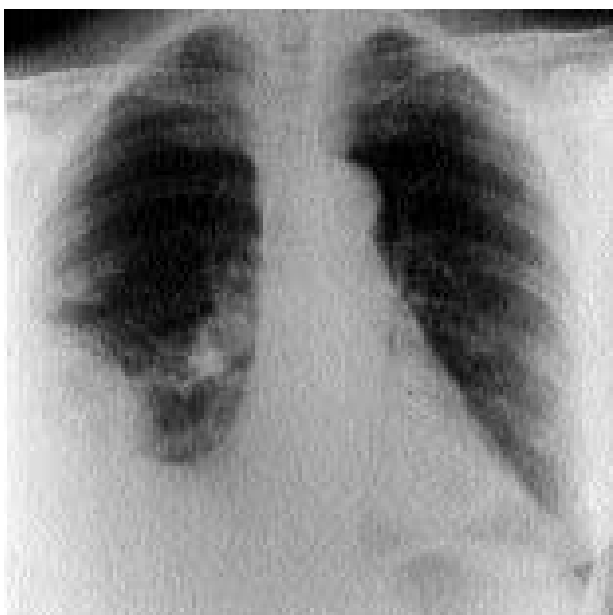

Fig. 2. – Patient 2. Infiltrates in the right upper and lower lobe caused by *Staphylococcus aureus*. Central infiltrate near the right hilus caused by Wegener's granulomatosis.

Because of an exanthema the trimethoprim/sulphamethoxazole was replaced by trimethoprim, 200 mg twice daily, alone and cyclophosphamide was continued at a low dose, 50 mg·day⁻¹. In 1993, a reactivation occurred which was successfully treated with 40 mg·day⁻¹ prednisolone and 150 mg·day⁻¹ cyclophosphamide.

In September 1994, the patient presented with a proptosis of her left eye and more bloody crusts in her nose. On this occasion, she was treated with 25 mg cyclophosphamide daily. A computed tomography scan showed a mass in the ethmoid sinuses with destruction of the bone structures and formation of a pseudotumour in the orbita. An ethmoidectomy was performed and histological examination of the tissue showed chronic inflammation without specific signs of WG. There was also a new pulmonary infiltrate around the right hilar region. The c-ANCA titre had risen to 1:20, and C-reactive protein (CRP) from 4 to 13 mg·L⁻¹. A reactivation of the WG was suspected and the patient was treated with prednisolone, 40 mg·day⁻¹, and cyclophosphamide, 50 mg·day⁻¹. With this treatment regimen, c-ANCA titre became negative after 6 weeks, but the nasal complaints persisted.

Four weeks later, the patient was readmitted to hospital with dyspnoea and high fever. The chest radiograph showed new infiltrates in the right upper and lower lobe (fig. 2). She was treated with ceftriaxone. The sputum culture yielded growth of >100 CFU·mL⁻¹ of *S. aureus*. Antibiotic therapy was changed to flucloxacillin intravenously and was continued for 4 weeks. *S. aureus* was also cultured from the nose. In this period, the patient developed a hyperglycaemic coma due to a newly diagnosed insulin-dependent diabetes mellitus, and a venous thrombosis of the left leg.

The pneumonia resolved with formation of a pneumatocele, which in the following months gradually resolved. The patient later developed a secondary infection of the pneumatocele caused by *Pseudomonas aeruginosa* and again *S. aureus*, which was treated with ceftazidime, tobramycin and flucloxacillin. She still carries *S. aureus* in her nose. Meanwhile, she has developed severe generalized airway obstruction.

Discussion

The cases of two patients with WG and *Staphylococcus aureus* in the lower respiratory tract are reported, an association which has not been described previously. In a study comprising 13 patients with WG, cultures of the bronchoalveolar lavage did not show any growth of bacteria, fungi or respiratory viruses. However, only three patients had active pulmonary disease at the moment of the bronchoalveolar lavage. Moreover, the lavage fluid of all five patients with active WG was characterized by a marked increase in polymorphonuclear neutrophils, suggesting bacterial infection despite negative cultures [13].

S. aureus colonizes the upper airways in about 20% of healthy persons. Most patients with serious sinus or nasal disease due to WG develop secondary infections, in which *S. aureus* is predominantly involved [1–11].

In our patients - one new case and one relapse of WG - the WG was associated with the presence of *S. aureus* in the upper and lower respiratory tract. Activation of

WG might be precipitated by infection with *S. aureus*, which initiates a cascade of immunological events caused by several *S. aureus* toxins. This hypothesis is supported by the observation that chronic nasal carriage of *S. aureus* is related to exacerbations of WG [12]. *S. aureus* products, like many other microbial products, can induce interleukin-8 (IL-8) expression. IL-8 is known to play a significant role in neutrophil recruitment in the airways. Auto-antibodies may also be formed during the inflammatory process. Antigens present in purulent sputum react strongly with immunoglobulin G (IgG) isolated from sera in patients with WG [14]. This indicates a possible mechanism by which respiratory infection with *S. aureus* might precipitate relapses of WG. Whether *S. aureus* could be the unknown agent inducing auto-antibodies in WG remains speculative.

Another explanation for the association that has been observed could be that the damaged tissue impairs mucosal immunity, favouring secondary infection with *S. aureus*. In this case, however, other pathogens would also be expected to be present.

To elucidate the pathogenesis of Wegener's granulomatosis, further bronchoalveolar lavages should be performed in patients with active pulmonary disease, making a distinction between patients having *S. aureus* infection or not. The effects of administering trimethoprim/sulphamethoxazole have to be evaluated in patients with and without *S. aureus* infection. The possible association of Wegener's granulomatosis and *S. aureus* infection supports the reported beneficial effects of including trimethoprim/sulphamethoxazole in the treatment of Wegener's granulomatosis.

References

1. Fauci AS, Haynes BF, Katz P, Wolff SM. Wegener's granulomatosis: prospective clinical and therapeutic experience with 85 patients for 21 years. *Ann Intern Med* 1983; 98: 76–85.
2. DeRemee RA, McDonald TJ, Weiland LH. Wegener's granulomatosis: observations on treatment with antimicrobial agents. *Mayo Clin Proc* 1985; 60: 27–32.
3. DeRemee RA. The treatment of Wegener's granulomatosis with trimethoprim/sulfamethoxazole: illusion or vision. *Arthritis Rheum* 1988; 31: 1068–1072.
4. Israel HL. Sulfamethoxazole-trimethoprim therapy for Wegener's granulomatosis. *Arch Intern Med* 1988; 148: 2293–2295.
5. Valeriano-Marcet J, Spiera H. Treatment of Wegener's granulomatosis with sulfamethoxazole-trimethoprim. *Arch Intern Med* 1991; 151: 1649–1652.
6. Wegener F. Über generalisierte, septische Gefässerkrankungen. *Verh Dtsch Ges Pathol* 1936; 26: 202–210.
7. Pinching AJ, Rees AJ, Pussell BA, Lockwood CM, Mitchison RS, Peters DK. Relapses in Wegener's granulomatosis: the role of infection. *BMJ* 1980; 281: 836–838.
8. Cohen Tervaert JW, Huitema MG, Hene RJ, et al. Relapses of Wegener's granulomatosis: prevention by treatment based on antineutrophil cytoplasmic antibodies. *Lancet* 1990; 336: 709–711.
9. Cohen Tervaert JW, van der Woude FJ, Fauci AS, et al. Association between active Wegener's granulomatosis and anticytoplasmic antibodies. *Intern Med* 1989; 149: 2461–2465.
10. Egner W, Chapel HM. Titration of antibodies against neutrophil cytoplasmic antigens is useful in monitoring disease activity in systemic vasculitides. *Clin Exp Immunol* 1990; 82: 244–249.
11. Hoffman GS, Kerr GS, Leavitt RY, et al. Wegener's granulomatosis: an analysis of 158 patients. *Ann Intern Med* 1992; 116: 488–498.
12. Stegeman CA, Cohen Tervaert JW, Sluiter WJ, et al. Association of chronic nasal carriage of *Staphylococcus aureus* and higher relapse rates in Wegener's granulomatosis. *Ann Intern Med* 1994; 120: 12–17.
13. Hoffman GS, Sechler JM, Gallin JI, Shelhamer JH, Suffredini A, Ognibene FP, et al. Bronchoalveolar lavage analysis in Wegener's granulomatosis: a method to study disease pathogenesis. *Am Rev Respir Dis* 1991; 143: 401–407.
14. Daha MR, Leusen J, Kramps JA, Schrama E, van Es LA, van der Woude FJ. Isolation from purulent sputum of an antigen reactive with antibodies in serum of patients with Wegener's granulomatosis. *Neth J Med* 1990; 36: 117–120.