

CASE REPORT

Migratory bronchiolitis obliterans organizing pneumonia after unilateral radiation therapy for breast carcinoma

B. Crestani*, M. Kambouchner**, P. Soler⁺, J. Crequit⁺⁺,
M. Brauner[#], J-P. Battesti*, D. Valeyre*

Migratory bronchiolitis obliterans organizing pneumonia after unilateral radiation therapy for breast carcinoma. B. Crestani, M. Kambouchner, P. Soler, J. Crequit, M. Brauner, J-P. Battesti, D. Valeyre. ©ERS Journals Ltd 1995.

ABSTRACT: We report the case of a 59 year old woman who developed cough, dyspnoea and fever with patchy migratory airspace infiltrates, 2 months after right breast radiation therapy for breast carcinoma. Lung infiltrates were initially localized in the irradiated area and spread to the contralateral lung. Lung biopsy, performed in an unirradiated area of the contralateral lung 9 months after completion of radiotherapy, revealed a typical histological pattern of bronchiolitis obliterans organizing pneumonia. No cause of bronchiolitis obliterans organizing pneumonia other than radiation was found. Treatment with corticosteroids resulted in rapid clinical improvement and complete resolution of airspace opacities.

This case suggests that localized lung irradiation might trigger the development of a bilateral lung disease, with a histological pattern of bronchiolitis obliterans organizing pneumonia.

Eur Respir J., 1995, 8, 318–321.

*Pulmonary Unit, **Pathology Department and [#]Radiology Department, Hôpital Avicenne, Bobigny, France, ⁺⁺Pulmonology Unit, Beauvais, France, ⁺Inserm unité 82, faculté Bichat, Paris, France.

Correspondence: D. Valeyre
Hôpital Avicenne
Service de Pneumologie
125 route de Stalingrad
93000 Bobigny
France

Keywords: Breast carcinoma, bronchiolitis obliterans organizing pneumonia, mast cells, radiation therapy

Received: July 4 1994

Accepted after revision November 6 1994

Radiation-induced injury of the lung is well-recognized as a potential complication in the treatment of patients with carcinoma of the breast [1]. Classically, radiation pneumonitis is confined to the irradiated area, but recent studies suggest that inflammation is widespread [2, 3]. In this setting, we report the case of a woman who developed bilateral migratory infiltrates, with histologically proven bronchiolitis obliterans organizing pneumonia, after right breast radiotherapy for carcinoma.

Case report

A 59 year old nonsmoking woman was diagnosed as having an 8 mm ductal carcinoma of the right breast. A superior and external quadrantectomy was performed in October 1991, and postoperative radiotherapy was given between January 2 and February 26, 1992, using a Gammatron S (Siemens) with a ⁶⁰Co source. The lower half of the right breast, the axillary area, the right supraclavicular fossa and the right internal mammary lymph node chain received ⁴⁵Gy in 25 fractions over 34 days. The upper half of the right breast received 65Gy in 36 fractions over 54 days. The patient received neither chemotherapy nor hormone therapy. There was no exposure to inhaled antigens or toxins, and no history of gastro-oesophageal reflux or systemic disease.

Two months after completion of radiotherapy, a non-productive cough appeared and persisted over the following months. Four months after completion of radiotherapy, the patient began to experience nocturnal sweats and

a progressive weight loss of 6 kg. Fever of 39°C was measured on different days, and a mild dyspnoea appeared. A chest roentgenogram showed an ill-defined infiltrate in the right lower lobe (in the irradiated area) with an air bronchogram present. Over the following 2 months, the patient received short courses of various antibiotics (amoxicillin, amoxycillin and clavulanic acid, ceftriaxone, and ofloxacin) with no improvement of symptoms. The patient used acetaminophen intermittently as an antipyretic drug. She denied using any other therapy. She was admitted to the pulmonology unit of Avicenne hospital in October 1992, six months after completion of radiotherapy, because of persistent fever, nonproductive cough and migratory lung infiltrates.

On examination, oral temperature was 37.7°C and bibasilar inspiratory crackles were heard. Cardiac sounds were normal. The abdomen was free of organomegaly, and no peripheral adenopathy was found. The right breast scar was painless, and the left breast was normal. Digital clubbing was absent.

A chest roentgenogram showed peripheral airspace infiltrates located at both apices and in the left axillar region. Careful review of previous roentgenograms revealed the migratory characteristic of the infiltrates, which began in the right lower lobe, then spread to the right upper lobe, left upper lobe and ultimately left lower lobe. High resolution computed tomography of the thorax (HRCT) confirmed the airspace opacities and their migratory pattern (fig. 1). There was no evidence of lymphadenopathy or pleural effusion.

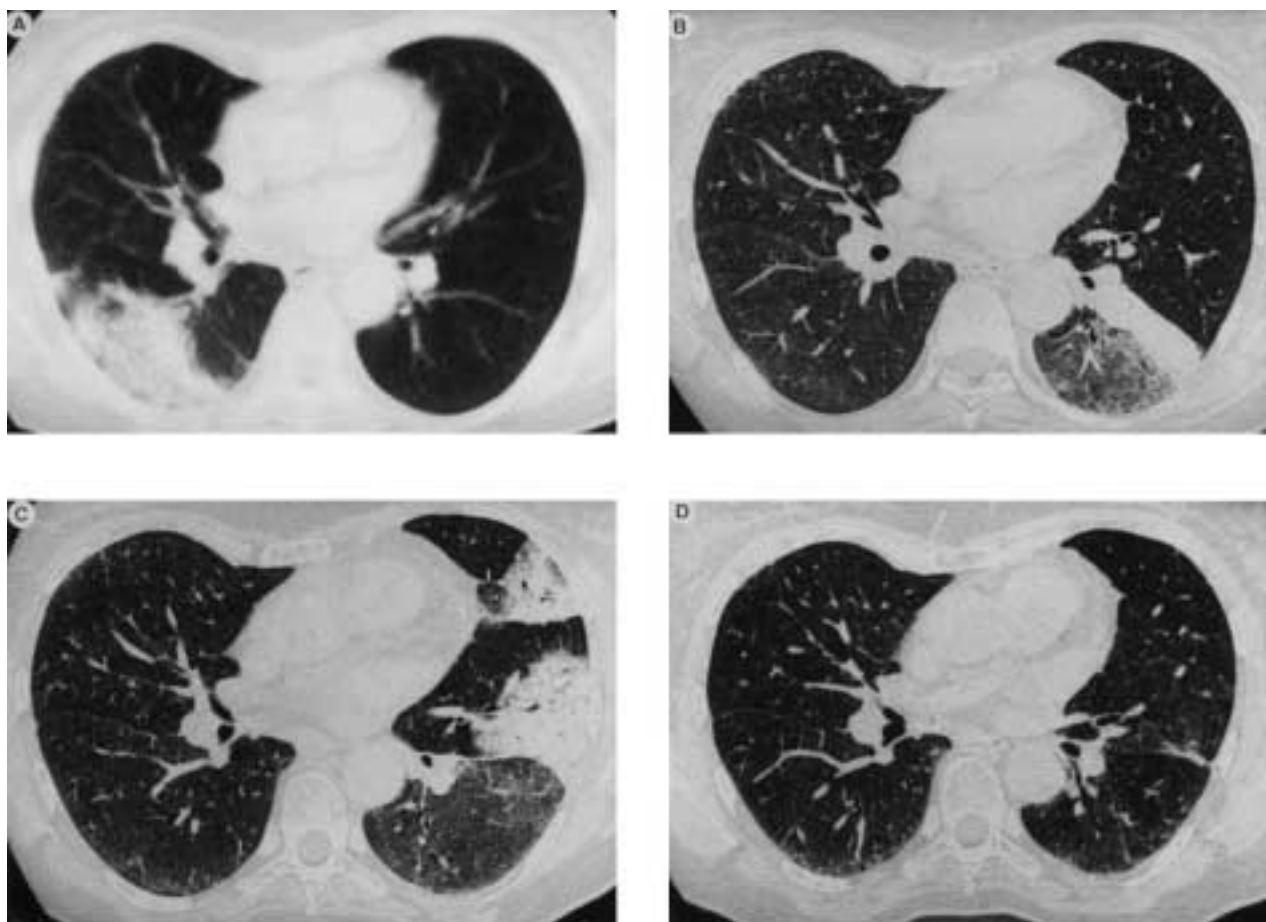


Fig. 1. – Computed tomography of the chest. Sequential evaluation was obtained: A) 5 months; B) 8 months; and C) 9 months after completion of right breast radiotherapy; and D) 3 months after initiation of steroid therapy. This illustrates the spontaneous migratory pattern of airspace opacities, which began in the right lower lobe, and then spread to the left lung. Complete resolution of opacities was obtained with steroids. Note that different algorithms were used in panel A and panels B, C, and D (high resolution), respectively.

Respiratory function tests (expressed as % of predicted) showed normal lung volumes (vital capacity 112% pred; total lung capacity 93% pred; residual volume 74% pred). Flow volume curves were normal. Carbon monoxide transfer capacity was 90% of predicted when corrected for haemoglobin level and alveolar volume. Data from arterial blood gases drawn whilst the patient was breathing room air were: arterial oxygen tension (P_{aO_2}), 9.6 kPa (72 mmHg); arterial carbon dioxide tension (P_{aCO_2}), 4.7 kPa (35 mmHg); and pH 7.47.

Haemoglobin was $100 \text{ g}\cdot\text{l}^{-1}$; the white blood cell count $5.75 \times 10^9 \text{ cells}\cdot\text{l}^{-1}$ with 60% neutrophils, 24% lymphocytes, 8% monocytes and 3% eosinophils; and platelet count $384 \times 10^9 \text{ platelets}\cdot\text{l}^{-1}$. The one hour erythrocyte sedimentation rate was $58 \text{ mm}\cdot\text{h}^{-1}$. The search for anti-nuclear antibodies, rheumatoid factor and autoantibodies to neutrophil cytoplasmic antigens was negative. Total serum complement was normal. Serum angiotensin converting enzyme level was within the normal range, as were the serum carcinoembryonic antigen (CEA) and carbohydrate-antigen 15-3 (CA 15-3) levels. Serological testing for human immunodeficiency virus (HIV-1 and HIV-2), human T-cell lymphotropic virus-1 (HTLV-1), hepatitis B and C viruses, Mycoplasma, Chlamydia and

Legionella was negative. Precipitins for *Aspergillus* species, pigeon breeders' disease and farmers' lung were absent.

A fiberoptic bronchoscopy showed a normal bronchial tree. Bronchoalveolar lavage (BAL) was performed in a segment of the right lower lobe that was included in the radiation field (but was radiographically normal at the time of examination) and in the left lower lobe, in the nonirradiated side of the chest, in a segment that appeared abnormal on HRCT. Samples were collected and analysed separately. Enumeration of different cell types and lymphocyte phenotyping (table 1) was performed on cytocentrifugation smears after May-Grünwald-Giemsa staining. The surface phenotype of lymphocytes recovered by lavage was evaluated by indirect immunofluorescence microscopy, anti-CD4 (OKT4 and OKT4A, Ortho Diagnostics, Raritan, NJ, USA) and anti-CD8 (IOT 8, Immunotech, Marseille, France) monoclonal antibodies being used. A careful search for pathogens in BAL fluid was negative, notably viral cultures for adenovirus, myxovirus influenzae A and B, respiratory syncytial virus and cytomegalovirus were negative, and acid-fast bacilli were not detected. A left lower lobe transbronchial biopsy produced a small sample of normal lung tissue.

Table 1. – Bronchoalveolar lavage cell data

	Right lower lobe	Left lower lobe
Recovery %	80	40
Total cell count $\times 10^3 \cdot \text{ml}^{-1}$	535	1500
Differential cell count %		
Macrophages	65.2	20.8
Lymphocytes	31	53.8
Neutrophils	2.2	1.8
Eosinophils	0.6	14.8
Mast cells	1	8.8
Lymphocyte phenotyping		
CD4+ %	16	48
CD8+ %	78	49
CD4+/CD8 ratio	0.20	0.98

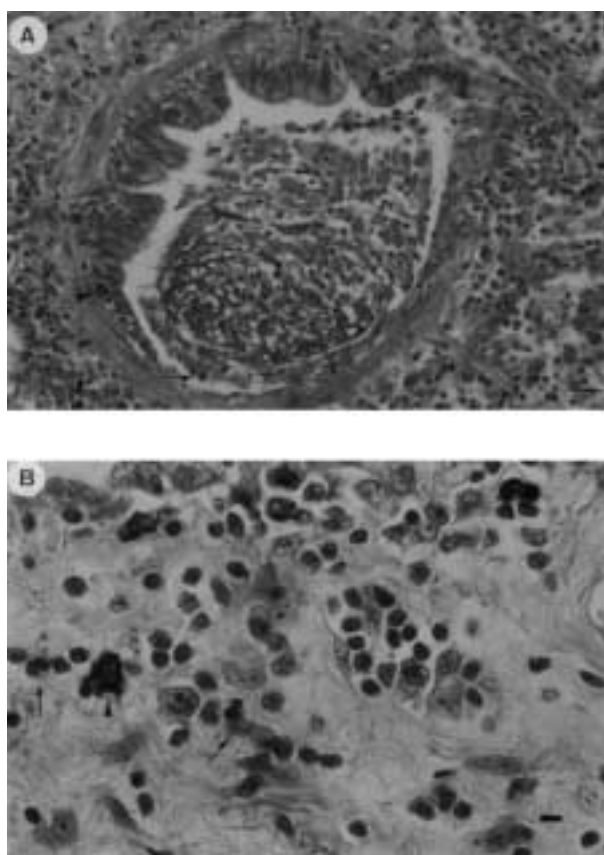


Fig. 2. – A) Histological section of open lung biopsy specimen showing obliteration of a respiratory bronchiole by an intraluminal fibrotic bud. Both mast cells (arrow heads) and polymorphonuclear eosinophils (arrow) are evident on this section. (Giemsa stain; internal scale bar=35 μm). B) High power view of an adjacent area with organizing pneumonia. Mast cells (arrow head), with their characteristic metachromatic cytoplasmic granules, and polymorphonuclear eosinophils (arrows) are seen in the interstitium. (Giemsa stain; internal scale bar=10 μm).

A surgical biopsy of the apical segment of the left lower lobe (that appeared abnormal on HRCT) was performed under videothoracoscopy in November 1992. Histological findings revealed a typical pattern of bronchiolitis obliterans organizing pneumonia, with infiltration of

mast cells and polymorphonuclear eosinophils in the alveolar septa (fig. 2). There was no evidence of hyaline membrane or vascular changes, which are suggestive of radiation-induced lung injury. The alterations appeared focal, since a sample obtained from the apex of the posterior segment of the left lower lobe was microscopically normal.

Treatment with corticosteroids resulted in rapid clinical improvement and complete resolution of airspace opacities. The patient was well in December 1993, six months after steroids were stopped.

Discussion

The originality of this case lies in the occurrence of a histologically proven bronchiolitis obliterans organizing pneumonia in the months following thoracic irradiation for breast carcinoma. Pathological diagnosis was obtained in an unirradiated area of the contralateral lung.

We believe that in this patient bronchiolitis obliterans organizing pneumonia was related to irradiation. Firstly, the lung infiltrates were detected initially in the irradiated area, with a temporal relationship that fitted with the usually reported delay between radiation exposure and acute lung disease [1]. Secondly, all other causes of bronchiolitis obliterans organizing pneumonia were excluded. In particular, there was no evidence of collagen vascular disease, no exposure to fume, toxins or drugs known to induce a bronchiolitis obliterans organizing pneumonia pattern [4]. Lack of effect of various antibiotics, negative serological testing, and negative search for pathogens in BAL fluid and lung biopsy make the hypothesis of an infectious process very unlikely. Moreover, there was no histological evidence of granulomas, vasculitis, or extensive infiltration with eosinophils in the lung, which could have suggested a diagnosis of extrinsic allergic alveolitis, Wegener's disease, or chronic eosinophilic pneumonia, respectively; all conditions that may indicate bronchiolitis obliterans organizing pneumonia [5].

Radiation-induced injury of the lung is a common event after irradiation for carcinoma of the breast [1]. One of its most classical features is that the pathological and radiological changes are confined to the outline of the fields of radiation [1, 6]. Two distinct clinical stages have been recognized: an early transient radiation pneumonitis which occurs about 4–12 weeks after completion of radiotherapy, and a later chronic radiation fibrosis occurring more than 9 months after treatment. The underlying pathological events are well-characterized, and consist successively in an acute exsudative phase, an organizing or proliferative phase, and a chronic fibrotic phase [1]. Certain findings, such as hyaline membranes, marked cytological atypia within hyperplastic pneumocytes, and prominent vascular changes (with thrombosis and vascular sclerosis), are suggestive of radiation-induced lung injury [6]. By contrast, a histological pattern of bronchiolitis obliterans organizing pneumonia is a very uncommon finding after radiation exposure. In the only two cases reported in the literature, this histological pattern

was strictly limited to the irradiated area [7, 8], and the onset of the disease was found two months [7], and 13 yrs [8], after completion of irradiation, in conjunction with findings suggestive of radiation-induced lung injury [7].

In the patient presented here, careful examination of histological sections obtained from the nonirradiated lung did not detect changes usually associated with radiation-induced lung injury. Moreover, the fields used were such that there could be no scattered irradiation of the contralateral lung. Therefore, despite the evidence that bronchiolitis obliterans organizing pneumonia was causally related to irradiation, we believe that it was not a direct effect, of irradiation but an indirect effect, that must be viewed in the light of the immunological hypothesis of radiation-induced lung disease.

It has been suggested that radiation pneumonitis represents a form of immunologically-mediated hypersensitivity pneumonitis [2, 3, 9, 10]. Indeed, in a few patients, extensive radiographic changes outside the field, even in the contralateral lung, have been observed after lung irradiation [9]. Recently, a prominent lymphocytic alveolitis, more pronounced in patients developing clinical pneumonitis, has been shown to develop in both lung fields after strictly unilateral thoracic irradiation [2, 3]. We also found an increased lymphocyte count in both sides of the lungs. Lymphocytosis consisted predominantly of CD8+ lymphocytes in the right lung (that appeared normal on HRCT); whereas, CD4+ and CD8+ lymphocytes were quantitatively similar in the left lung (that appeared abnormal on HRCT). Both results are consistent with bronchiolitis obliterans organizing pneumonia [11].

A prominent finding in this patient was the increased number of mast cells in the BAL fluid, and the infiltration of mast cells in the alveolar septa. Pulmonary mastocytosis is a well-documented phenomenon after lung radiation in animals [6, 12], most obvious in the areas of fibrosing alveolitis, but also apparent in the lung tissue of normal-appearance in irradiated rats [13]. This suggests that mast cells could participate in the induction of radiation-induced lung injury through the release of various mediators [13, 14], as suspected in the pathogenesis of hypersensitivity pneumonitis due to inhaled antigens [15]. However, the precise role of mast cells is unknown, since increased numbers of mast cells are sometimes observed in BAL in bronchiolitis obliterans organizing pneumonia not associated with irradiation [11].

We believe that this case clearly indicates that, in addition to the classical radiation pneumonitis localized in the irradiated area, unilateral lung irradiation may trigger the development of migratory lung infiltrates with histological features of bronchiolitis obliterans organiz-

ing pneumonia. This diagnosis must be evoked in the case of bilateral infiltrates occurring after thoracic irradiation, as well as infection, recurrent or metastatic neoplasm, or drug-induced toxic effects.

Acknowledgements: The authors thank D. Gay, Centre de Radiothérapie et d'Oncologie Médicale, Compiègne, France, for his help in the recovery of radiotherapy data.

References

1. Davis SD, Yankelevitz DH, Henschke CI. Radiation effects on the lung: clinical features, pathology, and imaging findings. *Am J Roentgenol* 1992; 159: 1157-1164.
2. Gibson PG., Bryant DH, Morgan GW, et al. Radiation-induced lung injury: a hypersensitivity pneumonitis? *Ann Intern Med* 1988; 109: 288-291.
3. Roberts CM, Foulcher E, Zaunders JJ, et al. Radiation pneumonitis: a possible lymphocyte-mediated hypersensitivity reaction. *Ann Intern Med* 1993; 118: 696-700.
4. Camus P, Lombard JN, Perrichon M, et al. Bronchiolitis obliterans organising pneumonia in patients taking acebutolol or amiodarone. *Thorax* 1989; 44: 711-715.
5. Kitaichi M. Differential diagnosis of bronchiolitis obliterans organizing pneumonia. *Chest* 1992; 102: 44S-49S.
6. Gross NJ. Pulmonary effects of radiation therapy. *Ann Intern Med* 1977; 86: 81-92.
7. Kaufman J, Komorowski R. Bronchiolitis obliterans: a new clinicopathologic complication of irradiation pneumonitis. *Chest* 1990; 97: 1243-1244.
8. Tobias ME, Plit M. Bronchiolitis obliterans organizing pneumonia with migratory infiltrates: a late complication of radiation therapy. *Am J Roentgenol* 1993; 160: 205-206.
9. Bennett D, Million RR, Ackerman LV. Bilateral radiation pneumonitis, a complication of the radiotherapy of bronchogenic carcinoma. *Cancer* 1969; 23: 1001-1018.
10. Holt JAG. The acute radiation pneumonitis syndrome. *J Coll Radiol Aust* 1964; 8: 40-47.
11. Costabel U, Teschler H, Guzman J. Bronchiolitis obliterans organizing pneumonia (BOOP): the cytological and immunocytological profile of bronchoalveolar lavage. *Eur Respir J* 1992; 5: 791-797.
12. Watanabe S, Watanabe K, Ohishi T, Aiba M, Kageyama K. Mast cells in the rat alveolar septa undergoing fibrosis after ionizing irradiation. *Lab Invest* 1974; 31: 555-567.
13. Aldenborg F, Nilsson K, Jarlshammar B, Bjermer L, Enerback L. Mast cells and biogenic amines in radiation-induced pulmonary fibrosis. *Am J Respir Cell Mol Biol* 1993; 8: 112-117.
14. Bienenstock J, Tomioka M, Stead R. Mast cell involvement in various inflammatory processes. *Am Rev Respir Dis* 1987; 135: 5-8.
15. Soler P, Nioche S, Valeyre D, et al. Role of mast cells in the pathogenesis of hypersensitivity pneumonia. *Thorax* 1987; 42: 565-572.