

CASE REPORT

Acute eosinophilic pneumonia in a heroin smoker

P.E. Brander*, P. Tukiainen**

Acute eosinophilic pneumonia in a heroin smoker. P.E. Brander, P. Tukiainen. ©ERS Journals Ltd 1993.

ABSTRACT: Inhalation of heroin is known to provoke asthma. We report on the case of a patient who, after repeated inhalation of heroin, presented with decreased lung volume associated with bronchial hyperresponsiveness, diffuse pulmonary infiltrates, and bronchoalveolar lavage fluid eosinophilia. Rapid remission was obtained after heroin abstinence and initiation of corticosteroid treatment. *Eur Respir J., 1993, 6, 750-752.*

*Kiljava hospital, Kiljava, Finland. **Dept of Pulmonary Medicine, Helsinki University Central Hospital, Helsinki, Finland.

Correspondence: P. Brander
Vipusentie 9
SF-05460 Hyvinkää
Finland

Keywords: Asthma; eosinophilic pneumonia; heroin; opiate abuse; pulmonary eosinophilia

Received: June 2 1992
Accepted after revision January 25 1993

Smoking of heroin, *i.e.* inhalation of vapours after heating of heroin on a metal foil ("chasing the dragon"), is a quick and potent method of heroin intake. In recent years, this method of heroin abuse has become increasingly popular among addicts [1, 2]. By inhalation, the infective risks of intravenous administration are avoided. Heroin smoking can produce severe bronchospasm in asthmatics and also in individuals with no previous history of asthma [3, 4]. We describe here a patient with no history of asthma, in whom regular inhalation of heroin led to reversible bronchial obstruction, which was associated with diffuse pulmonary infiltrates, and with an increased number of eosinophils detected by bronchoalveolar lavage.

Case report

A 24 year old smoking female, with no history of asthma, was admitted to our hospital because of cough and dyspnoea. She had inhaled heroin occasionally for 1.5 yrs, and more regularly during the preceding weeks, but had never abused drugs intravenously. She had no regular medication.

Six months previously, she had, for the first time, experienced dyspnoea with cough and wheezing after inhaling heroin daily for a couple of weeks. During antibiotic treatment, and with cessation of heroin inhalation, the symptoms disappeared. The chest radiograph was normal at that time.

Before the present admission, she had inhaled heroin daily for five weeks. During the previous three weeks she had suffered from cough and progressive dyspnoea. One week before admission, treatment with co-trimoxazole and inhaled salbutamol (by metered dose inhaler) had been started. The patient persisted in inhaling heroin.

On admission, the patient presented with severe dyspnoea and wheezing. Her pulse was 100 beats·min⁻¹, and

blood pressure was 110/80 mmHg. The temperature was 36.5 °C. On auscultation, a coarse expiratory wheeze was heard throughout her chest. Her peak expiratory flow rate (PEF) was 260 l·min⁻¹ (50% predicted). Her arterial blood gases showed a lowered arterial oxygen tension (PaO₂) of 7.5 kPa when breathing 35% oxygen. Peripheral blood analysis gave a white blood cell count of 17.3×10⁹·l⁻¹, and a C-reactive protein (CRP) concentration of 79 mg·l⁻¹. A differential white blood cell count was not performed. The chest radiograph disclosed diffuse bilateral infiltration (fig 1). Treatment was started with inhaled bronchodilators, parenteral aminophylline and methylprednisolone, together with oral (prednisolone, 40 mg·day⁻¹) and inhaled (budesonide, 2.4 mg·day⁻¹) steroids, and parenteral erythromycin.

The patient responded quickly to the therapy, and the next morning her PEF had risen to 365 l·min⁻¹. Lung function testing on the second day showed lung volumes and diffusing capacity for carbon monoxide (DLCO) of >80% of the predicted values [5]. Bronchial provocation with histamine showed abnormal bronchial responsiveness (table 1). The leucocytosis in the peripheral blood had disappeared. A differential cell count was now performed and showed no eosinophilia.

Fibreoptic bronchoscopy, performed on the third day, revealed a swollen and reddened tracheobronchial mucosa. Bronchial or transbronchial biopsies were not taken. Bronchoalveolar lavage (BAL) fluid from the right middle lobe yielded a normal total cell count (93×10⁶·l⁻¹), and an increased percentage of eosinophils (29%) on the cytocentrifugation preparation. The macrophages contained tiny particles of coal and of some unidentified material. A large number of microbiological and immunological assessments of serum, sputum and BAL fluid were all negative. The patient was seronegative for human immunodeficiency virus (HIV). *Aspergillus* serum precipitins were absent.

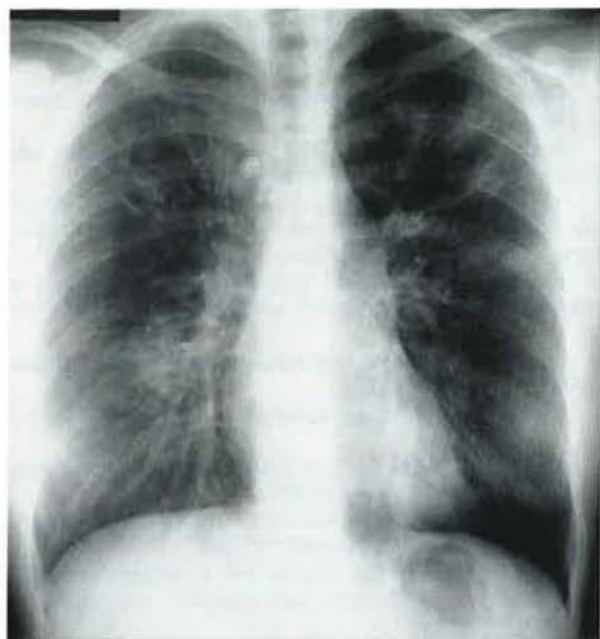


Fig. 1. — Chest radiograph taken on admission showing bilateral infiltrates.

Within a few days, chest auscultation and laboratory findings normalized, and the infiltration on the chest radiograph disappeared. Lung function testing, 7 days after the first examination, showed significantly higher values for all lung volumes and for diffusing capacity. The bronchial responsiveness to histamine was still increased (table 1). Monitored PEF stayed at about $450 \text{ l}\cdot\text{min}^{-1}$, with no significant diurnal variation.

The patient was discharged eight days after admission in good general condition. Treatment with prednisolone $30 \text{ mg}\cdot\text{day}^{-1}$, inhaled salbutamol $0.4 \text{ mg}\cdot\text{day}^{-1}$, and budesonide $0.8 \text{ mg}\cdot\text{day}^{-1}$ was continued; the prednisolone dose was reduced by 10 mg every week.

At follow-up, three weeks later, the patient was symptom free and had a normal chest examination and radiograph.

Table 1. — Lung function measurements

	Day 2	Day 8
$\text{FEV}_1 \text{ l}$	3.3 (80)	4.7 (115)
FVC l	3.9 (85)	5.4 (116)
$\text{FEV}_1/\text{FVC} \%$	85	87
TLC l	5.5 (86)	6.5 (101)
$\text{DLCO mmol}\cdot\text{min}^{-1}\cdot\text{kPa}^{-1}$	7.7 (85)	9.0 (99)
$\text{PD}_{15} \text{ mg}$	0.82	0.50

Data in parentheses are percentage predicted. FEV_1 : forced expiratory volume in one second; FVC : forced vital capacity; TLC : total lung capacity, calculated from single breath helium dilution; DLCO : diffusing capacity for carbon monoxide; PD_{15} : provocative dose of histamine causing a fall of 15% in the baseline FEV_1 . In our laboratory, the highest histamine dose used for provocation is 1.6 mg . PD_{15} values $>1.6 \text{ mg}$ represent normal bronchial responsiveness to histamine.

The Serum total immunoglobulin E (IgE) concentration was $2,400 \text{ units}\cdot\text{l}^{-1}$ (normal 0–110). She had inhaled heroin on two days after discharge, but had abstained from further use because of a recurrence of coughing. A follow-up visit with a skin prick test and lung function measurements was programmed, but the patient failed to return.

Discussion

Infections and pulmonary oedema after intravenous intake are the most common pulmonary complications associated with opiate abuse. Overdose with opiates may lead to central respiratory depression [6]. Heroin, like other opiates, is a powerful releaser of histamine [4]. Asthmatic attacks shortly after inhaling heroin have been described, both in association with heroin abuse and after occupational exposure to heroin dust [3, 4, 7, 8]. Recently, a case of acute eosinophilic pneumonia induced by inhaled crack cocaine has been described [9]. To the best of our knowledge, acute eosinophilic pneumonia associated with heroin smoking has not yet been previously reported.

Eosinophilic pneumonia has been defined by LIEBOW and CARRINGTON [10] as "pulmonary infiltrations of the lung by eosinophils that may or may not be accompanied by an excess of these cells in the peripheral blood". Diffuse pulmonary infiltrates on the chest radiograph, with an increased number of eosinophils detected by bronchoalveolar lavage and/or lung biopsy, indicate the diagnosis [11–13]. Several aetiological agents have been described, including drugs, parasitic infections and systemic vasculitis. In most cases the cause remains unknown. Drug-induced eosinophilic pneumonia usually resolves rapidly after discontinuation of the causative agent. Recently, an acute form of eosinophilic lung disease presenting as respiratory failure and responding quickly to corticosteroid treatment has been described. In the majority of these cases there was no peripheral blood eosinophilia [14].

In our patient, long-term abuse of heroin by inhalation led to decreased lung volume with possible initial bronchial obstruction which responded readily to standard treatment. The rapid clinical recovery, with resolution of the chest radiograph infiltration and increase in lung volumes and diffusing capacity, after institution of corticosteroid treatment, together with BAL fluid eosinophilia are suggestive of acute eosinophilic pneumonia. Peripheral blood eosinophilia was not observed, but may have been present on admission. Unfortunately, a differential white blood cell count was not performed initially. When BAL was performed, the patient had already received 125 mg parenteral methylprednisolone and 120 mg oral prednisolone, and the chest radiograph was nearly normal. The total cell and eosinophil counts in the BAL fluid had probably already decreased from their maximum values.

The cause of BAL fluid eosinophilia in our patient remained uncertain, but the temporal relationship to heroin inhalation was interesting. The high total serum IgE value points indirectly to the possibility of an IgE-mediated hypersensitivity reaction. The reaction might have been triggered by the inhaled heroin *per se*, or by the impuri-

ties inevitably inhaled with heroin (such as various powdered carrier substances). The reaction obviously resulted in an eosinophilic inflammation both of lung tissue and of airways, with release of mediators and tissue injury; the airway inflammation causing bronchial hyperresponsiveness which persisted, for at least some time, after clinical remission. Our case was quite similar to that induced by inhaled crack cocaine [9].

The patient had co-trimoxazole treatment for respiratory tract infection during one week before hospital admission. Thus, we cannot exclude the possibility that the acute lung reaction was induced by co-trimoxazole. However, we consider it unlikely, because the patient had also been treated with this antibiotic previously, without any side-effects. In addition, during follow-up her symptoms recurred after heroin inhalation. There was no evidence of systemic vasculitis. Parasitic infection was unlikely, because the patient had not visited countries where nematodal parasites are endemic.

Our patient had no history of asthma before onset of heroin smoking. However, as she failed to appear at further follow-up investigations, underlying asthma or bronchial hyperresponsiveness cannot be ruled out.

References

1. Gossop M, Griffiths P, Strang J. - Chasing the dragon: characteristics of heroin chasers. *Br J Addict* 1988; 83: 1159-1162.
2. Strang J, Griffiths P, Powis B, Gossop M. - First use of heroin: changes in route of administration over time. *Br Med J* 1992; 304: 1222-1223.
3. Oliver RM. - Bronchospasm and heroin inhalation. *Lancet* 1986; i: 915.
4. Hughes S, Calverley PMA. - Heroin inhalation and asthma. *Br Med J* 1988; 297: 1511-1512.
5. Viljanen A. - Reference values for spirometric, pulmonary diffusing capacity and body plethysmographic studies. *Scand J Clin Invest* 1982; 42 (Suppl. 159): 1-50.
6. Glassroth J, Adams GD, Schnoll S. - The impact of substance abuse on the respiratory system. *Chest* 1987; 91: 596-602.
7. Agius R. - Opiate inhalation and occupational asthma. *Br Med J* 1989; 298: 323.
8. Shaikh WA. - Allergy to heroin. *Allergy* 1990; 45: 555-556.
9. Oh PI, Balter MS. - Cocaine-induced eosinophilic lung diseases. *Thorax* 1992; 47: 478-479.
10. Liebow AA, Carrington CB. - The eosinophilic pneumonias. *Medicine* 1969; 48: 252-285.
11. Badesh DB, King TE, Schwarz MI. - Acute eosinophilic pneumonia: a hypersensitivity phenomenon? *Am Rev Respir Dis* 1989; 139: 249-252.
12. Allen JN, Davis BW, Pacht ER. - Diagnostic significance of increased bronchoalveolar lavage fluid eosinophils. *Am Rev Respir Dis* 1990; 142: 642-647.
13. Anonymous. - Acute eosinophilic pneumonia. *Lancet* 1990; 335: 947.
14. Allen JN, Pacht ER, Gadek JE, Davis WB. - Acute eosinophilic pneumonia as a reversible cause of noninfectious respiratory failure. *N Engl J Med* 1989; 321: 569-574.