

Vomiting in a patient with an Angelchik prosthesis

J. van der Berg*, P.E. Postmus**

Case report

A 50 yr old man was referred from a hospital for mentally ill and disabled people to the emergency department. He was known to have Little's syndrome (hemiplegia spastica infantilis). For two days he had complained of upper abdominal pain, nausea and vomiting. Six years previously an Angelchik prosthesis had been implanted to prevent gastro-oesophageal reflux. Due to chronic reflux there was some stenosis in the distal part of the oesophagus. He normally used ranitidine chloride, 150 mg *b.i.d.*, but had not been able to keep this down during the last 48 h.

On admission the patient was dehydrated, apparently ill, fever 38.2°C, blood pressure 90/60 mmHg, pulse rate 100 beats·min⁻¹ and regular, respiratory rate 30 breaths·min⁻¹ without cyanosis. There was dullness over the dorsal basal part of the right hemithorax and breath sounds were diminished on the right compared to the left. Heart sounds were normal. Examination

of the abdomen showed normal peristalsis and there were no signs of muscular defence.

Laboratory investigations showed erythrocyte sedimentation rate 60 mm·h⁻¹, leucocytosis $24.4 \times 10^9 \cdot l^{-1}$ with 6% band forms, haemoglobin 182 g·l⁻¹, serum creatinine 114 $\mu\text{mol} \cdot l^{-1}$ (normal 62-106 $\mu\text{mol} \cdot l^{-1}$), serum urea 17.5 mmol·l⁻¹ (normal 3.3-6.7 mmol·l⁻¹), serum lactate dehydrogenase (LDH) 507 U·l⁻¹ (normal <235 U·l⁻¹) and serum amylase also 1,409 U·l⁻¹ (normally <300 U·l⁻¹). The amylase level in the urine was also elevated: 8,028 U·l⁻¹ (normal <3,500 U·l⁻¹).

A thorax drain was introduced and some air escaped followed by dark brown fluid. In this fluid the amylase level was 15,012 U·l⁻¹. A Gram stain showed Gram-positive cocci and Gram-negative cocci and rods.

An anteroposterior (AP) chest roentgenogram was made in the supine position (fig. 1).

Interpret this roentgenogram before turning the page

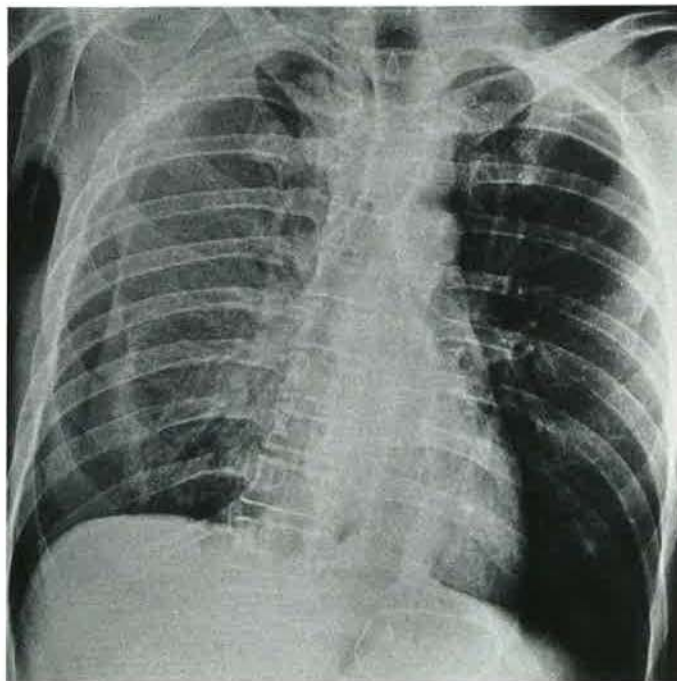


Fig. 1. - Chest X-ray in the supine position.

* Dept of Pulmonary Diseases, University Hospital, Groningen, The Netherlands. ** Dept of Pulmonary Diseases, Free University Hospital, P.O. Box 7057, 1007 MB, Amsterdam, The Netherlands.

NEXT PAGE FOR DIAGNOSIS

Interpretation of the chest roentgenogram

There is an Angelchik prosthesis without signs of dislocation. Over the whole right hemithorax there is diffuse shadowing. This is caused by fluid in the right hemithorax beneath the lung. There is also a right-sided pneumothorax.

At the thoracic inlet, the mediastinum is widened and the trachea is displaced to the left by air in the mediastinum. There is also air around the left main bronchus at the arrow. Thus, there is mediastinal emphysema.

Further roentgenograms

After introduction of a gastric tube, much air escaped and the abdominal pain disappeared. Subsequently, a roentgen contrast swallow of the oesophagus was made (fig. 2). This showed leakage of contrast into the mediastinum and pleural space to the right.

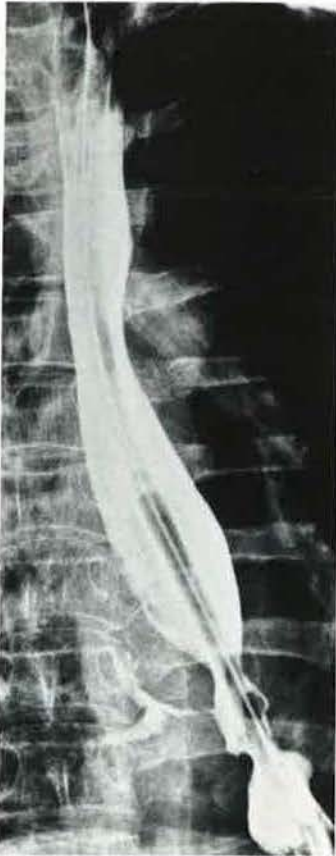

Fig. 2. - Roentgen contrast swallow of the oesophagus, showing leakage of contrast into the mediastinum and pleural cavity on the right.

Diagnostic considerations

The case report describes a vomiting, dehydrated, febrile patient with leucocytosis and a markedly raised serum amylase. There was dullness and reduced breath sounds over the lower part of the right chest.

This, together, may suggest a pleural exudate with infection. This could lead to the diagnosis of empyema, and one should then think of various causes for empyema. The extravasation of contrast on the right in the distal part of the oesophagus confirmed the suspicion already raised after the demonstration of mediastinal emphysema.

Diagnosis: perforation of the oesophagus with pneumothorax and empyema

Treatment and clinical course

Under general anaesthesia, three drains were placed in the pleural space and mediastinum. A gastrostomy drain was used to prevent reflux. Feeding was given through a tube in the jejunum. Despite intensive treatment with antibiotics and respiratory support the patient died of respiratory failure after nine days.

The postmortem investigation revealed encapsulated fluid with necrotic debris between the middle lobe and the pericardium, a thickened wall of the distal oesophagus without a visible perforation, the Angelchik prosthesis *in situ*, adherent with the surrounding tissues, ulcers in the gastric wall, besides gas no abnormalities in the jejunum, and a normal spleen, liver and pancreas.

Pathogenesis

The Angelchik prosthesis consists of a silicone collar containing circumferential tape, tied around the cardiooesophageal junction [1]. The knot is secured by a polypropylene tie or clip. PUCHETTI [2] mentioned three indications for this device, namely: a) elderly patients at high surgical risk; b) obese, brachytypical patients; and c) presence of severe oesophagitis, even with a short oesophagus.

The time for this operation is significantly shorter than the time for Nissen fundoplication, as reported by GOURLEY *et al.* [3], but otherwise there are no advantages for either operation [3, 4], although in cases of failure of other surgical procedures the Angelchik prosthesis has been found to be rather effective [5]. Many complications due to the Angelchik prosthesis have been reported, such as intragastric penetration, pericarditis and transmural migration, gastric stricture, migration into the pelvis or mediastinum, pericapsular fibrous tissue formation.

DURRANS *et al.* [5] postulated that established oesophageal stricture is a relative contraindication for an Angelchik prosthesis. In this patient the Angelchik prosthesis did not prevent reflux and vomiting, which ultimately led to a perforation in the lower oesophagus with a pneumothorax and leaking of gastric contents and saliva into the pleural cavity.

In this patient, the chest roentgenogram gives the most important diagnostic information. The presence

of mediastinal emphysema and a hydropneumothorax strongly suggest oesophageal rupture, and the latter diagnosis was confirmed by the roentgen contrast swallow of the oesophagus.

Keywords: Angelchik prosthesis
mediastinal emphysema
oesophageal rupture

References

1. Angelchik JP, Cohen R. - A new surgical procedure for the treatment of gastro-oesophageal reflux and hiatus hernia. *Surg Gynecol Obstet*, 1979; 148: 246-248.
2. Puchetti V. - Our experience on the use of the antireflux prosthesis by the Angelchik method (personal contribution of 26 cases). *Chir Ital*, 1989; 41: 145-159.
3. Gourley GR, Pellett JR, Li BU, Adkins WN Jr. - A prospective, randomized, double-blind study of gastro-oesophageal reflux surgery in pediatric-sized developmentally disabled patients: Nissen fundoplication versus Angelchik prosthesis. *J Pediatr Gastroenterol Nutr*, 1986; 5: 52-61.
4. Deakin M, Mayer D, Temple JG. - Surgery for gastro-oesophageal reflux: the Angelchik prosthesis compared to the floppy Nissen fundoplication. Two year follow-up study and a five year evaluation of the Angelchik prosthesis. *Ann R Coll Surg Engl*, 1989; 71: 249-252.
5. Durrans D, Armstrong CP, Taylor TV. - The Angelchik anti-reflux prosthesis: some reservations. *J Surg*, 1985; 72: 525-527.