

Three cases of idiopathic bronchiolitis obliterans with organizing pneumonia

J. Alegre-Martin*, T. Fernandez de Sevilla*, F. Garcia**, V. Falcó*, J.M. Martinez-Vazquez*

Three cases of idiopathic bronchiolitis obliterans with organizing pneumonia. J. Alegre-Martin, T. Fernandez de Sevilla, F. Garcia, V. Falcó, J.M. Martinez-Vazquez.

ABSTRACT: Three patients with bronchiolitis obliterans organizing pneumonia are described. Chest X-ray films showed peripheral densities and pulmonary function tests a restrictive pattern. In all three cases transbronchial biopsy was not useful for diagnosis and we point out the importance of an open lung biopsy in order to make the differential diagnosis with other infiltrative lung disease with a different prognosis and therapy.

Eur Respir J, 1991, 4, 902-904.

Depts of *Internal Medicine and **Pathology, Hospital General Valle Hebrón and Medical School, Universidad Autonoma, Barcelona, Spain.

Correspondence: J. Alegre-Martin, c/Juan de Garay 19-21 3º 1ª 08026 Barcelona, Spain.

Keywords: Idiopathic bronchiolitis obliterans; organizing pneumonia.

Received: April 18, 1990; accepted after revision March 27, 1991.

Bronchiolitis obliterans with organizing pneumonia (BOOP) is defined by the presence of masses of organizing granulation tissue in the bronchiolar lumen with obliteration of alveolar spaces. It is caused by a diversity of agents and may be associated with a number of different diseases [1]. The idiopathic form is a relatively rare disease, although the clinical and histological patterns are well characterized, that has a good response to therapy with steroids [2, 3].

We describe three patients which were diagnosed as having bronchiolitis obliterans with organizing pneumonia by open lung biopsy.

Case reports

Case 1

A 68 yr old male with one pack-day of smoking was in good health until two months earlier when he developed asthenia, anorexia and weight loss. He was referred to our hospital for evaluation. Physical examination was normal. Chest X-ray film disclosed an alveolar consolidation with signs of atelectasis in the right upper lobe. The erythrocyte sedimentation rate was 66 mm p·h⁻¹. The white cell count was normal. Immunological and bacteriological studies were negative. Spirometry revealed a moderate restrictive pattern. In the bronchoalveolar lavage of the right upper lobe, guided by chest X-ray, there were 26% macrophages, 57% lymphocytes and 18% neutrophils. Transbronchial biopsy of the right upper lobe showed only hyperplasia of alveolar cells. During the next days fever and dyspnoea developed and subsequent X-ray film showed new alveolar densities. An open lung biopsy was performed and disclosed bronchiolitis obliterans with organizing pneumonia (figs 1A and B). The patient was treated

with methylprednisolone with a good clinical and radiological response. Eight months after discharge he is asymptomatic.

Case 2

A 49 yr old male with one pack-day of smoking was admitted to hospital because of fever, cough with purulent sputum, chest pain and dyspnoea since twelve days before. On examination the patient appeared acutely ill. The temperature was 39°C. Crackles and ronchi were heard in the right lung. X-ray film of the chest revealed alveolar opacities in both lower lobes. Laboratory studies showed normal levels of serum electrolytes and chemical values. The erythrocyte sedimentation rate was 138 mm·hr⁻¹. A normocytic-normochromic anaemia with negative direct Coomb's test was detected. All bacteriological and immunological studies were normal, and sputum cytologies were negative. Spirometry revealed a moderate restrictive pattern. In the bronchoalveolar lavage of the right lower lobe there were 93% macrophages, 6.1% lymphocytes and 0.8% neutrophils. Transbronchial biopsy of the right lower lobe disclosed normal lung tissue. Because of worsening of the patient an open lung biopsy was performed and the histological analysis revealed a bronchiolitis obliterans with organizing pneumonia. Steroid therapy was started and the clinical and radiological response was successful.

Case 3

A 65 yr old male with one pack-day of smoking was referred to the hospital because of asthenia, anorexia, weight loss and blood-streaked sputum. Physical examination was normal. Laboratory studies showed a normocytic-normochromic anaemia with

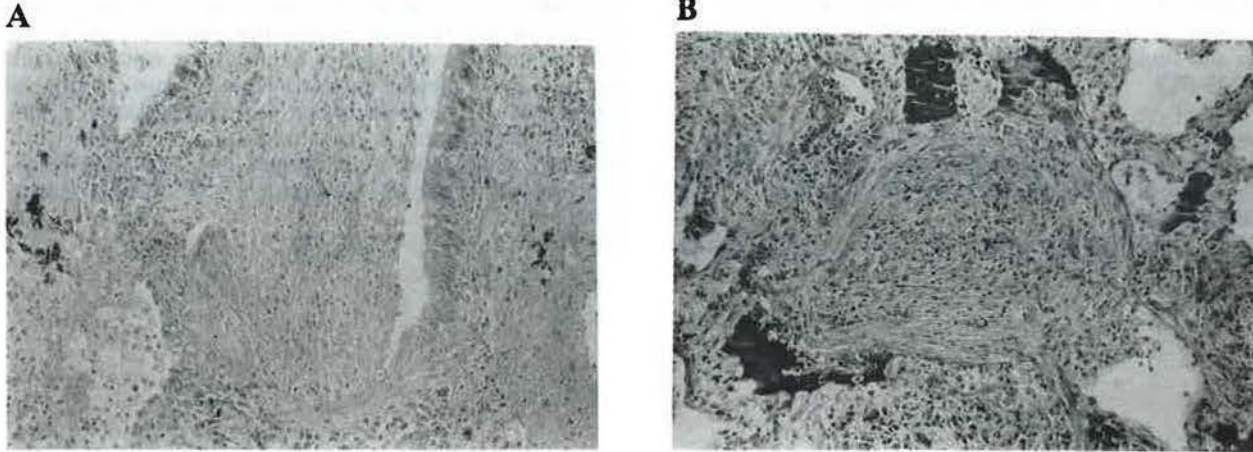


Fig. 1. - Granulation-tissue organization of inflammatory exudate extending from bronchiolus (A), into alveolar ducts and alveoli (B), lung biopsies from case 1. (Haematoxylin-eosin; original magnification $\times 32$).

negative direct Coomb's test. The erythrocyte sedimentation rate was $125 \text{ mm}\cdot\text{hr}^{-1}$. Chest X-ray film revealed an opacity in the left upper lobe with cavitation. All bacteriological and immunological studies and sputum cytologies were normal. Spirometry disclosed a restrictive pattern. In the bronchoalveolar lavage of the left upper lobe there were 92% macrophages, 4.3% lymphocytes and 2.5% neutrophils. Transbronchial biopsy of the left upper lobe disclosed normal lung tissue. During the next days new opacities appeared in the X-ray film; an open lung biopsy was performed, and the histologic study showed bronchiolitis obliterans with organizing pneumonia. The most conspicuous cells were foamy macrophages occupying free alveolar airspaces and some neutrophils, eosinophils and lymphocytes were occasionally found within the lumen of airspaces. The response with steroid therapy was satisfactory with chest roentgenograms returning to normal or nearly normal.

Discussion

The spectrum of aetiological factors associated with bronchiolitis obliterans includes a number of different causes such as fume exposures, infections [4], connective tissue disorders [5] and also the idiopathic form with organizing pneumonia [2]. There is not a characteristic clinical picture of bronchiolitis obliterans with organizing pneumonia, but most patients have a history of cough, dyspnoea and constitutional symptoms [6]. Chest X-ray films show patchy alveolar densities. Pulmonary function tests disclose a restrictive pattern [7]. Often the transbronchial biopsies are not useful for diagnosis, although recently BARTTER *et al.* [8] report three cases diagnosed using this method. The histological study obtained by open lung biopsy shows polypoid formations of granulation tissue in the bronchiolar lumen and the alveoli. Usually the response to steroid therapy is satisfactory.

Our patients had findings that were consistent with these disease. We would point out the lymphocyte

predominance in the bronchoalveolar lavage in the first patient, the normocytic-normochromic anaemia with an excellent response to steroid therapy in cases 2 and 3 and also the presence of cavitation in the X-ray film of the third patient, which is exceptional in this disease [2].

Bronchiolitis obliterans with organizing pneumonia must be differentiated from other infiltrative lung diseases such as classic bronchiolitis obliterans, chronic eosinophilic pneumonia and cryptogenic fibrosing alveolitis [9]. This diagnostic distinction is important because patients with bronchiolitis obliterans have a very good response to steroid therapy, that is why we think that an open lung biopsy must be performed when there is a suspicion of this disease.

References

1. Gosink BB, Friedman PJ, Liebow AA. - Bronchiolitis obliterans. Roentgenologic-pathologic correlation. *AJR*, 1973, 117, 816-832.
2. Epler GR, Colby TV, McLound TC, Carrington CB, Gaensler EA. - Bronchiolitis obliterans organizing pneumonia. *N Engl J Med*, 1985, 312, 152-158.
3. Cordier JF, Loire R, Brune J. - Idiopathic bronchiolitis organizing pneumonia. Definition of characteristic clinical profiles in a series of 16 patients. *Chest*, 198, 96, 999-1004.
4. Sato P, Maotes DK, Thorning D, Albert RK. - Bronchiolitis obliterans caused by *Legionella pneumophila*. *Chest*, 1985, 87, 840-842.
5. Epler GR, Colby TV. - The spectrum of bronchiolitis obliterans. *Chest*, 1983, 2, 161-162.
6. Davison AG, Heard BE, MacAllister WAC, Turner-Warwick MEH. - Cryptogenic organizing pneumonitis. *Q J Med*, 1983, 52, 382-394.
7. Segger JS, Masson UG, Worther S, Stanford RE, Fernández E. - Bronchiolitis obliterans: report of three cases with detailed physiologic studies. *Chest*, 1983, 83, 169-174.
8. Barter T, Irwin RS, Nash G, Balikian JP, Hollingsworth HH. - Idiopathic bronchiolitis obliterans organizing pneumonia with peripheral infiltrates on chest roentgenogram. *Arch Intern Med*, 1989, 149, 273-279.

9. Guerry-Force ML, Müller NL, Wright JL, *et al.* – A comparison of bronchiolitis obliterans with organizing pneumonia and small airways disease. *Am Rev Respir Dis*, 1987, 135, 705–712.

Observation clinique. Trois cas de bronchiolite oblitérante idiopathique avec pneumonie fibrosante. J. Alegre-Martin, T. Fernandez de Sevilla, F. Garcia, V. Falco, J.M. Martinez-Vasquez.

RÉSUMÉ: Nous décrivons trois observations de bronchiolite

oblitérante avec pneumonie fibrosante. Les clichés thoraciques ont montré des opacités pulmonaires périphériques, et les tests fonctionnels pulmonaires un syndrome restrictif. Dans les trois cas, la biopsie transbronchique n'a pas été utile au diagnostic, et nous insistons sur l'importance d'une biopsie pulmonaire à ciel ouvert pour permettre un diagnostic différentiel avec d'autres maladies pulmonaires infiltratives ayant un pronostic et une thérapeutique différents.

Eur Respir J., 1991, 4, 902–904.