

Pain in scar as an early symptom of acquired thoracic lung hernia

J.C.E. Meek*, E. Bollen**, J. Koudstaal†, C. Versteeg††, F.P.V. Maesen*

Pain in scar as an early symptom of acquired thoracic lung hernia. J.C.E. Meek, E. Bollen, J. Koudstaal, C. Versteeg, F.P.V. Maesen.

ABSTRACT: Hernia of the lung manifests itself as an elastic, usually replaceable, swelling in the chest wall, which changes in size during inspiration and expiration. It does not generally cause any symptoms. We describe the case history of a 49 yr old man with an acquired thoracic lung hernia, which had first presented three years previously as pain in an operation scar during coughing and lifting. Histopathology of the excised lung tissue showed abnormalities suggestive of previous episodes of strangulation.

Eur Respir J., 1991, 4, 505-507.

Depts of * Chest Diseases, ** Surgery, † Pathology, and †† Radiology.

Correspondence: Dr F.P.V. Maesen, Dept of Chest Diseases, De Wever Ziekenhuis, H. Dunantstraat 5, Heerlen, The Netherlands.

Keywords: Computer tomography; herniation; lungs; thoracotomy.

Received: October 26, 1990.

Hernia of the lung, first described in 1499 by ROLAND [1], has been defined by MAURER and BLADES [2] as "a protrusion of lung covered with pleura outside its normal boundaries through an abnormal opening in the thoracic cage". If the herniated lung is not covered with pleura, this is termed "prolapse of the lung". MOREL-LAVALLEÉ [3], divided the hernias of the lung both according to their localization (into cervical, thoracic and diaphragmatic hernias) and according to their aetiology. By this method they were classified as congenital or acquired and the latter group was further subdivided into traumatic (secondary to thoracic trauma), spontaneous (occurring at a weak point in the thoracic wall) and pathological (mostly after abscesses in the chest wall or breast, empyema or destruction of the ribs from tuberculosis or malignant tumours).

Congenital hernias of the lung are rare and approximately 80% of the lung hernias which have been described were found to be acquired [4]. Approximately 50% of the total number in the literature were thoracic hernias, mostly following penetrating wounds of the chest, and there was usually a fracture or bruising of the rib in the history or a scar remaining from a drainage procedure [5]. Furthermore, the post-thoracotomy lung hernia is also included in this group [6] but nowhere in the literature are exact data to be found concerning this last type of hernia.

We describe a 52 yr old male patient with a hernia of the lung which showed three years after a left thoracotomy. However, the first symptom, severe pain in the scar radiating out to the shoulder on that side, particularly on coughing and exertion, developed shortly after the operation.

Case history

A 49 yr old factory worker, who had previously worked for 20 yrs underground in the coal mines, underwent a left-sided, posterolateral thoracotomy on 21 June 1986 because of a hamartoma in the laterobasal segment of the left lower lobe. The tumour, which had a diameter of approximately 1 cm, was removed by means of a wedge excision, and the immediate post-operative progress was normal.

Several months later, the patient began to complain of pain in and on the operation scar, particularly during coughing, exertion and lifting. On 1 May 1989, thus three years after the operation, when the patient came back for the annual control in the out-patient clinic of the Department of Respiratory Diseases, a swelling of the size of a chicken egg had developed on the left side of the chest behind the pectoralis major muscle and at the level of the anterior axillary line in the operation scar. The swelling was elastic in nature and increased in size by pressure during coughing and lifting. It also showed crepitations when squeezed. The Valsalva manoeuvre caused pain at the site of the swelling, radiating to the left shoulder blade. After repositioning of the swelling in the chest cavity, a hernial orifice several centimetres in diameter could be felt between the two ribs. At this point, the pain disappeared, and an oblique chest X-ray (fig. 1) showed the picture of a thoracic lung hernia with lung tissue that had found a way between the ribs and presented as an egg-shaped zone of clearing in the subcutaneous tissues. Computer tomography (CT) of the chest (fig. 2 A and B) showed a small defect in the anterior thoracic wall. In the defect,

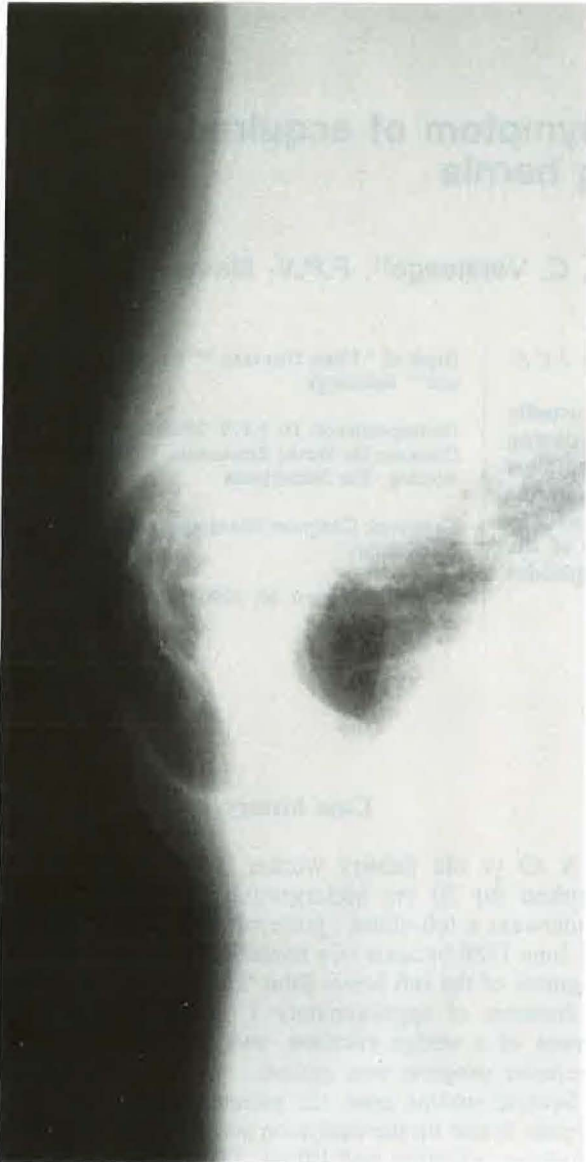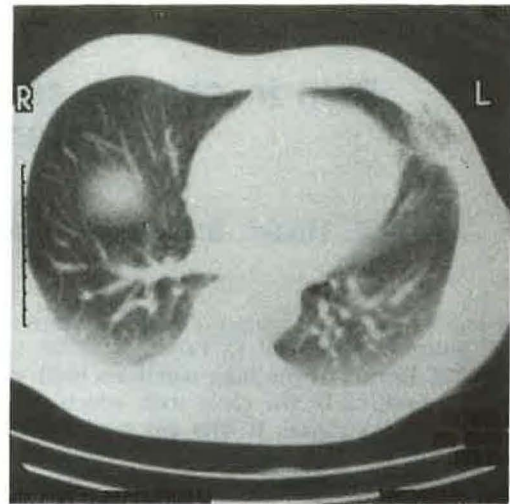


Fig. 1. - Oblique chest X-ray showing the thoracic lung hernia.

the Hounsfield-Units in expiration were higher than those of the remaining lung tissue. On maximal inspiration the wall defect became greater and the Hounsfield-Units values fell; one might conclude from this that the tissue then became better aerated.

The hernia was treated operatively on 27 September 1989. An oblique incision was made over the swelling and the subcutaneous lung tissue was exposed. A defect measuring 2×5 cm was found between the 5th and 6th ribs on the anterior axillary line. The contents of the hernia consisted of a lip of the lingula which did not appear normal. The abnormal piece of lung tissue ($6 \times 4 \times 2$ cm) was removed surgically. Because the defect in the chest wall could not be closed easily by approximating the two ribs, the gap was closed with a double layer of Vicryl net over which the skin was sutured.

A



B

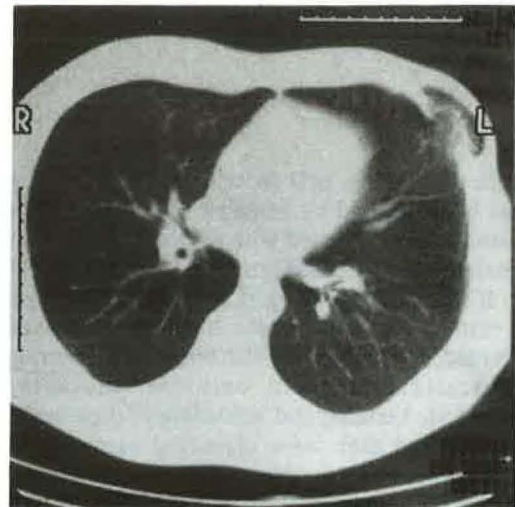


Fig. 2. - CT of the chest. A: expiration (CT level 104). B: inspiration (CT level 110). CT: computed tomography.

The excised lung tissue consisted of partly collapsed lung parenchyma with a rather severe chronic inflammatory change typified by partial bronchiolization of the alveoli, interstitial inflammation with granuloma formation and giant cell production (fig. 3). There was no necrosis and no refractive material. Auramine staining for acid-fast bacilli was negative. Staining for iron showed visible alveolar macrophages containing pigment, whereas in the interstitium histiocytic cell groups were present. These were also laden with considerable amounts of iron pigment, suggesting previous small haemorrhages. Furthermore, there was evidence of previous disturbances in the circulation which would fit with an occasional episode of strangulation. The granulomatous inflammation was probably in connection with the previous surgical intervention.

The post-operative progress was uneventful and the patient's pain complaints did not recur.

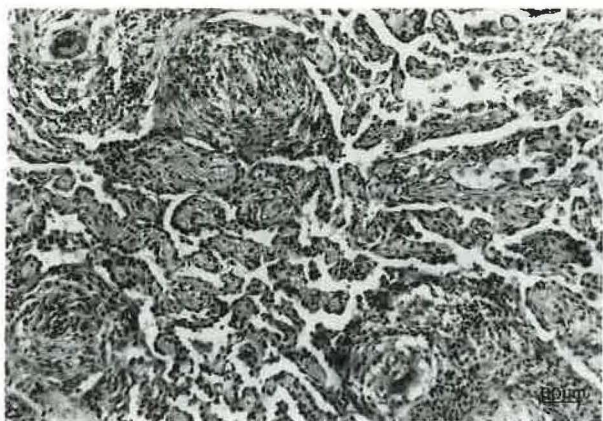


Fig. 3. - Partial bronchiolization of alveoli with formation of granulomata (haematoxylin eosin stain, 125x, bar equals 60 μ m).

Discussion

Thoracic wall lung hernia presents as a soft, crepitating elastic-feeling mass on the chest wall and its dimensions change according to inspiration and expiration. The hernia can usually be replaced through the orifice in the chest wall [2]. Incarceration and strangulation of the hernia are always possible but occur only rarely in practice [7], but there is a strict indication for operation [8]. The diagnosis is quite easy to make on physical examination and by performing the Valsalva manoeuvres. Coughing or pushing the muscles together appear to make the swelling increase so that the differential diagnosis from subcutaneous emphysema, empyema, benign tumour of the chest and destruction of a rib from tuberculosis or carcinoma is relatively simple.

Radiological investigation, both as screening and as oblique chest X-rays, show the herniated lung to increase in volume on pressure. Furthermore, the CT of the thorax illustrates the size of the hernial orifice which is important for the surgeon. Moreover, it gives extra information on the quality of the herniated parts of the lung [9, 10].

Congenital thoracic wall lung hernia is found at the place of least resistance in the thoracic wall and is usually situated along the vertebral column or, more frequently, along the edge of the sternum. These parts of the chest wall are not near the strong muscular masses of the back or the pectoral muscles of the anterior chest wall, and are only covered with the internal and external intercostal membranes.

In contrast, traumatic and secondary variants of the thoracic lung hernia find their way *via* a scar and are often associated with loss of bone, intercostal muscle or fascia. In general, thoracic lung hernias do not give rise to subjective complaints, according to the literature. In the present patient this was certainly not true: more

than two years before the hernia manifested itself externally he had pain in the scar, radiating to the left shoulder on pressure, coughing and lifting. When the hernial orifice was opened the point of the lingula did not appear normal and had to be amputated because of suspicion of strangulation, a suspicion which was subsequently confirmed histologically.

Considering that the resected tissue from the lingula was surrounded by a thick layer of pleura derived from both the visceral and the parietal layers and contained fat from the parietal component, we have to accept that there was a true lung hernia rather than a prolapse.

What is the explanation for the complaints of pain? Because lung tissue itself has no pain fibres, it is unlikely that strangulation of the lung was the direct cause. The intermittent nature of the pain and its relation to the increase in the size of the swelling with increasing intrathoracic pressure, plead against intercostal nerve pain. Traction of pleura adherent to unhealthy lung tissue in the region of the hernial orifice seems a more likely explanation.

References

1. Roland. - De Pulmonis sanaripot., Liber III (Cap) XXV, *In: de Chavliae, Guy, Cyrugia*, 1499, p. 144.
2. Maurer E, Blades B. - Hernia of the lung. *J Thorac Surg*, 1946, 15, 77-98.
3. Morel-Lavallée A. - Hernies du poumon. *Bull Mém Soc Chir Paris*, 1845, 1, 75-195.
4. Montgomery JG, Lutz H. - Hernia of the lung. *Ann Surg*, 1925, 82, 220-231.
5. Bhalla M, Leitman BS, Forcade C, Stern E, Naidich DP, McCauley DI. - Lung hernia: radiographic features. *Am J Radiol*, 1990, 154, 51-53.
6. Noyez L, Munting JDR, Gruwez JA. - Longhernia of pneumonocele. *Acta Chir Belg*, 1983, 20-25.
7. Lillenthal H. - *In: Thoracic Surgery*, vol. 1. W.B. Saunders Co., Philadelphia, 1926, p. 561.
8. Goodman HI. - Hernia of the lung. *J Thorac Surg*, 1933, 2, 368-379.
9. Seibel DG, Hopper KD, Ghaed N. - Mammographic and CT detection of extrathoracic lung herniation. *J Comp Assisted Tomogr*, 1987, 11, 537-538.
10. Dekoster J, Ectors P, Bertrand Ph, Jaspar N, Bosmans J, Sergysels R. - Hernie pulmonaire pariétale post-traumatique. *Rev Fr Mal Respir*, 1988, 5, 151-152.

Doleur au niveau de la cicatrice comme symptôme précoce d'une hernie pulmonaire transthoracique acquise. J.C.E. Meek, E. Bollen, J. Koudstaal, C. Versteeg, F.P.V. Maesen.
 RÉSUMÉ: La hernie du poumon se manifeste sous forme d'un gonflement de la paroi thoracique, élastique, et habituellement réductible, qui modifie son volume au cours de l'inspiration et de l'expiration. En général, elle ne provoque aucun symptôme. Nous décrivons l'observation d'un homme de 49 ans, atteint d'une hernie pulmonaire transthoracique acquise, qui s'était présentée 3 ans auparavant sous forme d'une douleur au niveau de la cicatrice opératoire pendant la toux et les efforts de soulèvement. L'examen histopathologique du tissu pulmonaire réséqué a montré des anomalies suggestives d'épisodes antérieurs d'étranglement.
Eur Respir J., 1991, 4, 505-507.