

Inhalation of the propeller from a spinhaler

R. Polosa, J.P. Finnerty

Inhalation of the propeller from a spinhaler. R. Polosa, J.P. Finnerty.

ABSTRACT: A 39 yr old man with a 5 yr history of asthma opened his spinhaler to inspect it. He sucked at the capsule to see if its contents were damp. The capsule and propeller came off the spindle, and he aspirated them. He attended a casualty department. The chest radiogram was normal. Over the next three months he developed dyspnoea and pain in his chest. He also noticed a whistling noise from his chest, more marked when he lay on his right side. On renewed examination, expiration was prolonged over the right side of the chest, and an occasional whistling wheeze could be heard on that side. A renewed chest radiogram was normal. By means of rigid bronchoscopy, the spindle was removed from its lodged position in the right intermediary bronchus just beyond the orifice to the right upper lobe.

Eur Respir J., 1991, 4, 236-237.

Dept of Medicine I, Southampton General Hospital, Southampton.

Correspondence: R. Polosa, Medicine 1, Level D, Centre Block, Southampton General Hospital, Tremona Road, Southampton, SO9 4XY, UK.

Keywords: Aspiration; inhaler propeller.

Received: July 2, 1990; accepted after revision August 27, 1990.

Spinhalers are widely used to administer disodium cromoglycate (Intal) both alone and in combination with isoprenaline sulphate (Intal Compound).

We report a case of inhalation of the propeller from a spinhaler in a male adult asthmatic.

prescribed by his general practitioner and he was referred to our chest clinic.

Case report

A 39 yr old male tanker driver had a 5 yr history of asthma well controlled on Intal Compound one capsule four times daily delivered *via* a spinhaler. In February 1986, after washing the spinhaler, he found he was unable to inhale any powder from it, and opened it to inspect it, exposing the propeller with the perforated capsule inserted in it, lying free on its spindle. He sucked at the capsule to see if its contents were damp. The capsule and propeller came off the spindle and he aspirated them as a single unit (fig. 1).

He immediately experienced a choking feeling and a fit of coughing but was unable to dislodge the foreign body. The feeling of choking resolved, but he remained breathless and had a persistent dull ache in his chest retrosternally.

He attended a casualty department the next morning. There, a chest radiograph was performed, which was normal; he was examined, reassured, and discharged.

Over the next three months he developed dyspnoea on mild exertion, and aching in his chest. He also noticed a whistling noise from his chest, more marked when he lay on his right side. These symptoms showed no improvement after oral steroid therapy and antibiotics

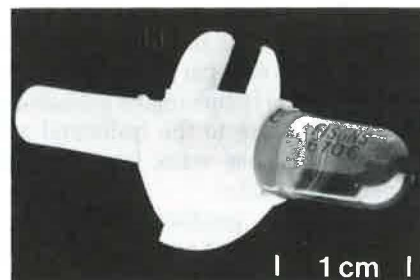


Fig. 1. - Single unit of capsule and propeller from a spinhaler.

On examination, expiration was prolonged over the right side of the chest, and an occasional whistling wheeze could be heard on that side. His chest radiograph was normal. His pulmonary function tests were as follows: forced expiratory volume in one second (FEV₁) 2.83 l (predicted value 5.03 l); forced vital capacity (FVC) 4.77 l (predicted value 5.23 l); and FEV₁/FVC 59% (predicted 75%). No previous values were available for comparison.

Fibreoptic bronchoscopy was immediately arranged, and the spindle was clearly visualized, lodged in the right intermediary bronchus just beyond the orifice to

the right upper lobe bronchus (fig. 2). He was referred for removal of the spindle at rigid bronchoscopy, which was performed without complication; and he was discharged the following day.

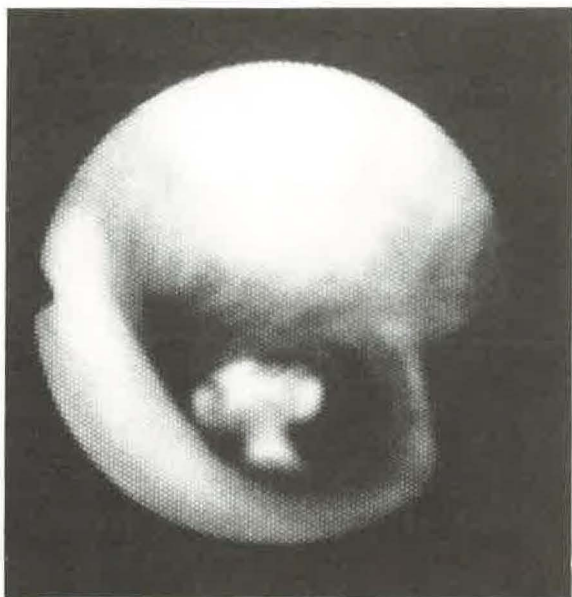

Fig. 2. - Spinhaler propeller lodged in right intermediary bronchus.

Discussion

Disodium cromoglycate is widely used in allergic asthma, and can be administered by pressurized aerosol inhaler or spinhaler. The action of the spinhaler depends on the very light assembly of the (perforated) capsule and propeller spinning rapidly on its spindle when the patient inspires through the device, thus finely

dispersing the contents of the capsule [1]. The propeller is only free to come off its spindle when the spinhaler is opened.

Inhalation of components of the spinhaler is very rare. Cases have been reported of aspiration of the mouth-piece [2] prior to its modification with flanges. The manufacturers, Fisons PLC, have been contacted, and are aware of only two cases such as ours: one in France and one in the USA. To our knowledge, neither case has been reported in the literature. We report the first such case in the United Kingdom.

References

1. Newman PM, Dean DA, Young DM. - Design of powder inhalers. *Practitioner*, 1983, 227, 1773-1777.
2. Quantock DC. - Asthma: spinhaler usage warning (letter). *Br Med J*, 1977, 1, 104.

Inhalation du propulseur d'un Spinhaler. R. Polosa, J.P. Finnerty.

RÉSUMÉ: Un homme âgé de 39 ans, dont l'asthme remonte à 5 ans, a ouvert son Spinhaler pour le contrôler. Il a aspiré la capsule pour vérifier si son contenu était humide. La capsule et le propulseur se détachèrent de leur fixation et pénétrèrent dans ses voies aériennes. Il se rend au service d'urgences. Le cliché thoracique est normal. Au cours des trois mois suivants, il développe de la dyspnée et des douleurs thoraciques. Il remarque également un bruit sifflant d'origine thoracique, plus marqué en décubitus latéral droit. A l'examen de contrôle, l'expiration est prolongée sur l'hémithorax droit, et un sifflement localisé est entendu de ce côté. Un nouveau cliché thoracique est normal. Un bronchoscope rigide a permis de retirer l'objet, qui était situé dans la bronche intermédiaire droite, juste au-delà de l'orifice du lobe supérieur droit. *Eur Respir J.*, 1991, 4, 236-237.