

Unilateral absence of a pulmonary artery: congenital disease or embolic occlusion?

J.M. Arriero, J. Gil, C. Martín, V. Mainar, S. Romero

Unilateral absence of a pulmonary artery: congenital disease or embolic occlusion? J.M. Arriero, J. Gil, C. Martín, V. Mainar, S. Romero.

ABSTRACT: A young man with congenital absence of the left pulmonary artery is reported. A right aortic arch and normal pulmonary pressures essentially rule out an alternate diagnosis of occlusive chronic thrombus in the central pulmonary arteries. Recurrent or massive haemoptysis makes an exact knowledge of the pulmonary circulation advisable.

Eur Respir J., 1991, 4, 1299-1300.

Sección de Neumología, Hospital de Elche, Universidad de Alicante, Alicante, Spain.

Correspondence: J.M. Arriero, Marín, Avenida de Salamanca 34, 6^oI. 03005 Alicante, Spain.

Keywords: Haemoptysis; pulmonary artery; pulmonary embolism.

Received: March 21, 1991; accepted after revision May 28, 1991.

Unilateral absence of a pulmonary artery (UAPA) is a congenital disease which may firstly be seen in adult life. Symptoms usually include haemoptysis, dyspnoea on exertion, or high-altitude pulmonary oedema [1-3]. Thirty percent of patients are asymptomatic at diagnosis. This uncommon condition may share clinical and radiographic features with other entities such as chronic thromboembolic occlusion of a central pulmonary artery [4]. Distinction between both entities is important because of different clinical course, prognosis and treatment.

We report an 18 yr old man with recurrent haemoptysis and unilateral absence of the left pulmonary artery. Angiographic examination confirmed the absence of a pulmonary artery with a right aortic arch. A systemic bronchial branch supplied the left lung. There was no pulmonary hypertension.

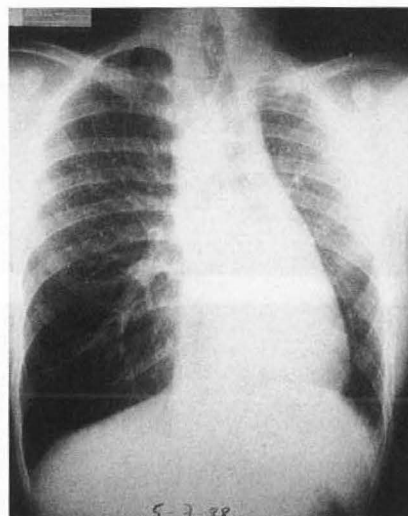
Case report

An 18 yr old man with a two pack-years smoking history was admitted to the hospital because of left thoracic pain and mild haemoptysis. There was no fever, tachypnoea or cyanosis in room air. Pulmonary examination showed diminished breath sounds on the left side.

Routine blood chemistry and urinalysis were normal. A right bundle branch block was seen in the electrocardiogram (ECG).

Chest X-ray films and tomograms (fig. 1A) revealed a small left hemithorax with narrowed intercostal spaces, a prominent main pulmonary artery with no left hilar shadow, an aortic arch to the right and anterior herniation of the right lung to the left. There were some reticular densities near the left hilar zone. No perfusion was seen in the left side on lung scan (fig. 1B). Computed tomographic (CT) scan confirmed

A



B

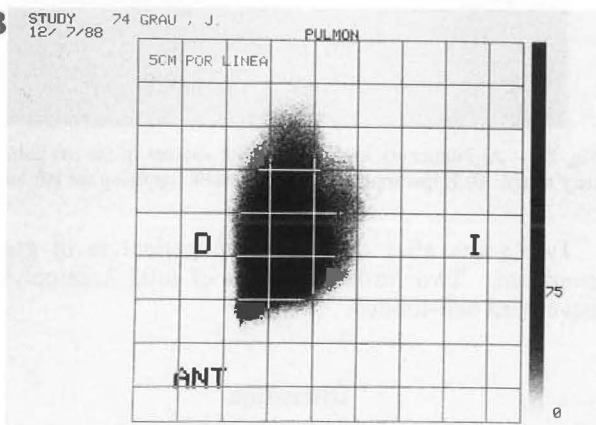


Fig. 1. - A) Posteroanterior (PA) chest X-ray showing typical findings of unilateral absence of a pulmonary artery (UAPA). B) Lung scan revealed no perfusion in the left hemithorax.

a right aortic arch with a right descending aorta, left shifting of the mediastinum and retrocardiac left hilar shadows. An angiographic examination was performed: there was no pulmonary artery on the left side (fig. 2A); pulmonary pressures of 30/12 mmHg were recorded. Aortography demonstrated normal supra-aortic branches with no flow to the left lung. Several hypertrophic vessels from the left bronchial artery supplied blood flow to the left lung (fig. 2B).

Fibreoptic bronchoscopy showed no active bleeding although some clots were seen in the left bronchial tree.

Pulmonary function tests revealed a mild restrictive defect; pulmonary transfer capacity for carbon monoxide (TLCO) was slightly diminished with normal carbon monoxide transfer coefficient (Kco). Arterial blood gases at room air showed: pH 7.41; arterial carbon dioxide tension (P_{aCO_2}) 5.8 kPa; arterial oxygen tension (P_{aO_2}) 13.4 kPa.

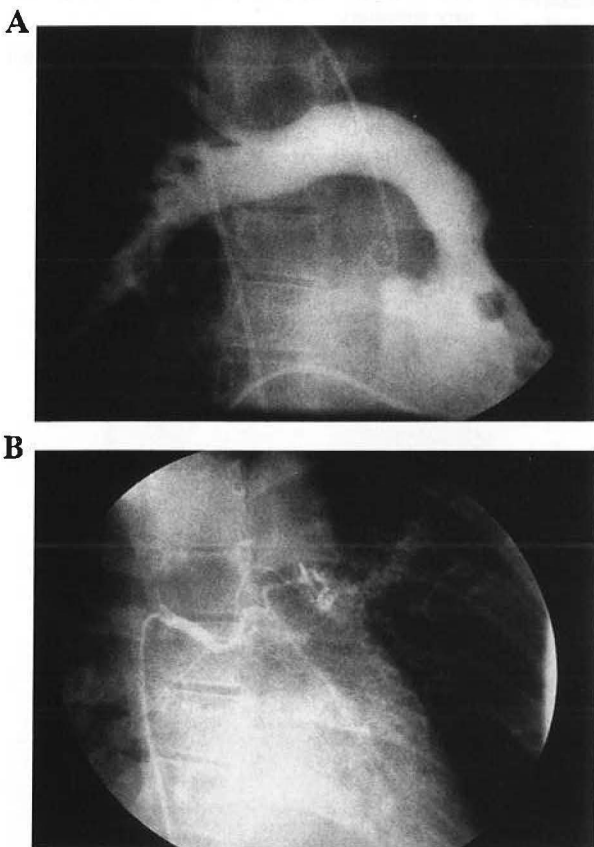


Fig. 2. - A) Pulmonary angiography with absence of the left pulmonary artery. B) Hypertrophic bronchial vessels supplying the left lung.

Two years after discharge the patient is in good condition. Two further episodes of mild haemoptysis have been self-limited.

Discussion

It is generally agreed that the diagnosis of UAPA is based on several distinctive radiographic features with no pulmonary perfusion on lung scan [5].

In a recent report by MOSER *et al.* [4], chronic thromboembolic occlusion was finally shown on surgery in three patients with suspected UAPA. Chest X-ray films, CT scan and pulmonary angiography were unable to distinguish between both entities. On clinical grounds before angiography the authors found a history of deep venous thrombosis and evolutive changes on chest X-ray films and/or lung scan as useful differential clues. The first patient had an absence of the right pulmonary artery. The other two patients had an absent left pulmonary artery with no aortic arch to the right. Severe pulmonary arterial hypertension was demonstrated in every case. We think that, as in our patient, the presence of unilateral absence of the left pulmonary artery with an aortic arch to the right is strongly suggestive of a congenital disease. Moreover, we feel that pulmonary pressures within normal limits would make chronic thromboembolic events improbable.

Hypertrophic systemic vessels, usually bronchial arteries, are the source of bleeding when haemoptysis appears. Abnormal vessels from the descending aorta or its branches, abdominal aorta and even, in one report, from the right coronary artery, have been described [6]. An exact aortographic knowledge of this circulation is essential when recurrent or massive haemoptysis makes embolization of the bleeding vessels necessary and, eventually, pneumonectomy.

References

1. Hackett PH, Creagh CE, Grover RF *et al.* - High-altitude pulmonary edema in persons without the right pulmonary artery. *N Engl J Med*, 1980, 302, 1070-1073.
2. Cogswell TL, Singh S. - Agenesis of the left pulmonary artery as a cause of hemoptysis. *Angiology*, 1986, 37, 154-159.
3. Mehta AC, Livingston DR, Kawalek W, Golish JA, O'Donnell JK. - Pulmonary artery agenesis presenting as massive hemoptysis - a case report. *Angiology*, 1987, 38, 67-71.
4. Moser KM, Olson LK, Schlüsselberg M, Daily PO, Dembitsky WP. - Chronic thromboembolic occlusion in the adult can mimic pulmonary artery agenesis. *Chest*, 1989, 95, 503-508.
5. Levine SJ, White DA, Fels AOS. - An abnormal chest radiograph in a patient with recurring high altitude pulmonary edema. *Chest*, 1988, 94, 627-628.
6. Thompson JA, Lewis SA, Mauck HP. - Absence of the left pulmonary artery: anomalous collateral from the coronary artery to affected lung. *Am Heart J*, 1986, 111, 418-420.

Observation clinique. Absence unilatérale de l'artère pulmonaire: maladie congénitale ou occlusion embolique? J.M. Arriero, J. Gil, C. Martin, V. Mainar, S. Romero.

RÉSUMÉ: Nous présentons un cas d'absence congénitale de l'artère pulmonaire gauche chez un homme jeune. La présence d'un arc aortique à droite et de pressions normales dans l'artère pulmonaire excluent le diagnostic d'occlusion thrombo-embolique chronique des artères pulmonaires centrales. En cas d'apparition d'hémoptysie récurrente ou massive, une connaissance exacte de la circulation pulmonaire est à conseiller.

Eur Respir J., 1991, 4, 1299-1300.