

SERIES "THORACIC IMAGING"
Edited by P.A. Gevenois, A. Bankier and Y. Sibille
Number 2 in this Series

The role of positron emission tomography with ^{18}F -fluoro-2-deoxy-D-glucose in respiratory oncology

J.F. Vansteenkiste*, S.G. Stroobants[#]

The role of positron emission tomography with ^{18}F -fluoro-2-deoxy-D-glucose in respiratory oncology. J.F. Vansteenkiste, S.G. Stroobants. ©ERS Journals Ltd 2001.

ABSTRACT: In the past 5 yrs, positron emission tomography (PET) with ^{18}F -fluoro-2-deoxy-D-glucose (FDG) has become an important imaging modality in lung cancer patients. At this time, the indication of FDG-PET as a complimentary tool to computed tomography in the diagnosis and staging of nonsmall cell lung cancer has gradually gained more widespread acceptance and also reimbursement in many European countries.

This review focuses on the data of FDG-PET in the diagnosis of lung nodules and masses, and in locoregional and extrathoracic staging of nonsmall cell lung cancer. Emphasis is put on the potential clinical implementation of the currently available FDG-PET data. The use of FDG-PET in these indications now needs further validation in large-scale multicentre randomized studies, focusing mainly on treatment outcome parameters, survival and cost-efficacy.

Interesting findings with ^{18}F -fluoro-2-deoxy-D-glucose-positron emission tomography have also been reported for the evaluation of response to radio- or chemotherapy, in radiotherapy planning, recurrence detection and assessment of prognosis. Finally, a whole new field of application of positron emission tomography in molecular biology, using new radiopharmaceuticals, is under extensive investigation.

Eur Respir J 2001; 17: 802–820.

*Respiratory Oncology Unit, Dept of Pulmonology and [#]PET-Centre, Dept of Nuclear Medicine, University Hospital Gasthuisberg, Catholic University Leuven, Belgium.

Correspondence: J.F. Vansteenkiste, Respiratory Oncology Unit, Dept of Pulmonology, University Hospital Gasthuisberg, Herestraat 49, B-3000, Leuven, Belgium.
Fax: 3216346803

Keywords: Decision trees, emission computed tomography, ^{18}F -fluoro-2-deoxy-D-glucose, lung neoplasms, non-small cell lung carcinoma, predictive value of tests

Received: October 12 2000
Accepted after revision January 10 2001

This data was presented in part in the review-of-the-decade lecture at the 2000 Florence meeting of the European Respiratory Society

Lung cancer is the most common cause of cancer-related death in the Western world. Approximately three million new cases per year are estimated worldwide, of which more than 200,000 are in the European Union. An increase in incidence is to be expected until the first decades of the 21st century.

Imaging techniques such as chest radiography, computed tomography (CT), ultrasonography (US), and sometimes magnetic resonance imaging (MRI) are essential in the diagnosis, staging, and follow-up of patients with lung cancer. These imaging tests are based on differences in the structure of tissues, measured by differences in density (for CT), in surface reflectivity (for US), or in chemical environment (for MRI). Although current imaging technology allows exquisite anatomical detail, the density differences often don't allow a definitive diagnosis and staging, and more invasive tests with tissue sampling are required.

Positron emission tomography (PET) has been used over the last decades mainly as a research tool for brain function studies [1, 2] and for the assessment of cardiac metabolism. In the past 5 yrs, it has generated widespread enthusiasm as an innovative imaging technique in oncology, based on its ability to visualize differences in metabolism of tissues.

Lung tumour cells have a much higher rate of glycolysis in comparison with non-neoplastic cells, and an increased cellular uptake of glucose, probably due to an increased expression of glucose transporter proteins [3–6]. FDG, a glucose analogue in which the oxygen molecule in position 2 is replaced by a positron-emitting ^{18}F fluorine, undergoes the same uptake as glucose, but is metabolically trapped and accumulated in the neoplastic cell after phosphorylation by hexokinase (fig. 1) [7–9].

Positron-emitting isotopes such as ^{18}F fluorine have an excess of protons and are, therefore, unstable. They

Previous articles in this series: No. 1: Ghaye B, Dondelinger RF. Imaging guided thoracic interventions. *Eur Respir J* 2001; 17: 507–528.

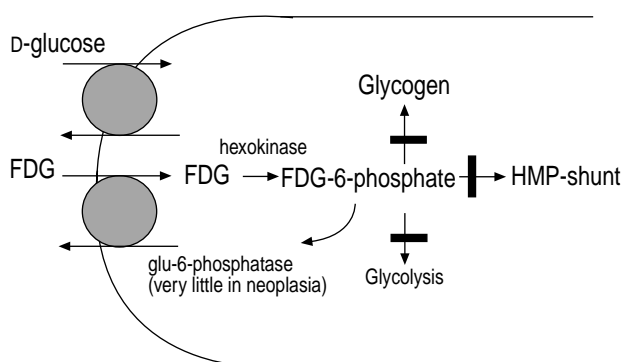


Fig. 1. – Lung tumour cells have an increased uptake of ^{18}F -fluoro-2-deoxy-D-glucose (FDG) and an increased activity of hexokinase generating large amounts of FDG-6-phosphate. This glucose analogue is metabolically trapped and accumulated in the neoplastic cell. HMP: hexose monophosphate pathway.

decay by emission of a positron, which is the subatomic, positively charged, antiparticle of the negatively charged electron. The positron released in this process has kinetic energy, travels a short distance, and then annihilates with an electron. This annihilation creates two 511 keV photons, emitted in opposite directions. The detection of a number of these annihilations by the detector rings of the PET-camera generates high resolution pictures (resolution 5–10 mm) indicating the sites of FDG accumulation in the body [10]. The preferential accumulation of FDG in neoplastic cells permits differentiation between benign and malignant tissue. In this way, FDG-PET compliments the anatomical information on standard imaging with "metabolic" information.

In contrast to the rapidly evolving data on the role of FDG-PET in nonsmall cell lung cancer (NSCLC), there are only a few anecdotal reports dealing with small cell lung cancer [11, 12].

After a short technical note on PET scanning protocols, this review will mainly focus on the current clinical indications of FDG-PET: diagnosis of lung nodules and masses, and staging of NSCLC (table 1). For these indications, there is already reimbursement in several European countries. It continues with a short overview of the studies on other applications in NSCLC, and end with some prospects for the future.

Table 1. – Indications for ^{18}F -fluoro-2-deoxy-D-glucose positron emission tomography (FDG-PET) in respiratory oncology

Current clinical indications
Diagnosis
Evaluation of nodules and masses
Staging
Locoregional staging
Extrathoracic staging
Other applications
Therapy planning
Radiotherapy planning
Therapy monitoring
Response post radiotherapy
Response post (induction) chemotherapy
Follow-up after therapy
Diagnosis of recurrence
Prognosis

Technical note

The behaviour of FDG in normal and neoplastic tissues can be studied with different PET acquisition protocols.

Nonattenuation corrected whole-body images

This is the most commonly used imaging protocol in clinical oncology studies (fig. 2). FDG is injected outside the PET-camera. After an uptake period of ≥ 1 h, necessary to obtain a good tumour to normal tissue contrast, the patient is positioned into the camera. Since the field of view of the PET-camera is only 10–15 cm, different bed positions need to be scanned to obtain a whole-body survey. At the end, the data of the different bed positions are reconstructed to a whole-body image by a computer algorithm, taking into account the physical decay of the FDG tracer during the examination. The advantage of this technique is that it allows a fast acquisition (usually < 45 min) of information of the total body. The disadvantage is that, since no attenuation correction is performed, this technique only generates images for visual interpretation.

Attenuation-corrected images

An important number of the emitted photons are absorbed in the patient's body. This absorption depends on the position in the body (*e.g.* superficial lesions are less attenuated than those situated in deeper layers of the body) and the type of surrounding tissue (*e.g.* lung tissue is less attenuating than muscle tissue). Since the intensity of photon emission of a lesion is position dependent, the intensity seen on the nonattenuation corrected whole-body images (figs. 2 and 3) does not truly reflect the actual FDG-uptake. If the images are corrected for photon attenuation by a so-called transmission scan, which makes an estimate of the attenuating characteristics of the patient, quantification of the FDG-metabolism becomes possible. This transmission scan, which can be performed prior to ("cold transmission") or after ("hot transmission") FDG-injection, will prolong the acquisition time substantially.

In absolute quantification protocols, in which the FDG-uptake can be expressed in $\text{mg}\cdot\text{g}^{-1}$ tissue, certain kinetic models that describe the behaviour of FDG in a tumour cell are used [13]. This quantification, however, requires a dynamic acquisition over the target lesion from the time of injection until a steady-state situation is reached (usually ≥ 1 h) and arterial blood sampling to measure the FDG input function. Since this procedure is time-consuming, rather invasive, and allows imaging in only one camera position (10–15 cm of the patient), its use is limited to more fundamental research studies (*e.g.* functional brain research [14, 15]), and has little application in clinical lung cancer imaging.

The FDG-uptake in most clinical studies is expressed by the standardized uptake value (SUV). The SUV of a lesion is a semiquantitative index of the glucose

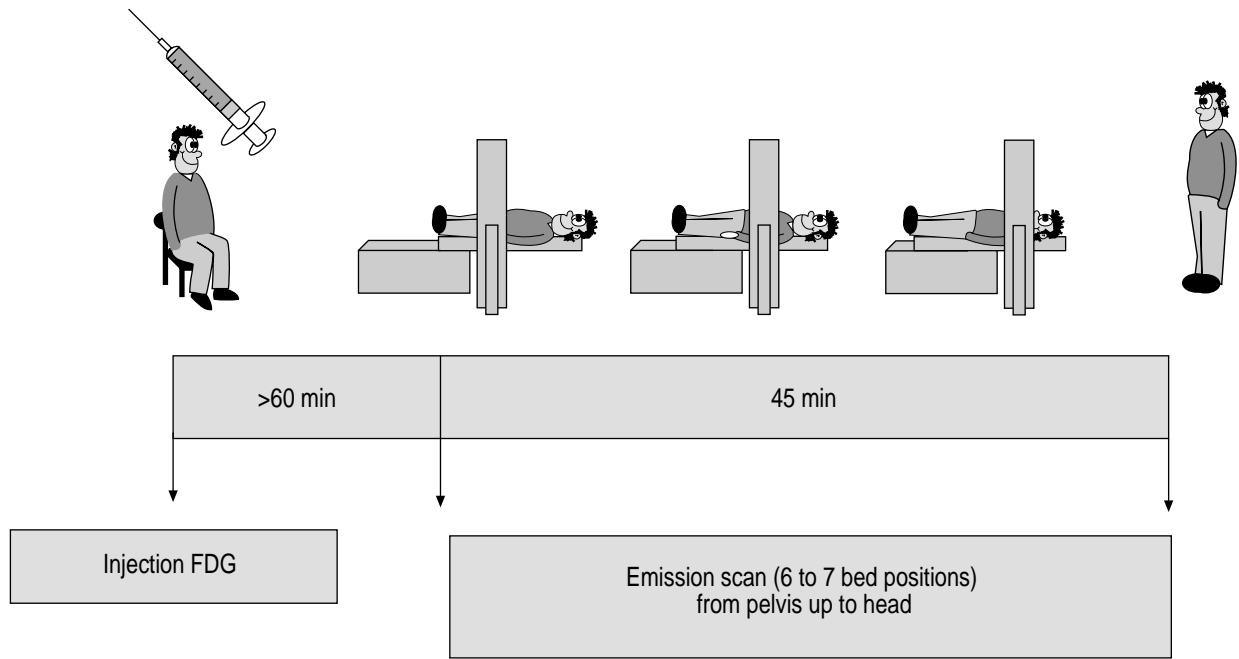


Fig. 2. – Protocol of nonattenuation corrected ¹⁸F-fluoro-2-deoxy-D-glucose positron emission tomography (FDG-PET). Approximately 1 h after injection of FDG, when a more or less stable distribution in the tissues has occurred, a whole-body emission scan is acquired during 6–7 camera positions.

utilization that is obtained by normalizing the accumulation of FDG in the lesion to the injected dose and patient's body weight [16]. Compared to the absolute quantification, no dynamic data are necessary, which allows evaluation of different bed positions and thus a larger field of view in the same image session.

Initially, the transmission scan to correct for photon attenuation could only be performed prior to FDG-injection ("cold transmission", fig. 3). After FDG-injection, the patient had to remain without any movement in the PET-camera for ~1 h, the time needed to obtain a good tumour to normal tissue contrast. Then the acquisition of the emission images, usually limited to two or three bed positions, completed the examination. A total camera time of nearly 3 h was needed for the entire sequence. With the introduction of "hot transmission" *i.e.* acquisition of transmission images after

injection, and alternating with emission images, on the new PET-devices, and the development of new reconstruction methods to decrease transmission time, whole-body attenuation corrected images can now be obtained in a time of 60–80 min (fig. 3) [17, 18].

Dual-head gamma camera coincidence imaging. The conclusions on the use of FDG-PET in respiratory oncology are mainly based on studies with high performance PET-cameras (so-called dedicated PET scanners), characterized by a high resolution and sensitivity. Because of the cost of a dedicated PET-camera, a considerably cheaper alternative has been designed by adding coincidence imaging to a dual-head gamma camera (gamma camera imaging: GCI). The crystals used in the gamma camera, however, have less stopping power for high energy photons compared to the ones used in dedicated systems, which results in a decrease in positron emission detection and, thus, in sensitivity [19].

Some studies have compared GCI with dedicated PET in lung cancer, usually on a limited number of cases, in 23 [20], 27 [21], 28 [22] and 31 patients [23]. Some series suggested that both techniques are equivalent. These series usually included larger lesions visible on both techniques. In a more challenging study, GCI detected 13 (93%) of the 14 lung nodules seen on PET, 20 (65%) of the 31 metastatic mediastinal nodes, and only 27 (42%) of the 64 distant metastases [23]. Another study found an 86% overall accuracy in staging lung cancer with FDG-PET, compared to only 64% with GCI [22]. Present experience suggests that the sensitivity of CGI clearly decreases for lesions smaller than 2 cm. Obviously, this has consequences for the detection of small metastatic deposits in mediastinal nodes or distant sites. One

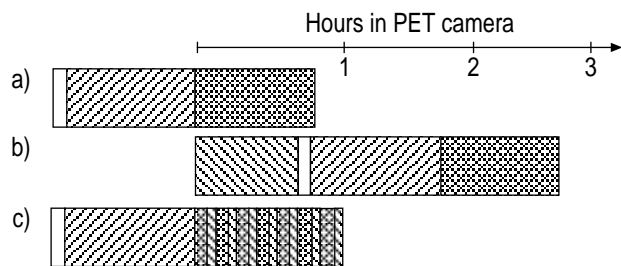


Fig. 3. – a) Nonattenuation corrected protocol as described in fig. 2 (duration 40 min). b) Attenuation corrected protocol with "cold" transmission scan before injection of ¹⁸F-fluoro-2-deoxy-D-glucose (FDG) (duration 150–180 min). c) Attenuation corrected protocol with "hot" transmission scan after injection of FDG (duration 60–80 min). PET: positron emission tomography; □ : FDG injection; ▨ : FDG-uptake phase; ▩ : transmission/bed position; ▩ : emission/bed position.

should thus be very careful in extrapolating the conclusions on clinical decision making obtained with dedicated PET to a situation where GCI is used.

Current clinical indications

Diagnosis of lung nodules and masses

Clinical setting. Central lung tumours can usually be diagnosed by fiberoptic bronchoscopy. Peripheral solitary pulmonary nodules (SPN) often represent a diagnostic challenge, especially if they are noncalcified [24]. Absence of growth over a 2-yr period is highly suggestive of a benign lesion, but often comparative chest radiographs are not available [25]. Bronchoscopic samples taken in patients with a peripheral nodule <3 cm yield a pathological diagnosis in only 20% of the cases [26]. A transthoracic needle aspiration biopsy has a higher diagnostic yield, but can be complicated by a pneumothorax, requiring drainage in 5–10% of procedures [27]. Moreover, the technique is still hampered by the possibility of a false negative test result, which carries the risk of an unacceptable expectation in patients with early-stage lung cancer [28, 29]. Often, more invasive procedures such as thoracoscopy or thoracotomy are needed for a final diagnosis. Consequently, a reliable, noninvasive imaging test, able to differentiate between benign and malignant nodules, could be very useful.

¹⁸F-fluoro-2-deoxy-D-glucose positron emission tomography data. FDG-PET has been studied extensively in the evaluation of indeterminate lung lesions [30–41] (fig. 4). The prospective studies in this indication are listed in table 2. The technique has proven to be

accurate in differentiating benign from malignant lesions as small as 1 cm. In general, there appears to be no significant difference in accuracy when a visual analysis of whole-body images and a semiquantitative approach using a threshold SUV of 2.5 are compared [31, 41, 42]. When data from table 2 are put together, an overall sensitivity of 96% (range 83–100), a specificity of 79% (range 52–100) and an accuracy of 91% (range 86–100) are obtained. The different results of the series can be explained by the prevalence of malignancy in the study population, which is the result of the varying epidemiology of solitary pulmonary lesions in different areas of the world (*e.g.* more histoplasmosis in North-America than in Europe). Another factor is the inclusion criteria of the different series (*e.g.* a lower sensitivity can be expected in series on very small nodules).

A critical mass of metabolically active malignant cells is required for PET diagnosis. Therefore, false negative findings can occur in lesions <10 mm [32, 34, 38, 39, 43], in tumours with low metabolic activity (*e.g.* carcinoid tumours [34, 44]), or in bronchioloalveolar cell carcinoma [43, 45–47]. It should also be mentioned that the sensitivity of FDG-PET is probably slightly less in the lower lung fields, due to respiratory motion. Finally, in small lesions (mostly for lesions <15 mm, depending on the resolution of the PET system) the FDG-uptake is underestimated because of partial volume effects (*i.e.* the activity of the lesion is averaged with the activity of a rim of normal tissue surrounding the lesion).

FDG-uptake is not specific for malignancy, and false positive findings can occur in inflammatory conditions such as bacterial pneumonia [48], pyogenic abscess or aspergillosis, granulomatous diseases such as active

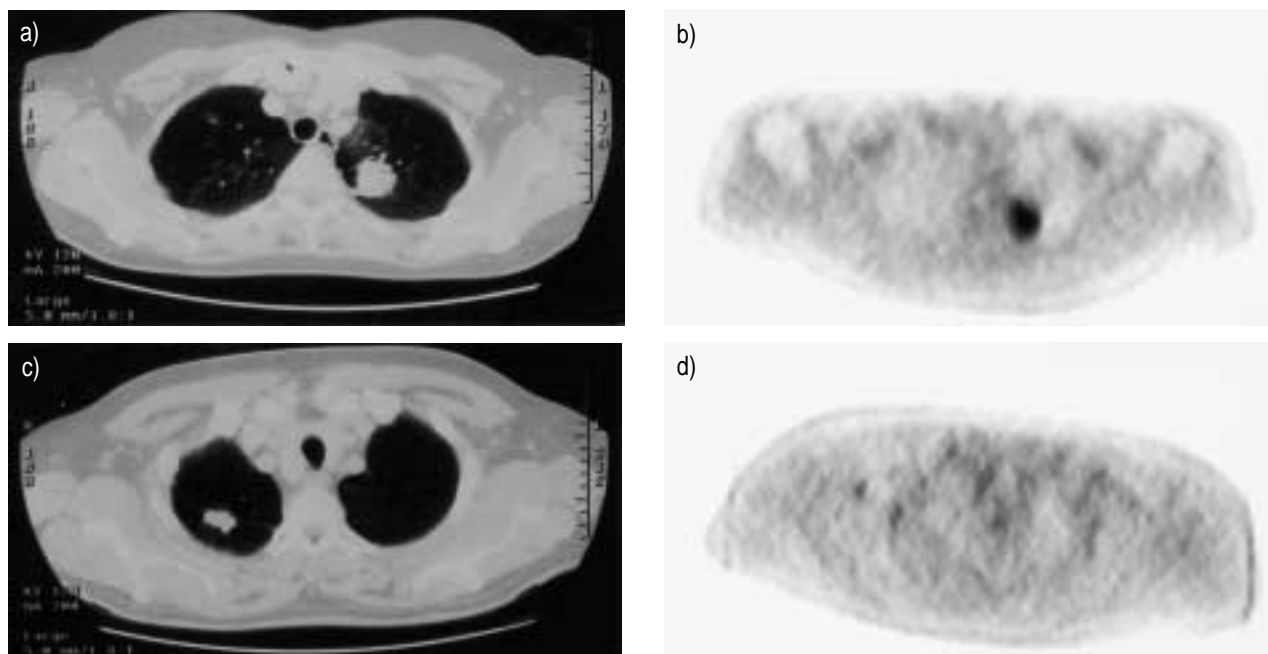


Fig. 4. – a) and b) Suspected coin lesion in the left upper lobe on computed tomography (CT), clearly ¹⁸F-fluoro-2-deoxy-D-glucose (FDG)-positive on positron emission tomography (PET)-images. Peripheral adenocarcinoma at resection. c) and d) Suspected coin lesion in the right upper lobe on CT, unremarkable on PET-images. Necrobiotic nodule at resection.

Table 2. – Prospective series on the use of ^{18}F -fluoro-2-deoxy-D-glucose positron emission tomography (FDG-PET) in the differential diagnosis of lung nodules or masses

First author [Ref.]	Year	n	Method of analysis	Sensitivity %	Specificity %	Accuracy %	Prevalence %
SAZON [30]	1996	107	Visual	100	52	89	77
LOWE [31]	1998	89	Visual	98	69	89	67
			Semiquantitative	92	90	91	
DUHAYLONGSOD [32]	1995	87	Semiquantitative	97	82	92	68
GUPTA [33]	1996	61	Semiquantitative	93	88	92	74
NACKAERTS [34]	1997	52	Semiquantitative	94	82	90	67
PATZ [35]	1993	51	Semiquantitative	89	100	92	65
BURY [36]	1996	50	Visual	100	88	96	66
SLOSMAN [37]	1993	36	Visual	94	60	89	86
DEWAN [38]	1993	30	Visual	95	80	90	67
KUBOTA [39]	1990	22	Semiquantitative	83	90	86	55
GUPTA [40]	1992	20	Semiquantitative	100	100	100	65
GUPTA [41]	1998	19	Visual	100	100	100	63
			Semiquantitative	83	100	89	

Visual: visual interpretation on whole-body images; Semiquantitative: using a threshold of a semiquantitative measure of FDG-uptake (e.g. standardized uptake value); prevalence: proportion of malignant cases in the total group of studied nodules.

sarcoidosis [49], tuberculosis, histoplasmosis, coccidiomycosis, Wegener's disease and coal miner's lung. In these lesions, the FDG-uptake has been attributed to an increase in granulocyte and/or macrophage activity [50].

For some lesions with equivocal findings on whole-body images or with a SUV 2–3, the use of dynamic measurement of FDG-uptake can be of additional benefit [41] to discriminate inflammatory from malignant lesions. The substantially longer scan-time required for these dynamic studies is, however, not justifiable in the clinical routine.

In North-American series, it was shown that FDG-PET reduced the number of patients with an indeterminate SPN undergoing unnecessary resection of a benign lesion by 15%. This resulted in a decrease in cost of US\$1,192 per patient [51, 52]. It is not yet clear whether this cost saving will also be present in Europe. In a Japanese study, the use of FDG-PET was unlikely to be cost-effective, maybe because of the different prevalence of malignancy in patients with a SPN in Japan and the differences in cost of surgical procedures [53].

Clinical application of ^{18}F -fluoro-2-deoxy-D-glucose positron emission tomography. Possibilities and limitations of FDG-PET in the patient with a SPN should be considered. The key question for the clinician is: "below which SUV can an SPN be considered benign and is expectation justified?" Most literature series use the criterion that an SPN with a SUV <2.5 (or with a low uptake on whole-body images) is likely to be benign. With its sensitivity of 96%, FDG-PET will indeed have a very good negative predictive value, and will be able to exclude malignancy correctly in the vast majority of cases. In these patients, a thoracotomy can be avoided, and a repeat chest radiograph or CT scan at 6 or 12 months can be used to confirm the absence of growth.

Difficult situations, where the critical mass of metabolically active malignant cells required for an SUV

>2.5 is not always present, are: 1) Lesions <10 mm; other clinical (age, smoking history) and radiological (spiculation) factors determining the likelihood of malignancy should be considered where a specific CT-study [54, 55], very close follow-up, or more invasive tests can be appropriate. 2) Tumours with low metabolic activity; carcinoid tumours are the most common example, but this tumour usually has a central location, amenable to bronchoscopic biopsy [56]. 3) Bronchioloalveolar cell carcinoma; in most of these cases, other features, especially on CT [57], will be suggestive for the diagnosis, and will point at the scrutiny needed for interpretation of the FDG-PET results. With its specificity of 79%, FDG-PET will also have a good positive predictive value, but not as good as its negative predictive value. A positive scan is possible in the previously listed inflammatory conditions, which should be excluded by appropriate tests in case of clinical suspicion. In case of doubt, lesions with increased FDG-uptake should, however, be considered malignant until proven otherwise, and managed accordingly.

Locoregional staging: primary tumour (T status) and locoregional lymph nodes (N Status)

Clinical setting. Accurate staging is essential to make estimates of prognosis, and to choose the best combination of treatment modalities such as surgery, radiation and chemotherapy, in an attempt to improve survival and optimize the use of imaging resources.

Extension of the primary tumour is usually assessed by thoracic CT, occasionally complemented by MRI, e.g. in situations where superior sulcus extension or relationship with the heart or large vessels is of importance [58]. With their exquisite anatomical detail, modern CT and MRI are the preferred tests to evaluate the T-factor. FDG-PET offers no extras in this respect, due to its limitations in spatial resolution and anatomical detail within the image.

Perhaps even more important for the prognosis is the locoregional lymph node (LN) spread. Patients without malignant LNs in the mediastinum are usually treated with straightforward surgical resection. Patients with diseased mediastinal LNs are candidates for induction chemotherapy up-front, followed by surgery and/or radiotherapy [59–63]. It is therefore of considerable clinical interest to evaluate these mediastinal LNs as accurately as possible.

CT is the most commonly used noninvasive staging method of the mediastinum, but is far from satisfactory and less accurate than invasive surgical staging (ISS) [64–67]. In prospective data from the Radiological Diagnostic Oncology Group, the sensitivity and specificity of thoracic CT were only 52% and 69%, respectively [68]. In the authors' (the University Hospital Gasthuisberg), the best results were obtained when LNs ≥ 1.5 cm at their maximal cross-sectional diameter were considered to be metastatic [69]. Using this criterion, the sensitivity was 69% and the specificity 71%. Given this very moderate level of accuracy of CT, ISS by mediastinoscopy remained, until recently, the only adequate tool for mediastinal LN staging. FDG-PET as a noninvasive tool for determination of LN spread has thus been examined extensively.

¹⁸F-fluoro-2-deoxy-D-glucose positron emission tomography data. An important number of prospective studies have compared the performance of CT and FDG-PET in mediastinal LN staging in potentially operable NSCLC [30, 70–85] (fig. 5). In all but one [82] of these studies, FDG-PET proved to be more accurate than CT. Quite evidently, a recent meta-analysis has confirmed this finding [86]. Additionally, FDG-PET can indicate suspect LNs in stations not amenable to ISS by mediastinoscopy.

Most of the studies have reported the results on a per patient basis, and compared the accuracy of CT and FDG-PET in distinguishing between presence (N2–N3) or absence (N0–N1) of malignant mediastinal LNs (table 3). When the results from table 3 are put together, an overall sensitivity of 89% (range 67–100), a specificity of 92% (range 79–100) and an accuracy of 90% (range 78–100) are obtained for FDG-PET. For CT, the results are a sensitivity of 65% (range 20–86), a specificity of 80% (range 43–90), and an accuracy of 75% (range 52–79). The information in table 3 also shows that studies in which FDG-PET images are interpreted with the aid of CT (complementary) usually have slightly better results than those in which FDG-PET images are read independently. In the two studies, that directly compared these two methods of interpretation, an additional gain in sensitivity was noted: from 67–93% [75] in one, and from 73–82% in the other [77]. This difference is the expression of the fact that the precise anatomic information on CT is complementary to the metabolic information images of FDG-PET, which lack precise anatomical detail. Therefore, the correlative interpretation will help in the distinction between, for example, central tumours and adjacent LNs, or between adjacent LN stations. This difference is of critical importance if the distinction is to be made between hilar and adjacent right tracheobronchial or subaortic nodes, and thus between N1 (operable) and

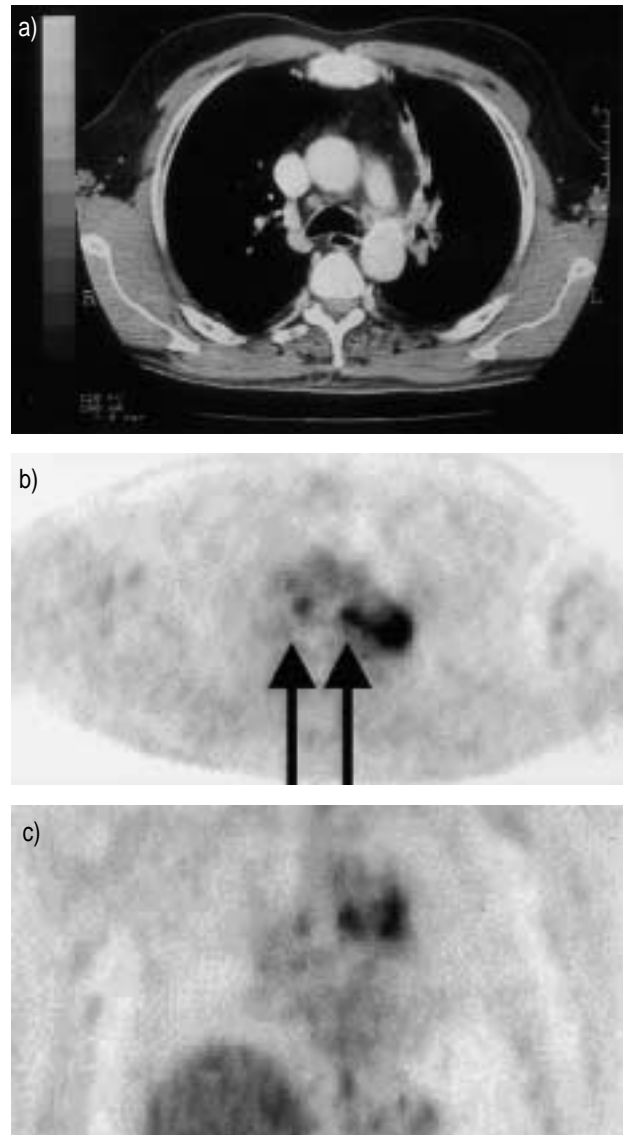


Fig. 5. – a) Computed tomography (CT)-image of a patient with left upper lobe tumour without suspect adenopathy in the mediastinum (N0-disease). b) and c) Transaxial and frontal positron emission tomography (PET)-images suggest N3-disease with left and right paratracheal lymph node metastasis (arrows), which was confirmed at mediastinoscopy.

N2 (nonoperable) disease. A study in the authors' centre addressed the question of whether digitally fused CT and FDG-PET images (so-called anatomometabolic fusion images) could further increase the accuracy of noninvasive LN staging [74]. It was found that, for an experienced reader, the gain in accuracy compared to visual correlation was very small, since the errors due to minimal tumour load (false negatives) or inflammation (false positives) were not corrected.

In one of the authors' studies, it was examined if the use of an SUV threshold for LNs improved the results, compared to simple visual analysis [72]. The best SUV threshold to distinguish benign from malignant LNs was 4.4, but the analysis with the SUV threshold did not prove to be superior to the simple visual reading.

Table 3. – Prospective comparator studies of computed tomography (CT) and ^{18}F -fluoro-2-deoxy-D-glucose positron emission tomography (FDG-PET) in mediastinal lymph node staging in nonsmall cell lung cancer, reporting the results per patient

First author [Ref.]	Year	n	Method of analysis	Sensitivity %	Specificity %	Accuracy %	Prevalence %	p-value
SAUNDERS [70]	1999	84	Independent CT	71 20	97 90	92 77	18	NR
VALK [71]	1995	76	Complementary CT	83 63	94 73	91 70	32	<0.01
VANSTEENKISTE [72]	1998	68	Complementary CT	93 75	95 63	94 68	41	0.0004
KERSTINE [73]	1999	64	Independent CT	70 65	86 79	84 76	25	<0.001
VANSTEENKISTE [74]	1998	56	Fusion images Complementary CT	89 89 86	82 82 43	86 86 64	50	0.04
VANSTEENKISTE [75]	1997	50	Independent Complementary CT	67 93 67	97 97 59	88 96 64	30	0.004
BURY [76]	1996	50	Independent CT	90 72	86 81	NR NR	32	<0.05
WENG [77]	2000	50	Independent Complementary CT	73 82 73	94 96 77	87 91 76	38	0.03
STEINERT [78]	1997	47	Independent CT	92 54	97 88	96 79	28	0.01
PATZ [79]	1995	42	Independent CT	92 58	100 80	95 68	NR	NR
SAZON [30]	1996	32	Complementary CT	100 81	100 56	100 69	50	0.01
CHIN [80]	1995	30	Complementary CT	78 56	81 86	80 77	30	NR
SCOTT [81]	1996	27	Complementary CT	100 67	100 83	100 78	33	0.03
ALBES [82]	1999	24	Independent CT	77 77	79 79	78 74	66	NR
WAHL [83]	1994	19	Independent CT	82 64	81 44	81 52	NR	<0.05

Independent: interpretation of PET without CT; Complementary: interpretation with aid of CT; Fusion images: digital fusion of CT and PET images; prevalence: proportion of cases with diseased mediastinal lymph nodes in the total group of studied patients; p-value: significance of the difference in performance between CT and PET, usually examined with a McNemar test; NR: not reported.

Some studies have reported the results on a per LN station basis, and compared the accuracy of CT and FDG-PET in the detection of metastatic deposits in the different LN stations [72, 74, 78, 79, 81, 84, 85] (table 4). These studies have convincingly demonstrated that the superiority of FDG-PET can be explained by the more frequent correct identification of "small malignant nodes" and "large benign nodes". Indeed, the moderate accuracy of CT in LN staging is explained by the fact that size is a relative criterion. LN can be enlarged due to infectious or inflammatory causes, and small-sized nodes can nonetheless harbour metastases [64, 67–69], resulting in overstaging as well as understaging.

False negative findings can occur when the tumour deposit in the mediastinal nodes is small. In the authors' experience, this was mainly the case in some patients with minimal areas of metastatic cells in LNs with a maximal diameter rarely exceeding 2.5 mm (unpublished data). False positive images are possible in LNs containing anthracosilicosis [36] or inflamma-

tory tissue with high metabolic activity. In some cases, however, no particular pathological abnormalities explaining the false positive FDG image can be found (unpublished data).

Clinical implication of ^{18}F -fluoro-2-deoxy-D-glucose positron emission tomography. How should mediastinal FDG-PET be implemented in clinical practice? In nonmetastatic NSCLC patients, survival results after resection are worthwhile in three groups: 1) those without metastasis in mediastinal lymph nodes at thoracotomy; 2) those with so-called "unforeseen N2" *i.e.* metastasis in ipsilateral mediastinal lymph nodes found at thoracotomy after a negative preoperative mediastinoscopy [87–92] and; 3) those with so-called "minimal N2" detected at mediastinoscopy (according to the International Association for the Study of Lung Cancer [93], minimal N2 is defined as "one positive lower mediastinal nodal station excluding subcarinal adenopathy"). Mediastinoscopy, therefore, plays a central role in the preoperative staging of

Table 4. – Prospective comparator studies of computed tomography (CT) and ^{18}F -fluoro-2-deoxy-D-glucose positron emission tomography (FDG-PET) in mediastinal lymph node staging in nonsmall cell lung cancer, reporting the results per lymph node station

First author [Ref.]	Year	n	Method of analysis	Sensitivity %	Specificity %	Accuracy %	Prevalence %	p-value
VANSTEENKISTE [72]	1998	690	Complementary	89	99	98	7	0.002
			CT	47	96	92		
VANSTEENKISTE [74]	1998	493	Complementary	67	97	93	12	0.002
			Fusion images	67	97	93		
			CT	50	93	87		
BERLANGIERI [84]	1999	201	Independent	80	97	95	10	<0.05
			CT	65	90	87		
STEINERT [78]	1997	191	Independent	89	99	97	25	0.007
			CT	57	94	85		
SCOTT [81]	1996	75	Complementary	100	98	99	13	0.04
			CT	60	94	85		
SASAKI [85]	1996	71	Independent	76	98	93	24	<0.05
			CT	65	87	82		
PATZ [79]	1995	62	Independent	83	82	82	37	NR
			CT	43	85	69		

n: number of studied lymph node stations; Independent: interpretation of PET without CT; Complementary: interpretation with aid of CT; Fusion images: digital fusion of CT and PET images; prevalence: proportion of malignant lymph node stations in the total group of studied lymph node stations; p-value: significance of the difference in performance between CT and PET, usually examined with a McNemar test; NR: not reported.

potentially operable NSCLC: it will be negative in groups 1 and 2, while it will confirm "minimal N2" in group 3. If mediastinoscopy shows "more than minimal N2" or N3 disease, the survival results of direct surgery are marginal [91, 94, 95], mainly due to the development of systemic relapses [96]. These patients will be treated in a multimodality protocol, including induction chemotherapy followed by radiotherapy and/or surgery [59–63].

The issue whether FDG-PET is able to replace mediastinoscopy involves two questions. 1) Is it possible to proceed directly to thoracotomy in the case of a negative mediastinal PET? In the authors' view, yes, since mediastinal PET has a very high negative predictive value in the exclusion of N2 or N3 disease. Occasionally, a patient with a false negative mediastinal PET proceeds to straightforward thoracotomy, but in these cases "minimal N2" is found, where, as already mentioned, a reasonable prognosis after surgical resection can be expected [88]. 2) Can we leave out straightforward thoracotomy in the case of a positive mediastinal PET? In the authors' view, no. Although the positive predictive value in the confirmation of N2 or N3 disease is also high, mediastinoscopy is still advised to prove N2 or N3 disease in patients with positive mediastinal nodes on PET. Mediastinal mapping by mediastinoscopy is justified before the start of a chemotherapy induction protocol, and is needed to ensure that no single patient with N0- or N1-disease is denied the chance of cure by direct surgical resection based on a false positive PET.

Even when only the high negative predictive value of mediastinal PET is implemented, this resulted, in the authors' experience, in nearly a 50% reduction of the number of mediastinoscopies. In the USA, it has been suggested that the use of a combined FDG-PET and CT strategy is more cost-effective than CT alone in the staging of NSCLC [52, 97].

Extrathoracic staging (*M status*)

Clinical setting. The finding of extrathoracic metastases implies that a patient is no longer amenable to long-term remission or cure. Standard staging for extrathoracic disease is based on clinical and biological factors, and imaging tests, such as CT, ultrasound, or bone scintigraphy. Whether these examinations need to be performed in every patient remains controversial. This issue is beyond this review, and the authors only refer to some recent guidelines [98, 99].

Current standard staging is far from perfect. After radical treatment for apparently localized disease, the present authors have found that an important proportion of patients, ranging from 20 [100] to 22% [101, 102], will nonetheless have an early distant relapse. This means that detection of micrometastases that are already present at the time of initial staging is not possible [103]. The most common sites of metastasis are the adrenal glands, bones, brain, and liver [104]. Up to 35–45% of the patients will have detectable distant disease at presentation [105].

^{18}F -fluoro-2-deoxy-D-glucose positron emission tomography data. In the detection of bone metastasis, $^{99\text{m}}\text{Tc}$ -technetium-methylene-diphosphonate ($^{99\text{m}}\text{Tc}$ -MDP) scintigraphy is considered to be the most practical technique for assessing the entire skeleton. It has a reasonable sensitivity of ~90%, but the clinical interpretation is hampered by its low specificity (false positive findings in arthrosis, arthritis, post-traumatic abnormalities, etc.). Often, additional studies such as bone radiographs, bone CT, or bone MRI are needed. One study pointed at an equivalent sensitivity of FDG-PET and $^{99\text{m}}\text{Tc}$ -MDP bone scintigraphy, but with a much higher specificity for FDG-PET (98% versus 61%) [106]. In another series, FDG-PET proved to be more sensitive than $^{99\text{m}}\text{Tc}$ -MDP bone

scintigraphy, and allowed better differentiation between benign and malignant lesions [107]. Whether FDG-PET can replace ^{99m}Tc -MDP bone scintigraphy remains an open question. Studies in breast cancer have indicated false negative FDG-PET findings in bone metastases, especially in osteoblastic lesions [108, 109]. Obviously, more data are needed to answer this question. Another point in this discussion is the fact that a whole-body FDG-PET gives an image from the head to just below the pelvis, while a standard ^{99m}Tc -MDP bone scintigraphy images the entire skeleton.

Adrenal masses are found in up to 20% of NSCLC patients at initial presentation [110–112]. The finding of an isolated adrenal mass on CT is often a diagnostic challenge. About two-thirds of cases could be explained by an asymptomatic adrenal adenoma in some series [110, 113]. An adrenal mass, therefore does not imply inoperable disease, but rather the need for further (pathological) examination by, for example, puncture or biopsy of the lesion [113]. FDG-PET can be a useful adjunct to other imaging modalities of the adrenals. The available (small) series point at a high sensitivity of FDG-PET in the detection of adrenal metastases [114–116]. An equivocal lesion on CT without FDG-uptake on PET will usually not be metastatic. However, it is necessary to be very careful with the interpretation of small lesions. Indeed, the available series have studied lesions with an average diameter of 30 mm. Specificity in the available data lies 80–100%, because some false positive findings have been described [114]. In the case of an isolated FDG-positive adrenal lesion, pathological proof is still required before a decision towards inoperable disease is made.

The evaluation for liver metastasis is usually less difficult because the liver is less frequently an isolated site of disease, and because the combination of ultrasonography and CT can solve most cases [117]. There are no series that specifically focus on the performance of FDG-PET in the evaluation of liver lesions in NSCLC patients. Data from studies on staging of NSCLC in general, suggest that FDG-PET is more accurate than CT in liver staging, mainly because of better specificity [118, 119]. A series on examination of the liver in patients with different primary tumours reported a sensitivity of 97% and a specificity of 88% for FDG-PET, in comparison to 93% and 75%, respectively for CT (a nonsignificant difference) [120]. Similar findings have been reported in studies on colorectal [121, 122], pancreatic [123] or oesophageal tumours [124]. False positive findings have been described in some liver abscesses [125]. The main advantage of FDG-PET is its ability to differentiate hepatic lesions that remain indeterminate by conventional studies: in one study, FDG-PET accurately indicated liver metastases in 11 patients, two with negative and nine with equivocal conventional imaging. On the other hand, FDG-PET could exclude metastasis in four cases with suspect conventional imaging [120].

In the authors' experience, FDG-PET was also of help in some patients in the detection of metastases that otherwise could have escaped notice, for example, small nodules in the other lung, soft tissue lesions, retroperitoneal LNs, hardly palpable supraclavicular

LN's, etc. Finally, FDG-PET also pointed at a coexistent asymptomatic second primary tumour, mainly of colorectal origin.

FDG-PET is not suited for the detection of brain metastasis. The sensitivity of FDG-PET in the detection of brain lesions is low, because the surrounding normal brain tissue has a high glucose uptake. CT and/or MRI remain the standard imaging tests in this indication [126].

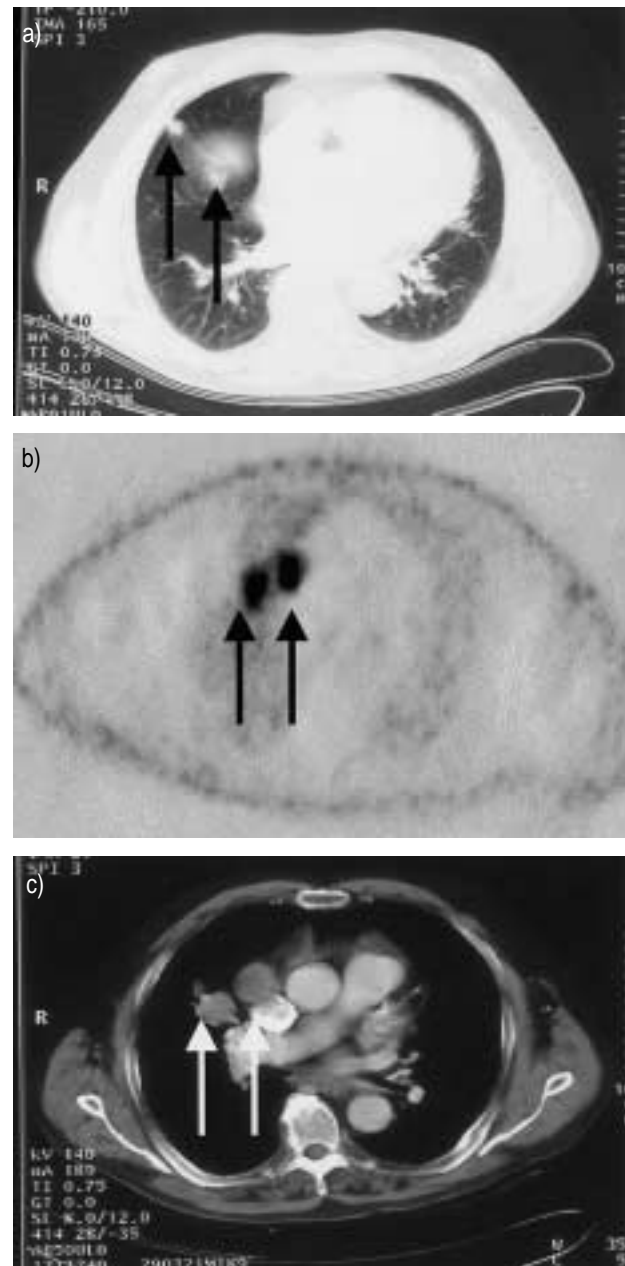


Fig. 6. – Importance of computed tomography-positron emission tomography (CT-PET) correlation. a) Two suspect lesions (arrows) are present in the right lung on CT. b) Two suspect lesions in the right lung (arrows) are withheld on PET-images (N0-disease?). c) Correlation locates one of the ^{18}F -fluoro-2-deoxy-D-glucose (FDG) hot-spots in the largest parenchymal lesion and the other one in a mediastinal node anterior of the superior vena cava (N2-disease). The small peripheral lung nodule does not exhibit FDG-uptake.

Clinical implication of ^{18}F -fluoro-2-deoxy-D-glucose positron emission tomography. Whole-body FDG-PET improves the imaging of metastases for two reasons. 1) It is able to detect metastatic lesions that would have been missed on conventional imaging, or in clinically hidden or difficult areas (bone, liver, soft tissue, some LNs, etc.) (fig. 7). Since most of the organ-specific literature series are still on small numbers of patients and contain some false positive findings, it should be a golden rule to obtain verification by other methods or by tissue sampling of an isolated positive finding that determines resectability. 2) It is able to exclude malignancy in lesions that are equivocal on conventional imaging (fig. 8). Exclusion of malignancy by FDG-PET should be done with caution in case of small lesions, e.g. adrenal nodules of <1 cm.

Because whole-body FDG-PET is able to stage both intra- and extra-thoracic sites in one examination, and because of its greater accuracy than conventional imaging, this technique is reported to change patient management in 19% [119], 20% [118], 30% [71], 31% [127], or even 41% [128] of patients. Numerous data indicate that FDG-PET can complement conventional imaging, but the authors clearly do not have enough data to accept that FDG-PET can replace it. In contrast with the large amount of data on locoregional staging, most of the organ-specific studies are small, and did not include an adequate number of small lesions, which truly challenge the technique. Further studies of this type have to be awaited.

Other applications

Radiotherapy planning. Although most of the FDG-PET studies of locoregional NSCLC staging were performed in a preoperative setting, the use of this technique could be of equivalent importance in radiotherapy planning in nonmetastatic patients not

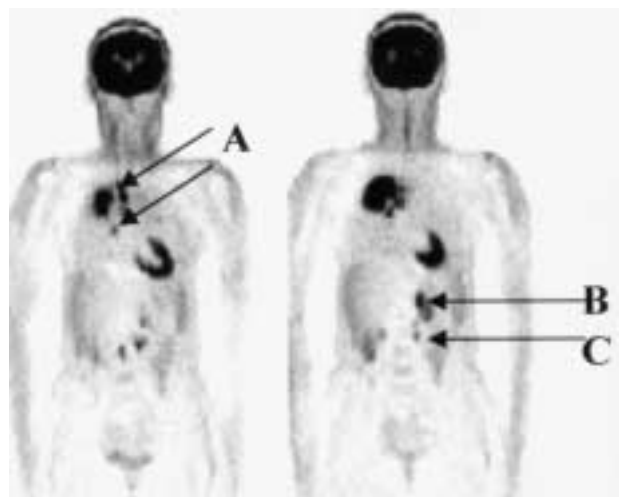


Fig. 7. – Patient referred for induction treatment for presumed stage IIIA-N2 disease. On ^{18}F -fluoro-2-deoxy-D-glucose positron emission tomography (FDG-PET), a) mediastinal lymph node spread is very important, and b) unsuspected left adrenal and c) abdominal lymph node lesions are found.

suitable for surgery e.g. due to cardiopulmonary limitations. The extent of the tumour will not only influence the treatment intention, i.e. curative or palliative, but also the volumes to be treated and therefore the toxicity to be expected. Indeed, several authors have suggested that a dose-volume effect for radiopneumonitis exists [129–132].

Classical radiotherapy planning uses conventional imaging such as chest radiography and CT to describe the tumour and to draw the target volume for

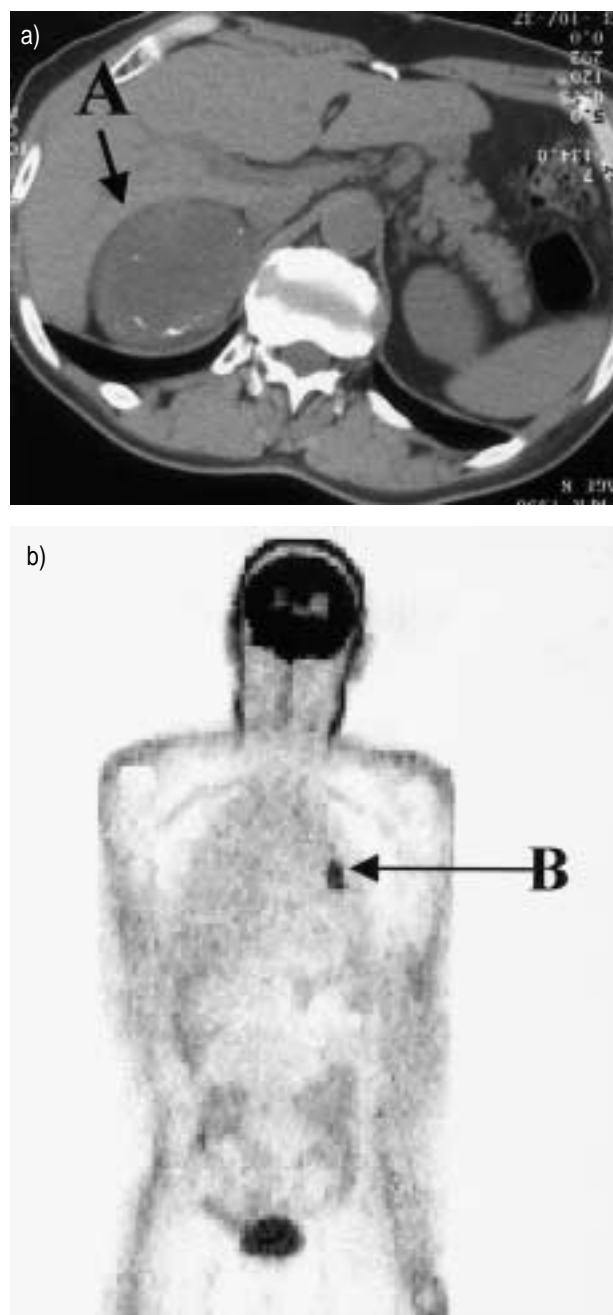


Fig. 8. – a) Patient referred for chemotherapy for presumed T1N0M1 adenocarcinoma (A) with lumbar pain due to adrenal metastasis on computed tomography (CT). b) Positron emission tomography (PET)-images demonstrate ^{18}F -fluoro-2-deoxy-D-glucose (FDG)-uptake in the primary tumour only. Surgical exploration revealed an adrenal adenoma with central bleeding (B).

irradiation. The main limitations of this method are the poor demarcation of some tumours on CT, and the inability of CT to distinguish between benign and malignant LNs. In one study including 20 patients, twelve had poorly demarcated tumours. CT and FDG-PET volumes corresponded in seven patients, but in three of 12 patients, the CT abnormalities were larger than on FDG-PET, and in two of 12 patients the abnormalities on FDG-PET extended outside the region of CT changes [133]. Another study pointed at the substantial reduction in radiation fields by FDG-PET in cases with postobstructive atelectasis [134].

As for the effect of LNs, a simulation study on the potential impact of FDG-PET on the radiation treatment plan of 105 patients with NSCLC was carried out at the authors' centre [135]. For 73 of these patients, with positive LNs on CT and/or on FDG-PET, a theoretical study was performed in which for each patient the gross tumour volume (GTV) was defined based on CT and on PET-CT data. For each GTV, the completeness of tumour coverage was assessed, using the available surgical pathology data as gold standard. Tumour coverage improved from 75% when the CT-GTV was used, to 89% with the PET-GTV ($p=0.0005$). In 45 patients (62%) the information obtained from FDG-PET would have led to a change of the treatment volumes. It was concluded that assessment of locoregional LNs by FDG-PET improved tumour coverage. In selected patients, it also reduced the volume of normal tissues irradiated, and thus toxicity, opening possibilities for treatment intensification. Similar findings were reported in smaller studies [134, 136, 137]. Future prospective comparative studies are indicated to examine whether these advantages of combined CT-PET planning will actually result in reduced toxicity, better local control, and increased survival.

Response evaluation postradiotherapy. Response after radiotherapy is usually evaluated by comparing tumour volumes on chest radiographs or CT images pre- and post-therapy. An important limitation of this method lies in the fact that changes in tumour viability (and thus prognosis) do not necessarily correlate with changes in volume. Data on the possible extra value of FDG-PET in NSCLC in this setting are still limited. In one study, tumours with a high FDG-uptake responded better to radiotherapy than those with a low uptake [138]. Other series suggested that there was a correlation between volume changes on CT and decrease of FDG-uptake on PET, but that a persistently elevated FDG-uptake after radiotherapy predicted an early relapse, irrespective of the volume changes on CT [138, 139].

Response evaluation post (induction) chemotherapy. If the mediastinoscopy in potentially operable NSCLC patients is positive for N2-disease, the results of direct surgical resection (or radiotherapy) are very disappointing [88, 91, 94, 140], mainly due to systemic relapses [96]. Rapidly increasing amounts of data indicate that effective systemic therapy (induction chemotherapy), followed by resection with mediastinal dissection, is a better treatment option for these patients [59–63]. Many authors pointed out that

clearance of viable tumour cells in the mediastinum (so-called downstaging) is very important for the long-term prognosis [141–146]. It was further stressed, in the Memorial-Sloan-Kettering series on induction chemotherapy, that the estimated 5-yr survival rate of patients with a pathological complete response was 54%, while it was only 15% in those without pathological complete response [147].

After induction chemotherapy, one should ideally be able to select the patients with clearance of mediastinal involvement for radical surgical treatment, and to avoid it in the others. CT has not proven to be a good tool to evaluate downstaging after induction chemotherapy. It is well known that patients with little decrease in measurements on CT can nonetheless have mediastinal LN downstaging, while those with an important decrease can still have viable tumour in their mediastinal LN. On the other hand, a remediastinoscopy is hardly technically feasible, due to fibrosis caused by the chemotherapy and by the extensive sampling during the first mediastinoscopy.

In a prospective pilot study, the authors examined if FDG-PET could be a reliable noninvasive technique to solve this problem [148]. FDG-PET proved to be 100% accurate in the evaluation of downstaging (*versus* 67% for CT). Furthermore, outcome after the entire combined modality treatment was correlated with the findings on the postinduction FDG-PET; survival was significantly better in patients with mediastinal clearance on FDG-PET ($p=0.01$) or with $>50\%$ decrease of the SUV of the primary tumour ($p=0.03$) after induction chemotherapy (fig. 9). A larger prospective multicentre study is ongoing. If these preliminary findings can be confirmed, PET could become a useful noninvasive tool to select patients for intensive locoregional treatment after induction chemotherapy.

Diagnosis of recurrence. The interpretation of a post-treatment chest radiograph or CT can be hampered by anatomical changes such as distortion of bronchi, infiltration of the lung parenchyma or mediastinum, or fibrotic changes, which may be difficult to distinguish from tumour relapse. The exact differential diagnosis can be of importance, especially in the light of the expanding possibilities for second-line treatment [149–153].

In one study, FDG-PET gave a correct positive result in 16 indeterminate lung lesions after previous lung tumour resection [32]. Other studies in patients whose CT images were suspect of recurrence have pointed at the possible distinction between post-therapy scarring and new viable tumour with sensitivity for FDG-PET 97–100%, specificity 62–100%, and accuracy 78–98% [133, 154–158]. False positive studies may occur if the FDG-PET is performed shortly after surgery or radiotherapy. These false positive findings are ascribed to either radiation pneumonitis or macrophage glycolysis in tumour necrosis [157]. An interval 4–6 months after therapy is recommended to be sure that inflammatory changes have subsided, so that adequate assessment of tumour viability is possible.

Prognosis. The TNM-staging is the most important tool to estimate the prognosis of NSCLC patients. It

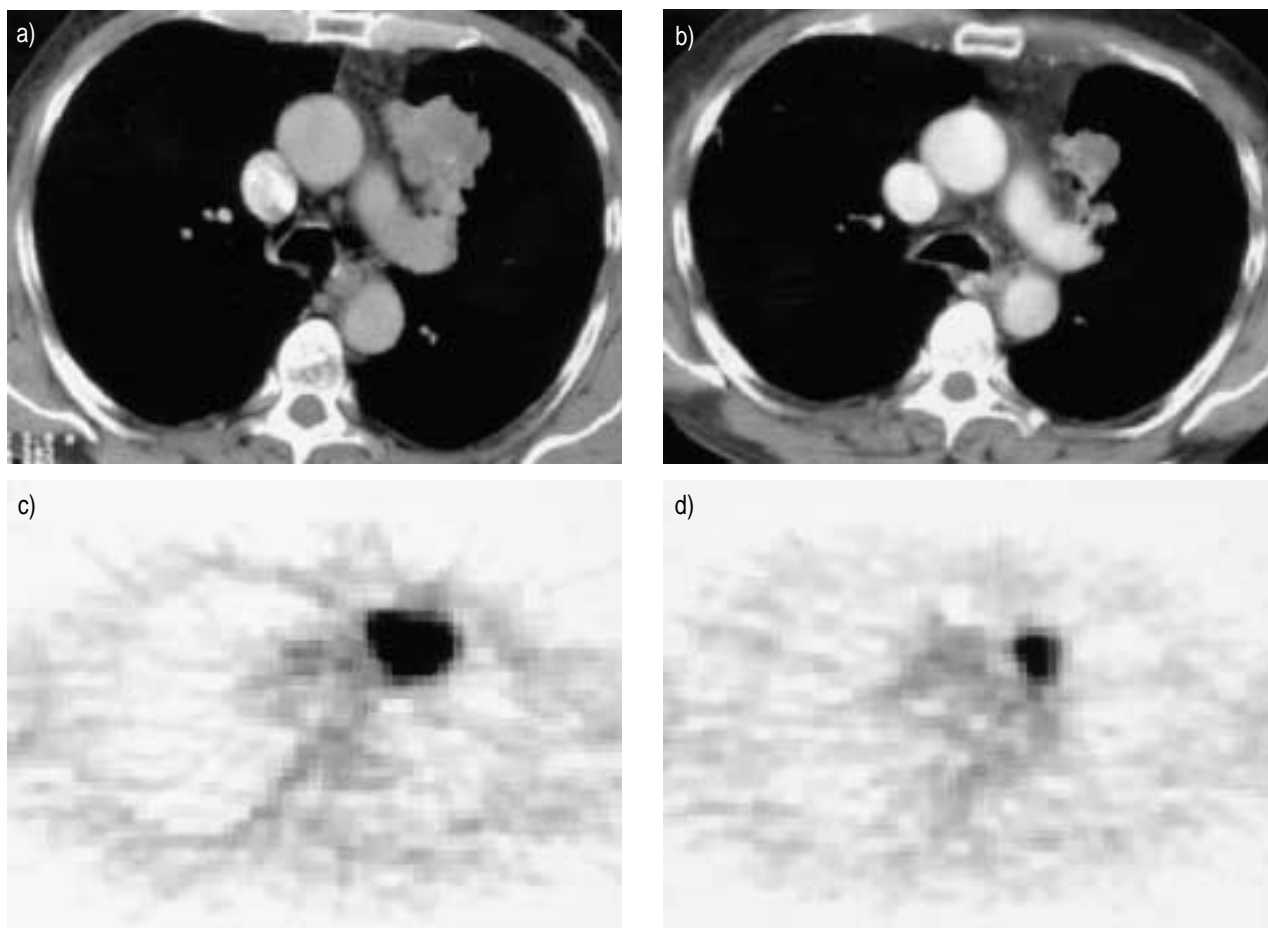


Fig. 9. – a) Computed tomography (CT) before and b) after induction chemotherapy: partial response (70% decrease in bi-dimensional measurement). Positron emission tomography (PET) c) before and d) after induction: decrease in volume confirmed, but only a -20% decrease in ^{18}F -fluoro-2-deoxy-D-glucose (FDG)-uptake. This patient developed an early systemic relapse.

does not, however, always give a satisfactory explanation for differences in survival. Resected stage I NSCLC is a typical example; many patients are cured, but some have an early relapse and die. Recent advances in molecular biology [159] have already helped to increase understanding of different patterns of survival in resected stage I NSCLC [160, 161]. For instance, in the Boston experience based on a molecular-biologic staging including angiogenesis, proto-oncogene *erbB-2*, suppressor gene *p53*, and the proliferation marker *KI-67*, a 5-yr survival of 81% was found in resected stage I NSCLC patients without any adverse marker, while it was only 49% in those with ≥ 3 markers [162].

Since NSCLC is characterized by important carbohydrate metabolic derangement's, which have also been identified as independent prognostic factors correlated with poor treatment response and survival [163, 164], measurement of the glucose metabolism *in vivo* with FDG-PET might have prognostic importance. This hypothesis is further substantiated by the finding that FDG-uptake in NSCLC cells is correlated with growth rate and proliferation capacity [165].

In one of the authors' studies, it was examined whether the SUV of the primary tumour at baseline was

predictive for the prognosis after treatment in 125 NSCLC patients [166]. It was found that an SUV of the primary tumour >7 had independent prognostic value, apart from the performance status and stage. In patients with a resected T1 tumour, the 2-yr survival was 86% if the SUV was <7 , and 60% if >7 . Similar findings, based on a cut-off SUV of 10 were reported by another group [167]. These researchers also examined the prognostic value of FDG-PET after primary treatment [168]. They found that patients with a positive FDG-PET after initial treatment had a median survival of 12 months, in contrast with those with a negative FDG-PET, of whom 85% were still alive at the time of analysis, after a median follow-up of 34 months ($p=0.002$).

Conclusions and future directions. The indication of FDG-PET as a complimentary tool to CT in the diagnosis and staging of NSCLC gradually gains widespread acceptance and also reimbursement in many European countries. A summary of its possible clinical implementation is depicted in figure 10. Further development is expected when commercial isotope distributors will be able to deliver FDG, so that an on-site cyclotron is no longer a prerequisite.

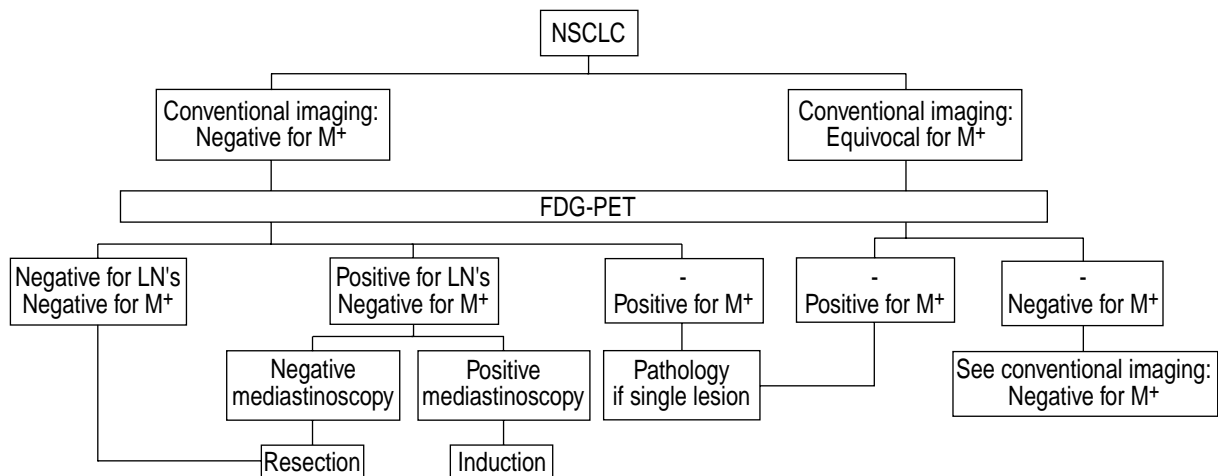


Fig. 10. – Algorithm for the implementation of ^{18}F -fluoro-2-deoxy-D-glucose positron emission tomography (FDG-PET) in nonsmall cell lung cancer (NSCLC). LN: lymph node; M^+ : metastasis.

^{18}F FDG has a half-life of 110 min, so a practical distribution radius 200–300 kilometres should be feasible. Another factor will be the more widespread availability of PET-cameras. The question whether the use of dual-head GCI will be a useful substitute still requires a large amount of carefully controlled clinical studies. It is also expected that the resolution and performance of both dedicated PET and dual-head GCI will still improve in the future [169]. The use of FDG-PET in the current clinical indications now needs further validation in multicentre, large-scale, randomized studies, focusing mainly on treatment outcome parameters, on the question whether FDG-PET actually improves survival prospects and on cost-efficacy issues. Other indications, such as evaluation of radio- or chemotherapy, radiotherapy planning, recurrence detection and prognosis determination need further well designed prospective investigations in more specialized centres.

Finally, a whole new field using PET in molecular applications is under exploration. FDG, with its possibility to study tumour glucose metabolism, has paved the way for PET in clinical oncology. Several other radiopharmaceuticals can also be used to study processes such as blood flow (H_2^{15}O), protein metabolism (^{11}C -methionine, ^{11}C -choline) and carbohydrate metabolism (^{11}C -acetate) [170]. One step further is the study by PET of cellular functions such as receptors, transport proteins or intracellular enzymes. The use of PET to study the efficacy of gene therapy in cancer is one example [171, 172]. Another example is how PET could be used as a guide in the selection or early assessment of anticancer therapy. Nowadays, it is difficult to predict response to chemotherapy and the choice of a chemotherapy regimen is mainly empirical. It is necessary to wait for the repeated chest radiograph or CT after several cycles before it can be determined whether therapy actually worked, thus, losing time and perhaps exposing the patient to needless toxicity. Ideally, it should be known what happens at the cellular level. Some years ago it was already reported that FDG-PET could demonstrate a significant decrease in tumour glucose metabolism after effective treatment for breast

cancer, with a reduction in the glucose metabolism before the radiological decrease in tumour size [173]. PET with ^{11}C -thymidine or its analogues could theoretically evaluate the efficacy of a treatment very shortly after the first dose, since ^{11}C -thymidine is rapidly incorporated into DNA, and thus mirrors proliferation of neoplastic cells [174]. After demonstration of the possibility of PET imaging with thymidine, the feasibility of measuring the response to chemotherapy in humans with ^{11}C -thymidine was recently reported [175].

Problems still to be solved relate to the short half-life of ^{11}C -thymidine (creating practical problems) and the rapid catabolism of thymidine in human cells, which creates major noise in the positron emission tomography image, unless very complex interpretation algorithms are used. Extensive research is ongoing to test new thymidine analogues with a longer half-life, with the same deoxyribonucleic acid incorporation properties, but minimized intracellular breakdown [176, 177]. If this concept can be brought into practice, it would enable us to tailor therapy for a specific patient, and move faster ahead in testing new drugs in phase I and II clinical studies, by using the endpoint of subclinical positron emission response response [178].

Acknowledgements. The authors would like to thank the numerous other coworkers involved in the FDG-PET research program of the Leuven Lung Cancer Group (LLCG): Data-nursing LLCG (B. Anrys, D. Strens); Nuclear Medicine (P. Dupont, L. Mortelmans, S. Stroobants); Pathology (E. Verbeken); Pneumology (M. Demedts, K. Nackaerts); Radiology (J. Bogaert, W. De Wever, J. Verschakelen); Radiotherapy (Y. Lievens, L. Van Uyttsel); Thoracic Surgery (P. De Leyn, G. Deneffe, T. Lerut, D. Van Raemdonck).

References

1. Mortelmans L, Vanhaecke J, Lesaffre E, *et al.* Evaluation of the effect of thrombolytic treatment on

- infarct size and left ventricular function by enzymatic, scintigraphic and angiographic methods. *Am Heart J* 1990; 6: 1231-1237.
2. Mortelmans L, Nuyts J, Scheys I, *et al.* A new quantitative method for the analysis of cardiac perfusion tomography (SPECT). Validation in patients treated with thrombolytic therapy. *Eur J Nucl Med* 1993; 20: 1193-1200.
 3. Warburg O, Posener K, Negelein E. The metabolism of the carcinoma cell. In: Warburg O, ed. *The Metabolism of Tumors*. New York, Richard R. Smith, Inc., 1931; pp.129-169.
 4. Nolop KB, Rhodes CG, Brudin LH, *et al.* Glucose utilization *in vivo* by human pulmonary neoplasms. *Cancer* 1987; 60: 2682-2689.
 5. Nelson CA, Wang JQ, Leav I, Crane PD. The interaction among glucose transport, hexokinase, and glucose-6-phosphatase with respect to 3H-2-deoxyglucose retention in murine tumor models. *Nuclear Med Biol* 1996; 23: 533-541.
 6. Yamamoto T, Seino Y, Fukumoto H, *et al.* Overexpression of facilitative glucose transporter genes in human cancer. *Biochem Biophys Res Commun* 1990; 170: 223-230.
 7. Ido T, Wan C, Carella V, *et al.* Labeled 2-deoxy-D-glucose analogs: 18F-labeled 2-deoxy-2-fluoro-D-glucose, 2-deoxy-2-fluoro-D-mannose and 14C-2-deoxy-2-fluoro-D-glucose. *J Label Compds Radiopharm* 1978; 24: 174-183.
 8. Monakhav NK, Neistadt EL, Showlowskil MM. Physicochemical properties and isoenzyme composition of hexokinase from normal and malignant human tissues. *J Natl Cancer Inst* 1978; 67: 27-34.
 9. Pauwels EK, McCready VR, Stoot JH, van Deurzen DF. The mechanism of accumulation of tumour-localising radiopharmaceuticals. *Eur J Nucl Med* 1998; 25: 277-305.
 10. Wahl R, Hutchins G, Bushsboam D, Liebert M, Grossman H, Fisher S. 18F-2-deoxy-2-fluoro-D-glucose uptake into human tumor xenografts: feasibility studies for cancer imaging with positron emission tomography. *Cancer* 1991; 67: 1544-1550.
 11. Lassen U, Andersen P, Daugaard G, *et al.* Metabolic and hemodynamic evaluation of brain metastases from small cell lung cancer with positron emission tomography. *Clin Cancer Res* 1998; 4: 2591-2597.
 12. Shuke N, Tonami N, Shintani H, *et al.* Differential uptake of TI-201 by small cell lung cancer in a patient with pneumoconiosis-related pulmonary nodules. *Clin Nucl Med* 1999; 24: 687-690.
 13. Patlak CS, Blasberg RG. Graphical evaluation of blood-to-brain transfer constants from multiple-time uptake data. Generalizations. *J Cereb Blood Flow Metab* 1985; 5: 584-590.
 14. Dupont P, Orban G, Vogels R, *et al.* Different perceptual tasks performed with the same visual stimulus attribute activate different regions of the human brain: a PET study. *Proc Nat Acad Science* 1993; 90: 10927-10931.
 15. Huang SC, Phelps ME, Hoffman EJ, Sideris K, Selin CJ, Kuhl DE. Noninvasive determination of local cerebral metabolic rate of glucose in man. *Am J Physiol* 1980; 238: E69-82.
 16. Keyes JW. SUV: standard uptake or silly useless value? *J Nucl Med* 1995; 36: 1836-1839.
 17. Meikle SR, Bailey DL, Hooper PK, *et al.* Simultaneous emission and transmission measurements for attenuation correction in whole-body PET. *J Nucl Med* 1995; 36: 1680-1688.
 18. Hooper PK, Meikle SR, Eberl S, Fulham MJ. Validation of postinjection transmission measurements for attenuation correction in neurological FDG-PET studies. *J Nucl Med* 1996; 37: 128-136.
 19. Coleman RE, Laymon CM, Turkington TG. FDG imaging of lung nodules: a phantom study comparing SPECT, camera-based PET, and dedicated PET. *Radiology* 1999; 210: 823-828.
 20. Tatsumi M, Yutani K, Watanabe Y, *et al.* Feasibility of fluorodeoxyglucose dual-head gamma camera coincidence imaging in the evaluation of lung cancer: comparison with FDG-PET. *J Nucl Med* 1999; 40: 566-573.
 21. Weber WA, Neverve J, Sklarek J, *et al.* Imaging of lung cancer with fluorine-18 fluorodeoxyglucose: comparison of a dual-head gamma camera in coincidence mode with a full-ring positron emission tomography system. *Eur J Nucl Med* 1999; 26: 388-395.
 22. Lonneux M, Delval D, Bausart R, *et al.* Can dual-headed 18F-FDG SPET imaging reliably supersede PET in clinical oncology? A comparative study in lung and gastrointestinal tract cancer. *Nucl Med Commun* 1998; 19: 1047-1054.
 23. Shreve PD, Steventon RS, Deters EC, Kison PV, Gross MD, Wahl RL. Oncologic diagnosis with 2-[fluorine-18]fluoro-2-deoxy-D-glucose imaging: dual-head coincidence gamma camera *versus* positron emission tomographic scanner. *Radiology* 1998; 207: 431-437.
 24. Cummings SR, Lillington GA, Richard RJ. Managing solitary pulmonary nodules. The choice of strategy is a "close call". *Am Rev Respir Dis* 1986; 134: 453-460.
 25. Yankelevitz DF, Henschke CI. Does 2-year stability imply that pulmonary nodules are benign? *AJR Am J Roentgenol* 1997; 168: 325-328.
 26. Arroliga AC, Matthay RA. The role of bronchoscopy in lung cancer. *Clin Chest Med* 1993; 14: 87-98.
 27. Santambrogio L, Nosotti M, Bellaviti N, Pavoni G, Radice F, Caputo V. CT-guided fine-needle aspiration cytology of solitary pulmonary nodules: a prospective, randomized study of immediate cytologic evaluation. *Chest* 1997; 112: 423-425.
 28. Larscheid RC, Thorpe PE, Scott WJ. Percutaneous transthoracic needle aspiration biopsy: a comprehensive review of its current role in the diagnosis and treatment of lung tumors. *Chest* 1998; 114: 704-709.
 29. Michiels E, Demedts M. Pitfalls of transthoracic needle aspiration biopsy. *Acta Clin Belg* 1991; 46: 359-363.
 30. Sazon DA, Santiago SM, Soo Hoo GW, *et al.* Fluorodeoxyglucose-positron emission tomography in the detection and staging of lung cancer. *Am J Respir Crit Care Med* 1996; 153: 417-421.
 31. Lowe VJ, Fletcher JW, Gobar L, *et al.* Prospective investigation of positron emission tomography in lung nodules. *J Clin Oncol* 1998; 16: 1075-1084.
 32. Duhaylongsod FG, Lowe VJ, Patz EF, Vaughn AL, Coleman RE, Wolfe WG. Detection of primary and recurrent lung cancer by means of F-18 fluorodeoxyglucose positron emission tomography (FDG-PET). *J Thorac Cardiovasc Surg* 1995; 110: 130-139.
 33. Gupta NC, Maloof J, Gunel E. Probability of malignancy in solitary pulmonary nodules using fluorine-18-FDG and PET. *J Nucl Med* 1996; 37: 943-948.

34. Nackaerts K, Stroobants S, Vansteenkiste J, *et al.* The use of positron emission tomography (PET) in the differential diagnosis of indeterminate solitary pulmonary lesions. *Eur Respir J* 1997; 10: 425S.
35. Patz EF, Lowe VJ, Hoffman JM, *et al.* Focal pulmonary abnormalities: evaluation with F-18 fluorodeoxyglucose PET scanning. *Radiology* 1993; 188: 487-490.
36. Bury T, Dowlati A, Paulus P, *et al.* Evaluation of the solitary pulmonary nodule by positron emission tomography imaging. *Eur Respir J* 1996; 9: 410-414.
37. Slosman DO, Spiliopoulos A, Couson F, *et al.* Satellite PET and lung cancer: a prospective study in surgical patients. *Nucl Med Commun* 1993; 14: 955-961.
38. Dewan NA, Gupta NC, Redepenning LS, Phalen JJ, Frick MP. Diagnostic efficacy of PET-FDG imaging in solitary pulmonary nodules. Potential role in evaluation and management. *Chest* 1993; 104: 997-1002.
39. Kubota K, Matsuzawa T, Fujiwara T, *et al.* Differential diagnosis of lung tumor with positron emission tomography: a prospective study. *J Nucl Med* 1990; 31: 1927-1932.
40. Gupta NC, Frank AR, Dewan NA, *et al.* Solitary pulmonary nodules: detection of malignancy with PET with 2-[F-18]-fluoro-2-deoxy-D-glucose. *Radiology* 1992; 184: 441-444.
41. Gupta N, Gill H, Graeber G, Bishop H, Hurst J, Stephens T. Dynamic positron emission tomography with F-18 fluorodeoxyglucose imaging in differentiation of benign from malignant lung/mediastinal lesions. *Chest* 1998; 114: 1105-1111.
42. Lowe VJ, Hoffman JM, DeLong DM, Patz EF, Coleman RE. Semiquantitative and visual analysis of FDG-PET images in pulmonary abnormalities. *J Nucl Med* 1994; 35: 1771-1776.
43. Scott WJ, Schwabe JL, Gupta NC, Dewan NA, Reeb SD, Sugimoto JT. Positron emission tomography of lung tumors and mediastinal lymph nodes using [18F]fluorodeoxyglucose. The Members of the PET-Lung Tumor Study Group. *Ann Thorac Surg* 1994; 58: 698-703.
44. Erasmus JJ, McAdams HP, Patz EF, Coleman RE, Ahuja V, Goodman PC. Evaluation of primary pulmonary carcinoid tumors using FDG-PET. *AJR Am J Roentgenol* 1998; 170: 1369-1373.
45. Higashi K, Nishikawa T, Seki H, *et al.* Comparison of fluorine-18-FDG-PET and thallium-201 SPECT in evaluation of lung cancer. *J Nucl Med* 1998; 39: 9-15.
46. Higashi K, Ueda Y, Seki H, *et al.* Fluorine-18-FDG-PET imaging is negative in bronchioloalveolar lung carcinoma. *J Nucl Med* 1998; 39: 1016-1020.
47. Kim BT, Kim Y, Lee KS, *et al.* Localized form of bronchioloalveolar carcinoma: FDG-PET findings. *AJR Am J Roentgenol* 1998; 170: 935-939.
48. Kapucu LO, Meltzer CC, Townsend DW, Keenan RJ, Luketich JD. Fluorine-18-fluorodeoxyglucose uptake in pneumonia. *J Nucl Med* 1998; 39: 1267-1269.
49. Brudin LH, Valind SO, Rhodes CG, *et al.* Fluorine-18 deoxyglucose uptake in sarcoidosis measured with positron emission tomography. *Eur J Nucl Med* 1994; 21: 297-305.
50. Bakheet SM, Saleem M, Powe J, Al Amro A, Larsson SG, Mahassin Z. F-18 fluorodeoxyglucose chest uptake in lung inflammation and infection. *Clin Nucl Med* 2000; 25: 273-278.
51. Gambhir SS, Shepherd JE, Shah BD, *et al.* Analytical decision model for the cost-effective management of solitary pulmonary nodules. *J Clin Oncol* 1998; 16: 2113-2125.
52. Scott WJ, Shepherd J, Gambhir SS. Cost-effectiveness of FDG-PET for staging non-small cell lung cancer: a decision analysis. *Ann Thorac Surg* 1998; 66: 1876-1883.
53. Kosuda S, Ichihara K, Watanabe M, Kobayashi H, Kusano S. Decision-tree sensitivity analysis for cost-effectiveness of chest 2-fluoro-2-D-[(18F)]fluorodeoxyglucose positron emission tomography in patients with pulmonary nodules (non-small cell lung carcinoma) in Japan. *Chest* 2000; 117: 346-353.
54. Swensen SJ, Brown LR, Colby TV, Weaver AL, Midthun DE. Lung nodule enhancement at CT: prospective findings. *Radiology* 1996; 201: 447-455.
55. Seemann MD, Seemann O, Luboldt W, *et al.* Differentiation of malignant from benign solitary pulmonary lesions using chest radiography, spiral CT and HRCT. *Lung Cancer* 2000; 29: 105-124.
56. Schreurs AJ, Westermann CJ, Van Den Bosch JM, Vanderschueren RG, Brutel de la Riviere A, Knaepen PJ. A twenty-five-year follow-up of ninety-three resected typical carcinoid tumors of the lung. *J Thorac Cardiovasc Surg* 1992; 104: 1470-1475.
57. Jang HJ, Lee KS, Kwon OJ, Rhee CH, Shim YM, Han J. Bronchioloalveolar carcinoma: focal area of ground-glass attenuation at thin-section CT as an early sign. *Radiology* 1996; 199: 485-488.
58. Bittner RC, Felix R. Magnetic resonance (MR) imaging of the chest: state-of-the-art. *Eur Respir J* 1998; 11: 1392-1404.
59. Vansteenkiste J, De Leyn P, Deneffe G, *et al.* Present status of induction treatment for N2 non-small cell lung cancer: A review. *Eur J Cardiothorac Surg* 1998; 13: 1-12.
60. Roth J, Fossella F, Komaki RP, *et al.* A randomized trial comparing perioperative chemotherapy and surgery with surgery alone in resectable stage IIIA non small cell lung cancer. *J Natl Cancer Inst* 1994; 86: 673-680.
61. Rosell R, Gomez Codina J, Camps C, *et al.* A randomized trial comparing preoperative chemotherapy plus surgery with surgery alone in patients with non-small-cell lung cancer. *N Engl J Med* 1994; 330: 153-158.
62. Pass HI, Pogrebniak HW, Steinberg SM, Mulshine J, Minna J. Randomized trial of neoadjuvant therapy for lung cancer: interim analysis. *Ann Thorac Surg* 1992; 53: 992-998.
63. Splinter TA, Kirckpatrick A, Van Meerbeeck J, *et al.* Randomized trial of surgery versus radiotherapy in patients with stage IIIA non-small cell lung cancer after a response to induction-chemotherapy. Inter-group study 08941. *Proc Am Soc Clin Oncol* 1998; 17: 453A.
64. McCloud TC, Bourgouin PM, Greenberg RW, *et al.* Bronchogenic carcinoma: analysis of staging in the mediastinum with CT by correlative lymph node mapping and sampling. *Radiology* 1992; 182: 319-323.
65. Staples CA, Miller RR, Evans KG, Nelems B. Mediastinal nodes in bronchogenic carcinoma: comparison between CT and mediastinoscopy. *Radiology* 1988; 167: 367-372.
66. Martini N, Heelan R, Westcott J, *et al.* Comparative merits of conventional, computed tomographic, and magnetic resonance imaging in assessing mediastinal

- involvement in surgically confirmed lung carcinoma. *J Thorac Cardiovasc Surg* 1985; 90: 639–648.
67. Gdeedo A, Van Schil P, Corthouts B, Van Mieghem F, Van Meerbeeck J, Van Marck E. Prospective evaluation of computed tomography and mediastinoscopy in mediastinal lymph node staging. *Eur Respir J* 1997; 10: 1547–1551.
 68. Webb WR, Gatsouris S, Zerhouni EA, *et al.* CT and MR imaging in staging non-small cell bronchogenic carcinoma: report of the Radiology Diagnostic Oncology Group. *Radiology* 1991; 178: 705–713.
 69. Dillemans B, Deneffe G, Verschakelen J, Decramer M. Value of computed tomography and mediastinoscopy in preoperative evaluation of mediastinal nodes in non-small cell lung cancer. *Eur J Cardiothorac Surg* 1994; 8: 37–42.
 70. Saunders CA, Dussek JE, O'Doherty MJ, Maisey MN. Evaluation of fluorine-18-fluorodeoxyglucose whole body positron emission tomography imaging in the staging of lung cancer. *Ann Thorac Surg* 1999; 67: 790–797.
 71. Valk PE, Pounds TR, Hopkins DM, *et al.* Staging non-small cell lung cancer by whole-body positron emission tomographic imaging. *Ann Thorac Surg* 1995; 60: 1573–1581.
 72. Vansteenkiste JF, Stroobants SG, De Leyn PR, *et al.* Lymph node staging in non-small cell lung cancer with FDG-PET scan: A prospective study on 690 lymph node stations from 68 patients. *J Clin Oncol* 1998; 16: 2142–2149.
 73. Kernstine KH, Stanford W, Mullan BF, *et al.* PET, CT, and MRI with Combidex for mediastinal staging in non-small cell lung carcinoma. *Ann Thorac Surg* 1999; 68: 1022–1028.
 74. Vansteenkiste JF, Stroobants SG, Dupont PJ, *et al.* FDG-PET scan in potentially operable non-small cell lung cancer: Do anatomometabolic PET-CT fusion images improve the localisation of regional lymph node metastases? *Eur J Nucl Med* 1998; 25: 1495–1501.
 75. Vansteenkiste JF, Stroobants SG, De Leyn PR, *et al.* Mediastinal lymph node staging with FDG-PET scan in patients with potentially operable non-small cell lung cancer: A prospective analysis of 50 cases. *Chest* 1997; 112: 1480–1486.
 76. Bury T, Paulus P, Dowlati A, *et al.* Staging of the mediastinum: value of positron emission tomography imaging in non-small cell lung cancer. *Eur Respir J* 1996; 9: 2560–2564.
 77. Weng E, Tran L, Rege S, *et al.* Accuracy and clinical impact of mediastinal lymph node staging with FDG-PET imaging in potentially resectable lung cancer. *Am J Clin Oncol* 2000; 23: 47–52.
 78. Steinert HC, Hauser M, Allemann F, *et al.* Non-small cell lung cancer: Nodal staging with FDG-PET versus CT with correlative lymph node mapping and sampling. *Radiology* 1997; 202: 441–446.
 79. Patz EF, Lowe VJ, Goodman PC, Herndon J. Thoracic nodal staging with PET imaging with 18FDG in patients with bronchogenic carcinoma. *Chest* 1995; 108: 1617–1621.
 80. Chin R, Ward R, Keyes JW, *et al.* Mediastinal staging of non-small-cell lung cancer with positron emission tomography. *Am J Respir Crit Care Med* 1995; 152: 2090–2096.
 81. Scott WJ, Gobar LS, Terry JD, Dewan NA, Sunderland JJ. Mediastinal lymph node staging of non-small-cell lung cancer: a prospective comparison of computed tomography and positron emission tomography. *J Thorac Cardiovasc Surg* 1996; 111: 642–648.
 82. Albes JM, Lietzenmayer R, Schott U, Schulen E, Wehrmann M, Ziemer G. Improvement of non-small-cell lung cancer staging by means of positron emission tomography. *Thorac Cardiovasc Surgeon* 1999; 47: 42–47.
 83. Wahl RL, Quint LE, Greenough RL, Meyer CR, White RI, Orringer MB. Staging of mediastinal non-small cell lung cancer with FDG-PET, CT, and fusion images: preliminary prospective evaluation. *Radiology* 1994; 191: 371–377.
 84. Berlangieri SU, Scott AM, Knight SR, *et al.* F-18 fluorodeoxyglucose positron emission tomography in the non-invasive staging of non-small cell lung cancer. *Eur J Cardiothorac Surg* 1999; 16Suppl. 1S25–30.
 85. Sasaki M, Ichiya Y, Kuwabara Y, *et al.* The usefulness of FDG positron emission tomography for the detection of mediastinal lymph node metastases in patients with non-small cell lung cancer: a comparative study with X-ray computed tomography. *Eur J Nucl Med* 1996; 23: 741–747.
 86. Dwamena BA, Sonnad SS, Angobaldo JO, Wahl RL. Metastases from non-small cell lung cancer: mediastinal staging in the 1990s. Meta-analytic comparison of PET and CT. *Radiology* 1999; 213: 530–536.
 87. Goldstraw P, Mannam G, Kaplan D, Michael P. Surgical management of non-small cell lung cancer with ipsilateral mediastinal node metastasis (N2 disease). *J Thorac Cardiovasc Surg* 1994; 107: 19–28.
 88. Vansteenkiste JF, De Leyn PR, Deneffe GJ, *et al.* Survival and prognostic factors in resected N2 non-small cell lung cancer: A study of 140 cases. The Leuven Lung Cancer Group. *Ann Thorac Surg* 1997; 63: 1441–1450.
 89. Cybulski I, Lanza L, Bernadette R, Putnam J, McMurtrey M, Roth J. Prognostic significance of computed tomography in resected N2 lung cancer. *Ann Thorac Surg* 1992; 54: 533–537.
 90. Kirsh M, Sloan H. Mediastinal metastases in bronchogenic carcinoma: Influence of postoperative irradiation, cell type, and location. *Ann Thorac Surg* 1982; 33: 459–463.
 91. Pearson F, DeLarue N, Ilves R, Todd T, Cooper J. Significance of positive superior mediastinal nodes identified at mediastinoscopy in patients with resectable cancer of the lung. *J Thorac Cardiovasc Surg* 1982; 83: 1–11.
 92. Deneffe G, Stalpaert G. Five year survival in resected T3/N2 lung cancer. *Acta Chir Belg* 1989; 89: 159–160.
 93. Klastersky J, Burkes R, Choi NC, *et al.* Induction therapy for NSCLC: a consensus report. *Lung Cancer* 1991; 7: 15–17.
 94. Martini N, Flehinger B. The role of surgery in N2 lung cancer. *Surg Clin North Am* 1987; 67: 1037–1049.
 95. Goldstraw P. The practice of cardiothoracic surgeons in the perioperative staging of non-small cell lung cancer. *Thorax* 1992; 47: 1–3.
 96. Kumar P, Herndon J, Langer M, *et al.* Patterns of disease failure after trimodality therapy of non-small cell lung carcinoma pathologic stage IIIA (N2). *Cancer* 1996; 77: 2393–2399.
 97. Gambhir SS, Hoh CK, Phelps ME, Madar I, Maddahi J. Decision tree sensitivity analysis for cost-effectiveness of FDG-PET in the staging and management of non-small cell lung carcinoma. *J Nucl Med* 1996; 37: 1428–1436.

98. ATS Guidelines. Pretreatment evaluation of non-small cell lung cancer. The American Thoracic Society and The European Respiratory Society. *Am J Respir Crit Care Med* 1997; 156: 320-332.
99. Goldstraw P, Rocmans P, Ball D, *et al.* Pretreatment minimal staging for non-small cell lung cancer: an updated consensus report. *Lung Cancer* 1994; 11: Suppl. 3, 1-4.
100. Martini N, Bains MS, Burt ME, *et al.* Incidence of local recurrence and second primary tumors in resected stage I lung cancer. *J Thorac Cardiovasc Surg* 1995; 109: 120-129.
101. Pairolero PC, Williams DE, Bergstralh EJ, Pehler JM, Bernatz PE, Payne WS. Postsurgical stage I bronchogenic carcinoma: morbid implications of recurrent disease. *Ann Thorac Surg* 1984; 38: 331-338.
102. Yano T, Yokoyama H, Inoue T, *et al.* The first site of recurrence after complete resection in non-small cell carcinoma of the lung. Comparison between pN0 disease and pN2 disease. *J Thorac Cardiovasc Surg* 1994; 108: 680-683.
103. Pantel K, Izbicki J, Passlick B, *et al.* Frequency and prognostic significance of isolated tumour cells in bone marrow of patients with non-small cell lung cancer without overt metastases. *Lancet* 1996; 347: 649-653.
104. Quint LE, Tummala S, Brisson LJ, *et al.* Distribution of distant metastases from newly diagnosed non-small cell lung cancer. *Ann Thorac Surg* 1996; 62: 246-250.
105. Parker SL, Tong T, Bolden S, Wingo PA. Cancer statistics 1997. *CA Cancer J Clin* 1997; 47: 5-27.
106. Bury T, Barreto A, Daenen F, Barthelemy N, Ghaye B, Rigo P. Fluorine-18 deoxyglucose positron emission tomography for the detection of bone metastases in patients with non-small cell lung cancer. *Eur J Nucl Med* 1998; 25: 1244-1247.
107. Schirrmeyer H, Guhlmann A, Elsner K, *et al.* Sensitivity in detecting osseous lesions depends on anatomic localization: planar bone scintigraphy versus 18F-PET. *J Nucl Med* 1999; 40: 1623-1629.
108. Moon DH, Maddahi J, Silverman DH, Glaspy JA, Phelps ME, Hoh CK. Accuracy of whole-body fluorine-18-FDG PET for the detection of recurrent or metastatic breast carcinoma. *J Nucl Med* 1998; 39: 431-435.
109. Cook GJ, Houston S, Rubens R, Maisey MN, Fogelman I. Detection of bone metastases in breast cancer by 18FDG-PET: differing metabolic activity in osteoblastic and osteolytic lesions. *J Clin Oncol* 1998; 16: 3375-3379.
110. Oliver TW, Bernardino ME, Miller JI, Mansour K, Greene D, Davis WA. Isolated adrenal masses in non-small cell bronchogenic carcinoma. *Radiology* 1984; 153: 217-218.
111. Nielsen ME, Heaston DK, Dunnick NR, Korobkin M. Preoperative CT evaluation of adrenal glands in non-small cell bronchogenic carcinoma. *AJR Am J Roentgenol* 1982; 139: 317-320.
112. Paganì JJ. Non-small cell lung carcinoma adrenal metastases. Computed tomography and percutaneous needle biopsy in their diagnosis. *Cancer* 1984; 53: 1058-1060.
113. Ettinghausen SE, Burt ME. Prospective evaluation of unilateral adrenal masses in patients with operable non-small cell lung cancer. *J Clin Oncol* 1991; 9: 1462-1466.
114. Erasmus JJ, Patz EF, McAdams HP, *et al.* Evaluation of adrenal masses in patients with bronchogenic carcinoma using 18F-fluorodeoxyglucose positron emission tomography. *AJR Am J Roentgenol* 1997; 168: 1357-1360.
115. Boland GW, Goldberg MA, Lee MJ, *et al.* Indeterminate adrenal mass in patients with cancer: evaluation at PET with 2-[F-18]-fluoro-2-deoxy-D-glucose. *Radiology* 1995; 194: 131-134.
116. Maurea S, Mainolfi C, Bazzicalupo L, *et al.* Imaging of adrenal tumors using FDG PET: comparison of benign and malignant lesions. *AJR Am J Roentgenol* 1999; 173: 25-29.
117. Patz EF, Erasmus JJ, McAdams HP, *et al.* Lung cancer staging and management: comparison of contrast-enhanced and nonenhanced helical CT of the thorax. *Radiology* 1999; 212: 56-60.
118. Weder W, Schmid RA, Bruchhaus H, Hillinger S, von Schulthess GK, Steinert HC. Detection of extrathoracic metastases by positron emission tomography in lung cancer. *Ann Thorac Surg* 1998; 66: 886-892.
119. Marom EM, McAdams HP, Erasmus JJ, *et al.* Staging non-small cell lung cancer with whole-body PET. *Radiology* 1999; 212: 803-809.
120. Hustinx R, Paulus P, Jacquet N, Jerusalem G, Bury T, Rigo P. Clinical evaluation of whole-body 18F-fluorodeoxyglucose positron emission tomography in the detection of liver metastases. *Ann Oncol* 1998; 9: 397-401.
121. Abdel Nabi H, Doerr RJ, Lamonica DM, *et al.* Staging of primary colorectal carcinomas with fluorine-18 fluorodeoxyglucose whole-body PET: correlation with histopathologic and CT findings. *Radiology* 1998; 206: 755-760.
122. Flamen P, Stroobants S, Van Cutsem E, *et al.* Additional value of whole-body positron emission tomography with fluorine-18-2-fluoro-2-deoxy-D-glucose in recurrent colorectal cancer. *J Clin Oncol* 1999; 17: 894-901.
123. Nakamoto Y, Higashi T, Sakahara H, *et al.* Contribution of PET in the detection of liver metastases from pancreatic tumours. *Clin Radiol* 1999; 54: 248-252.
124. Rankin SC, Taylor H, Cook GJ, Mason R. Computed tomography and positron emission tomography in the pre-operative staging of oesophageal carcinoma. *Clin Radiol* 1998; 53: 659-665.
125. Delbeke D, Martin WH, Sandler MP, Chapman WC, Wright JK, Pinson CW. Evaluation of benign vs malignant hepatic lesions with positron emission tomography. *Arch Surg* 1998; 133: 510-515.
126. Griffeth LK, Rich KM, Dehdashti F, *et al.* Brain metastases from non-central nervous system tumors: evaluation with PET. *Radiology* 1993; 186: 37-44.
127. Bury T, Dowlati A, Paulus P, Hustinx R, Radermecker M, Rigo P. Staging of non-small cell lung cancer by whole-body fluorine-18 deoxyglucose positron emission tomography. *Eur J Nucl Med* 1996; 23: 204-206.
128. Lewis P, Griffin S, Marsden P, *et al.* Whole-body 18F-fluorodeoxyglucose positron emission tomography in preoperative evaluation of lung cancer. *Lancet* 1994; 344: 1265-1266.
129. Graham MV, Purdy JA, Emami B, Matthews JW, Harms WB. Preliminary results of a prospective trial using three dimensional radiotherapy for lung cancer. *Int J Radiat Oncol Biol Phys* 1995; 33: 993-1000.
130. Kwa SL, Lebesque JV, Theuws JC, *et al.* Radiation pneumonitis as a function of mean lung dose: an

- analysis of pooled data of 540 patients. *Int J Radiat Oncol Biol Phys* 1998; 42: 1-9.
131. Marks LB, Munley MT, Bentel GC, *et al.* Physical and biological predictors of changes in whole-lung function following thoracic irradiation. *Int J Radiat Oncol Biol Phys* 1997; 39: 563-570.
 132. Martel MK, Ten Haken RK, Hazuka MB, Turrisi AT, Fraass BA, Lichter AS. Dose-volume histogram and 3-D treatment planning evaluation of patients with pneumonitis. *Int J Radiat Oncol Biol Phys* 1994; 28: 575-581.
 133. Hebert ME, Lowe VJ, Hoffman JM, Patz EF, Anscher MS. Positron emission tomography in the pretreatment evaluation and follow-up of non-small cell lung cancer patients treated with radiotherapy: preliminary findings. *Am J Clin Oncol* 1996; 19: 416-421.
 134. Nestle U, Walter K, Schmidt S, *et al.* 18F-deoxyglucose positron emission tomography (FDG-PET) for the planning of radiotherapy in lung cancer: high impact in patients with atelectasis. *Int J Radiat Oncol Biol Phys* 1999; 44: 593-597.
 135. Vanuytsel LJ, Vansteenkiste JF, Stroobants SG, *et al.* The impact of (18)F-fluoro-2-deoxy-D-glucose positron emission tomography (FDG-PET) lymph node staging on the radiation treatment volumes in patients with non-small cell lung cancer. *Radiother Oncol* 2000; 55: 317-324.
 136. Kiffer JD, Berlangieri SU, Scott AM, *et al.* The contribution of 18F-fluoro-2-deoxy-glucose positron emission tomographic imaging to radiotherapy planning in lung cancer. *Lung Cancer* 1998; 19: 167-177.
 137. Munley MT, Marks LB, Scarfone C, *et al.* Multimodality nuclear medicine imaging in three-dimensional radiation treatment planning for lung cancer: challenges and prospects. *Lung Cancer* 1999; 23: 105-114.
 138. Ichiya Y, Kuwabara Y, Sasaki M, *et al.* A clinical evaluation of FDG-PET to assess the response in radiation therapy for bronchogenic carcinoma. *Ann Nucl Med* 1996; 10: 193-200.
 139. Kubota K, Yamada S, Ishiwata K, *et al.* Evaluation of the treatment response of lung cancer with positron emission tomography and L-[methyl-11C]methionine: a preliminary study. *Eur J Nucl Med* 1993; 20: 495-501.
 140. Johnson DH, Einhorn LH, Bartolucci A, *et al.* Thoracic radiotherapy does not prolong survival in patients with locally advanced, unresectable non-small cell lung cancer. *Ann Intern Med* 1990; 113: 33-38.
 141. Martini N, Kris MG, Flehinger B, *et al.* Preoperative chemotherapy for stage IIIa (N2) lung cancer: The Sloan-Kettering experience with 136 patients. *Ann Thorac Surg* 1993; 55: 1365-1374.
 142. Albain KS, Rusch VW, Crowley JJ, *et al.* Concurrent cisplatin/etoposide plus chest radiotherapy followed by surgery for stages IIIA (N2) and IIIB non-small-cell lung cancer: mature results of Southwest Oncology Group phase II study 8805. *J Clin Oncol* 1995; 13: 1880-1892.
 143. Rice TW, Adelstein DJ, Koka A, *et al.* Accelerated induction therapy and resection for poor prognosis stage III non-small cell lung cancer. *Ann Thorac Surg* 1995; 60: 586-591.
 144. Weitberg AB, Yashar J, Glicksman AS, *et al.* Combined modality therapy for stage IIIA non-small cell carcinoma of the lung. *Eur J Cancer* 1993; 29A: 511-515.
 145. Strauss GM, Herndon JE, Sherman DD, *et al.* Neoadjuvant chemotherapy and radiotherapy followed by surgery in stage IIIA non-small-cell carcinoma of the lung: report of a Cancer and Leukemia Group B phase II study. *J Clin Oncol* 1992; 10: 1237-1244.
 146. Choi NC, Carey RW, Daly W, *et al.* Potential impact on survival of improved tumor downstaging and resection rate by preoperative twice-daily radiation and concurrent chemotherapy in stage IIIA non-small-cell lung cancer. *J Clin Oncol* 1997; 15: 712-722.
 147. Pisters KM, Kris MG, Gralla RJ, Zaman MB, Heelan RT, Martini N. Pathologic complete response in advanced non-small-cell lung cancer following preoperative chemotherapy: implications for the design of future non-small-cell lung cancer combined modality trials. *J Clin Oncol* 1993; 11: 1757-1762.
 148. Vansteenkiste JF, Stroobants SG, De Leyn PR, *et al.* Potential use of FDG-PET scan after induction chemotherapy in surgically staged IIIA-N2 non-small cell lung cancer: A prospective pilot study. *Ann Oncol* 1998; 9: 1193-1198.
 149. Fossella FV, Lee JS, Shin DM, *et al.* Phase II study of docetaxel for advanced or metastatic platinum-refractory non-small cell lung cancer. *J Clin Oncol* 1995; 13: 645-651.
 150. Fossella FV, Lee JS, Berille J, Hong WK. Summary of phase II data of docetaxel (Taxotere), an active agent in the first- and second-line treatment of advanced non-small cell lung cancer. *Semin Oncol* 1995; 22: 22-29.
 151. Gandara DR, Vokes E, Green M, *et al.* Activity of docetaxel in platinum-treated non-small cell lung cancer: results of a phase II multicenter trial. *J Clin Oncol* 2000; 18: 131-135.
 152. Crino L, Mosconi AM, Scagliotti GV, *et al.* Gemcitabine as second-line treatment for advanced non-small cell lung cancer: A phase II trial. *J Clin Oncol* 1999; 17: 2081-2085.
 153. Sculier JP, Lafitte JJ, Berghmans T, *et al.* A phase II trial testing gemcitabine as second-line chemotherapy for non-small cell lung cancer. *Lung Cancer* 2000; 29: 67-73.
 154. Kubota K, Yamada S, Ishiwata K, Ito M, Ido T. Positron emission tomography for treatment evaluation and recurrence detection compared with CT in long-term follow-up cases of lung cancer. *Clin Nucl Med* 1992; 17: 877-881.
 155. Inoue T, Kim EE, Komaki R, *et al.* Detecting recurrent or residual lung cancer with FDG-PET. *J Nucl Med* 1995; 36: 788-793.
 156. Patz EF, Lowe VJ, Hoffman JM, Paine SS, Harris LK, Goodman PC. Persistent or recurrent bronchogenic carcinoma: detection with PET and 2-[F-18]-2-deoxy-D-glucose. *Radiology* 1994; 191: 379-382.
 157. Frank A, Lefkowitz D, Jaeger S, *et al.* Decision logic for retreatment of asymptomatic lung cancer recurrence based on positron emission tomography findings. *Int J Radiat Oncol Biol Phys* 1995; 32: 1495-1512.
 158. Bury T, Corhay JL, Duysinx B, *et al.* Value of FDG-PET in detecting residual or recurrent non-small cell lung cancer. *Eur Respir J* 1999; 14: 1376-1380.
 159. Salgia R, Skarin AT. Molecular abnormalities in lung cancer. *J Clin Oncol* 1998; 16: 1207-1217.
 160. Harpole DH, Herndon JE, Wolfe WG, Iglehart JD, Marks JR. A prognostic model of recurrence and death in stage I non-small cell lung cancer utilizing

- presentation, histopathology, and oncoprotein expression. *Cancer Res* 1995; 55: 51–56.
161. Apolinario RM, van der Valk P, de Jong JS, *et al*. Prognostic value of the expression of p53, bcl-2, and bax oncoproteins, and neovascularization in patients with radically resected non-small-cell lung cancer. *J Clin Oncol* 1997; 15: 2456–2466.
 162. Harpole DH, Richards WG, Herndon JE, Sugarbaker DJ. Angiogenesis and molecular biologic subtyping in patients with stage I non-small cell lung cancer. *Ann Thorac Surg* 1996; 61: 1470–1476.
 163. Stanley KE. Prognostic factors for survival in patients with inoperable lung cancer. *J Natl Cancer Inst* 1980; 65: 25–32.
 164. Vansteenkiste JF, Simons JP, Wouters EF, Demedts MG. Hormonal treatment in advanced non-small cell lung cancer: fact or fiction?. *Eur Respir J* 1996; 9: 1707–1712.
 165. Duhaylongsod FG, Lowe VJ, Patz EF, Vaughn AL, Coleman RE, Wolfe WG. Lung tumor growth correlates with glucose metabolism measured by fluoride-18 fluorodeoxyglucose positron emission tomography. *Ann Thorac Surg* 1995; 60: 1348–1352.
 166. Vansteenkiste JF, Stroobants SG, De Leyn PR, *et al*. Prognostic importance of the Standardized Uptake Value on FDG-PET-scan in non-small cell lung cancer: An analysis of 125 cases. *J Clin Oncol* 1999; 10: 3201–3206.
 167. Ahuja V, Coleman RE, Herndon J, Patz EF. The prognostic significance of fluorodeoxyglucose positron emission tomography imaging for patients with non-small cell lung carcinoma. *Cancer* 1998; 83: 918–924.
 168. Patz EF, Connolly J, Herndon J. Prognostic value of thoracic FDG-PET imaging after treatment for non-small cell lung cancer. *AJR Am J Roentgenol* 2000; 174: 769–774.
 169. Budinger TF. PET instrumentation: what are the limits?. *Semin Nucl Med* 1998; 28: 247–267.
 170. Tewson TJ, Krohn KA. PET radiopharmaceuticals: state-of-the-art and future prospects. *Semin Nucl Med* 1998; 28: 221–234.
 171. Alauddin MM, Shahinian A, Kundu RK, Gordon EM, Conti PS. Evaluation of 9-[(3-18F-fluoro-1-hydroxy-2-propoxy)methyl]guanine ([18F]-FHPG) *in vitro* and *in vivo* as a probe for PET imaging of gene incorporation and expression in tumors. *Nucl Med Biol* 1999; 26: 371–376.
 172. Alauddin MM, Conti PS. Synthesis and preliminary evaluation of 9-(4-[18F]-fluoro-3-hydroxymethylbutyl) guanine ([18F]FHBG): a new potential imaging agent for viral infection and gene therapy using PET. *Nucl Med Biol* 1998; 25: 175–180.
 173. Wahl RL, Zasadny K, Helvie M, Hutchins GD, Weber B, Cody R. Metabolic monitoring of breast cancer chemohormonotherapy using positron emission tomography: initial evaluation. *J Clin Oncol* 1993; 11: 2101–2111.
 174. Christman D, Crawford EJ, Friedkin M, Wolf AP. Detection of DNA synthesis in intact organisms with positron-emitting (methyl-11C)thymidine. *Proc Nat Acad Science* 1972; 69: 988–992.
 175. Shields AF, Mankoff DA, Link JM, *et al*. Carbon-11-thymidine and FDG to measure therapy response. *J Nucl Med* 1998; 39: 1757–1762.
 176. Conti PS, Alauddin MM, Fissekis JR, Schmall B, Watanabe KA. Synthesis of 2'-fluoro-5-[11C]-methyl-1-beta-D-arabinofuranosyluracil ([11C]-FMAU): a potential nucleoside analog for *in vivo* study of cellular proliferation with PET. *Nucl Med Biol* 1995; 22: 783–789.
 177. Shields AF, Grierson JR, Dohmen BM, *et al*. Imaging proliferation *in vivo* with [F-18]FLT and positron emission tomography. *Nat Med* 1998; 4: 1334–1336.
 178. Price P, Jones T. Can positron emission tomography (PET) be used to detect subclinical response to cancer therapy? The EC PET Oncology Concerted Action and the EORTC PET Study Group. *Eur J Cancer* 1995; 31A: 1924–1927.