

## CASE STUDY

# Early-onset phenytoin toxicity mimicking a renopulmonary syndrome

A.J. Polman\*, T.S. van der Werf\*, A.T.M.C. Tiebosch\*\*, J.G. Zijlstra\*

*Early-onset phenytoin toxicity mimicking a renopulmonary syndrome. A.J. Polman, T.S. van der Werf, A.T.M.C. Tiebosch, J.G. Zijlstra. ©ERS Journals Ltd 1998.*

**ABSTRACT:** Phenytoin is a commonly used anti-epileptic drug. Adverse reactions including fever, skin reactions and lymphadenopathy are well known but atypical reactions can also occur. A patient is described with a lag time of only 4 days between onset of phenytoin and the development of a syndrome with acute lung injury and renal failure. The symptoms mimicked a renopulmonary syndrome, and resolved completely after cessation of phenytoin and addition of steroids.

*Eur Respir J 1998; 11: 501–503.*

Depts of \*Internal Medicine and \*\*Pathology, University Hospital Groningen, The Netherlands.

Correspondence: J.G. Zijlstra, Intensive and Respiratory Care Unit, Dept of Internal Medicine, University Hospital Groningen, P.O. 30.001, 9700 RB Groningen, The Netherlands.

Fax: 31 503613216

Keywords: Acute lung injury, adverse drug reactions, phenytoin, renal failure

Received: March 21 1997

Accepted after revision July 21 1997

Adverse reactions to phenytoin have been described since the introduction of this drug in 1936 [1–3]. Incidence appears to be in the range of 1:1,000 to 1:10,000. The reactions are mainly extrapulmonary, and include gingival hypertrophy, fever, cutaneous reactions, lymphadenopathy, hepatitis, splenomegaly and granulocytopenia [2–4]. Typically, the reactions occur months to years after starting the drug; they are not clearly dose-dependent. Pulmonary complications have occasionally been described. We present a case of acute lung injury accompanied by renal failure after only 4 days of phenytoin use.

### Case report

A 32 yr old man with no previous medical history (apart from smoking and an alcohol abuse of 6 units daily) was admitted to the neurology department because of seizures that developed 3 weeks after a head trauma due to a car accident. On admission, the patient had no other complaints. He had no pulmonary symptoms or any other physical sign or symptom. The chest radiograph was normal. Phenytoin was started (loading dose 1,000 mg *i.v.* followed by 150 mg *b.i.d.*). After 4 days, he became febrile, dyspnoeic and developed renal failure. He also developed mild haemoptysis. He was transferred to the medical intensive care unit (ICU) on day 5. A renopulmonary syndrome such as Wegener's granulomatosis or Good-pasture's syndrome was suspected.

On admission to the ICU, body temperature was 38.8°C. There were no skin lesions or lymphadenopathy. Chest examination revealed rales over both lower regions. The chest radiograph showed diffuse alveolar/interstitial infiltrates (fig. 1). There were no electrolyte disturbances, serum urea was 18.5 mmol·L<sup>-1</sup> (normal 3.3–6.7) and ser-

um creatinine 607 μmol·L<sup>-1</sup> (normal 62–107). Liver function tests revealed: alkaline phosphatase 104 U·L<sup>-1</sup> (normal 13–120); lactate dehydrogenase 492 U·L<sup>-1</sup> (normal 114–235); aspartate aminotransferase (ASAT) 39 U·L<sup>-1</sup> (normal 0–40); alanine aminotransferase (ALAT) 44 U·L<sup>-1</sup> (normal 0–30); gamma-glutamyltransferase 395 U·L<sup>-1</sup> (normal 0–65); and total bilirubin 17 μmol·L<sup>-1</sup> (normal 3–26). Haemoglobin was 6.4 mmol·L<sup>-1</sup> (9.6 on day 1), white cell count was 11.6×10<sup>9</sup>·L<sup>-1</sup> (neutrophils 75.5%, lymphocytes 13.3%, monocytes 8.3%, eosinophils 2.8% and basophils 0%). Urinalysis showed elevated red cells (15–20 per

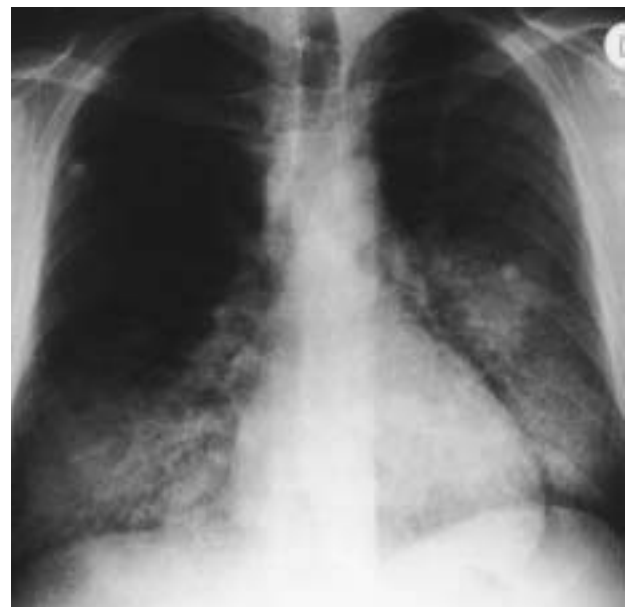

Fig. 1. – Chest radiograph on day 5 showing bilateral alveolar/interstitial infiltrates.

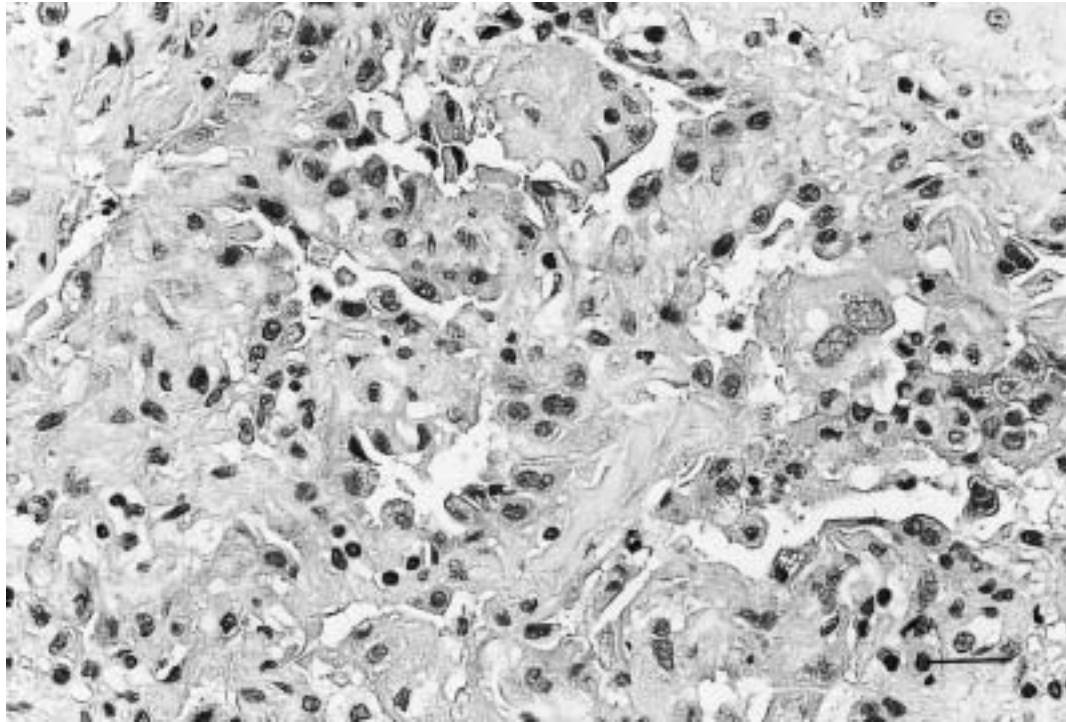


Fig. 2. – Transbronchial biopsy taken on day 8 showing metaplastic type II pneumocytes, lymphocytic and plasmacytic infiltrates and interstitial fibrosis. (Haematoxylin and eosin stain; internal scale bar = 25  $\mu\text{m}$ ).

high-power field) and leucocyturia (0–5 per high-power field) but no casts. Urinary sodium excretion was 12  $\text{mmol}\cdot 24\text{ h}^{-1}$ , creatinine 10.6  $\text{mmol}\cdot 24\text{ h}^{-1}$  and proteinuria 0.6  $\text{g}\cdot 24\text{ h}^{-1}$ .

Arterial blood gas analysis showed pH 7.42, arterial oxygen tension ( $P_{\text{a},\text{O}_2}$ ) 6.1 kPa, arterial carbon dioxide tension ( $P_{\text{a},\text{CO}_2}$ ) 3.6 kPa, bicarbonate 17  $\text{mmol}\cdot\text{L}^{-1}$  and arterial oxygen saturation ( $S_{\text{a},\text{O}_2}$ ) 84%. Additional blood tests on day 5 revealed negative antinuclear-antigen, anti-glomerular basement membrane and antineutrophilic cytoplasmic antigen (indirect immunofluorescence) serology; C-reactive protein (CRP) rose from 1  $\text{mg}\cdot\text{L}^{-1}$  on day 1, to 97 on day 5; immunoglobulin (Ig)A, IgG, IgM, complement factors C3, and C4 were normal. Serology against *Legionella pneumophila*, Hantavirus, Mycoplasma, Chlamydia, and *Coxiella burnetii* was negative at admission, and after 21 days. After taking blood and sputum cultures, cefuroxime was administered for 4 days for possible aspiration pneumonia. Cultures remained negative. On day 5, a renal biopsy was performed which showed 14 glomeruli with no signs of glomerulonephritis or vasculitis and normal overall histology. The tubuli showed no apparent changes. Immunofluorescence with polyclonal antibodies against human globulin and complement factors were negative. On day 8, the pulmonary infiltrates increased on the chest radiograph and blood gases deteriorated. After orotracheal intubation, bronchoscopy with bronchoalveolar lavage (BAL) and transbronchial biopsy were performed. Gram-stain and culture of the BAL fluid showed a low-density mixed flora considered to be contamination by nonpathogenic mouth flora. The lung biopsy showed swollen metaplastic type II pneumocytes, interstitial fibrosis with lymphocytic and plasmacytic infiltration at some places expanding in the intra-alveolar space. There was no eosinophilic infil-

tration, vasculitis, or granuloma formation (fig. 2). Phenytoin was stopped on day 9, and prednisolone was started at a daily dose of 100 mg *i.v.*, after which the patient recovered. At day 12, the patient was weaned from the ventilator. Renal failure improved from day to day and was normalized on day 18. Six weeks after discharge, the patient had no pulmonary or other complaints, and the chest radiograph and lung function tests were normal. Prednisolone was gradually diminished and stopped over a 3 month period.

## Discussion

Phenytoin, as a causal agent for the pulmonary and renal failure in this patient, is very likely, although not fully proven. The time course is very suggestive, and also the rapid recovery after withdrawal supports this hypothesis. Most other possible diagnoses seemed unlikely. There was no positive sign of sepsis or aspiration. Serology reasonably excluded other renopulmonary syndromes, vasculitis and autoimmune disease [5]. Positive evidence was found in the lung biopsy which showed similar histology as described in other patients with pulmonary toxicity [6, 7]. The histology was not suggestive of viral/bacterial infection or acute respiratory distress syndrome. In the last 20 yrs, several cases of phenytoin-induced acute pulmonary complications have been described [4, 8–10], of which five were examined histologically [6, 7]. Biopsies showed lymphocytic interstitial pneumonitis with or without eosinophilia after 3 weeks to several years of phenytoin. In two fatal cases, necrotizing vasculitis was described [11]. Slowly progressive pulmonary toxicity, presenting as radiographic parenchymal changes [12] or a reduced

pulmonary diffusing capacity [13], is more common than acute toxicity after long-term phenytoin therapy.

Renal failure has been described previously in combination with multiorgan involvement in patients on phenytoin [2, 9, 14, 16]. Histology has been described in a few patients and the results were not uniform. Interstitial nephritis with lymphocyte and plasmacyte infiltration and IgG and IgM deposits along the tubular and glomerular basement membrane have been observed [17, 18]. Antitubular basement membrane antibodies and phenytoin as an antigen were detected [14–18]. Recently, a phenytoin-induced antineutrophil cytoplasm antibody (ANCA)-associated vasculitis was described [19]. In our patient, resolution of the renal failure occurred before and was completed after cessation of phenytoin. The lack of pathological changes in the renal biopsy is surprising and may suggest a toxic or haemodynamic mechanism as a cause. Improvement of renal failure might in part be due to careful treatment of haemodynamics and fluid balance. Our patient had fever as the only hallmark of the anticonvulsant hypersensitivity syndrome. There was no skin rash or lymphadenopathy. This demonstrates again that the clinical expression of the anticonvulsant hypersensitivity syndrome can be very varied. The diversity might be a sign that the anticonvulsant hypersensitivity is not a disease entity. This is strengthened by the fact that several pathophysiological mechanisms may be involved in this hypersensitivity. Drug-specific T-cells [20], anticytochrome P450 antibodies [21], an inherited epoxide hydrolase deficiency [22–24], and polyclonal antibodies to phenytoin [25] have all been suggested to play a role in the hypersensitivity syndrome. The very rapid time course in our patient does not point to an immunological mechanism, unless the patient had been sensitized by unknown previous administration of phenytoin or by a related chemical compound.

This case illustrates that drug reactions can occur in every patient, sometimes very early in the treatment course, that they can mimic many other syndromes or diseases, and that a classic pattern of hypersensitivity syndrome probably does not exist. Especially in the intensive care unit with its high incidence of phenytoin use for convulsions, and the frequency of co-morbid states, one should be aware of the possible rapid onset and severe clinical pattern of phenytoin toxicity.

### References

- Merritt HH, Putnam TJ. Sodium diphenyl hydantoin in the treatment of convulsive disorders. *JAMA* 1938; 111: 1068–1073.
- Haruda F. Phenytoin hypersensitivity. *Neurology* 1979; 29: 1480–1485.
- Vittorio CC, Muglia JJ. Anticonvulsant hypersensitivity syndrome. *Arch Intern Med* 1995; 155: 2285–2290.
- Fruchter L, Laptook A. Diphenylhydantoin hypersensitivity reaction associated with interstitial pulmonary infiltrates and hypereosinophilia. *Ann Allergy* 1981; 47: 453–455.
- Niles JL, Bottiger EP, Saurina GR, et al. The syndrome of lung hemorrhage and nephritis is usually an ANCA-associated condition. *Arch Intern Med* 1996; 156: 440–445.
- Michael JR, Rudin ML. Acute pulmonary disease caused by phenytoin. *Ann Intern Med* 1981; 95: 452–454.
- Chamberlain DW, Hyland RH, Ross DJ. Diphenylhydantoin-induced lymphocytic interstitial pneumonia. *Chest* 1986; 90: 458–460.
- Bayer AS, Targan SR, Pitchon HE, Guze LB. Dilantin toxicity: miliary pulmonary infiltrates and hypoxemia. *Ann Intern Med* 1976; 85: 475–476.
- Mahatma M, Haponik EF, Nelson S, Lopez A, Summer W. Phenytoin-induced acute respiratory failure with pulmonary eosinophilia. *Am J Med* 1989; 87: 93–94.
- Muren C, Strandberg O. Cavitory pulmonary nodules in atypical collagen disease and lupoid drug reaction. *Acta Radiologica* 1989; 30: 281–284.
- Yermakov VM, Hitti IF, Sutton AL. Necrotizing vasculitis associated with diphenylhydantoin: two fatal cases. *Human Pathology* 1983; 14: 182–184.
- Moore MT. Pulmonary changes in hydantoin therapy. *JAMA* 1959; 171: 1328–1333.
- Hazlett DR, Ward GW, Madison DS. Pulmonary function loss in diphenylhydantoin therapy. *Chest* 1974; 66: 660–664.
- Josephs SH, Rothman SJ, Buckley RH. Phenytoin hypersensitivity. *J Allergy Clin Immunol* 1980; 66: 166–172.
- Michael JR, Mitch WE. Reversible renal failure and myositis caused by phenytoin hypersensitivity. *JAMA* 1976; 236: 2773–2775.
- Aggarwal BN, Cabebe FG, Hoffman B. Diphenylhydantoin-induced acute renal failure. *Nephron* 1977; 18: 249–251.
- Sheth KJ, Casper JT, Good TA. Interstitial nephritis due to phenytoin hypersensitivity. *J Pediatr* 1996; 91: 438–441.
- Hyman LR, Ballow M, Knieser MR. Diphenylhydantoin interstitial nephritis. Roles of cellular and humoral immunologic injury. *J Pediatr* 1978; 92: 915–920.
- Parry RG, Gordon P, Mason JC, Marley NJE. Phenytoin-associated vasculitis and ANCA positivity: a case report. *Nephrol Dial Transpl* 1996; 11: 357–359.
- Mauri-Hellweg D, Bettens F, Mauri D, Brander C, Hunziker T, Pichler WJ. Activation of drug-specific CD4+ and CD8+ T cells in individuals allergic to sulfonamides, phenytoin, and carbamazepine. *J Immunol* 1995; 155: 462–472.
- Leeder JS, Riley RJ, Cook VA, Spielberg SP. Human anti-cytochrome P450 antibodies in aromatic anticonvulsant-induced hypersensitivity reactions. *J Pharmacol Exp Ther* 1992; 263: 360–367.
- Gennis MA, Vemuri R, Burns EA, Hill JV, Miller MA, Spielberg SP. Familial occurrence of hypersensitivity to phenytoin. *Am J Med* 1991; 91: 631–634.
- Spielberg SP, Gordon GB, Blake DA, Goldstein DA, Herlong HF. Predisposition to phenytoin hepatotoxicity assessed *in vitro*. *N Engl J Med* 1981; 305: 722–727.
- Shear NH, Spielberg SP. Anticonvulsant hypersensitivity syndrome. *J Clin Invest* 1988; 82: 1826–1832.
- Kleckner HB, Yakulis V, Heller P. Severe hypersensitivity to diphenylhydantoin with circulating antibodies to the drug. *Ann Intern Med* 1975; 83: 522–523.